



US 20070038085A1

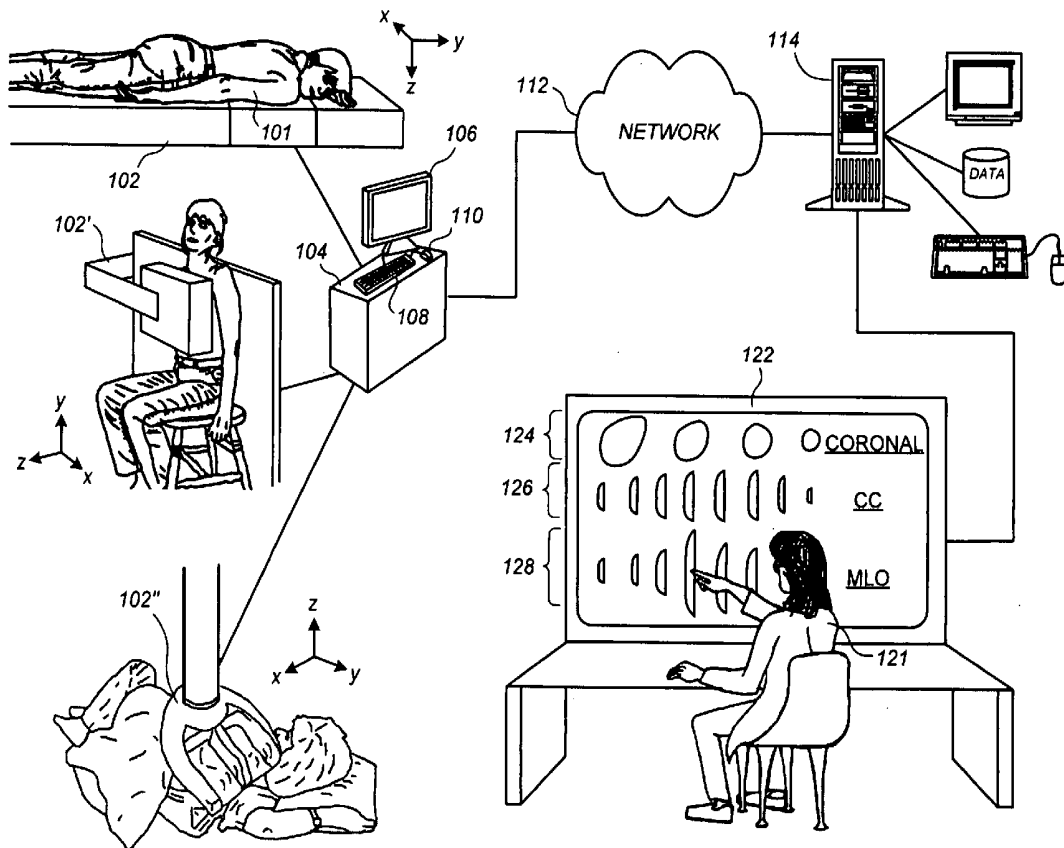
(19) **United States**(12) **Patent Application Publication**  
**Zhang et al.**(10) **Pub. No.: US 2007/0038085 A1**(43) **Pub. Date: Feb. 15, 2007**(54) **NAVIGATION AMONG MULTIPLE BREAST  
ULTRASOUND VOLUMES****Publication Classification**(76) Inventors: **Wei Zhang**, Union City, CA (US);  
**Jiayu Chen**, Palo Alto, CA (US);  
**Thomas P. Neff**, Newark, CA (US);  
**Michael E. Reed**, Sunnyvale, CA (US);  
**Jeanine M. Rader**, Rockford, IL (US)(51) **Int. Cl.**  
**A61B 8/00** (2006.01)  
(52) **U.S. Cl.** ..... **600/437**(57) **ABSTRACT**

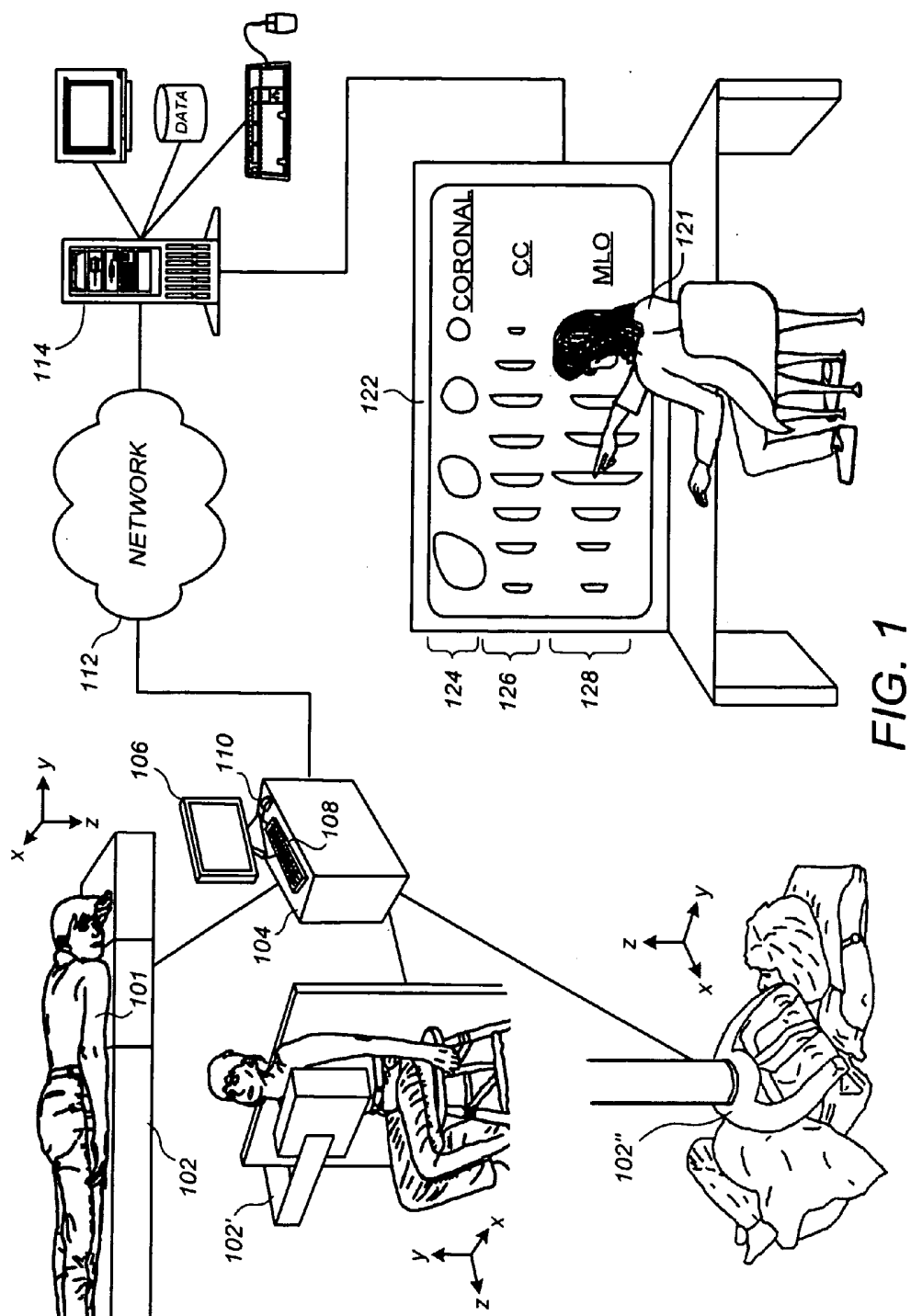
Correspondence Address:

**COOPER & DUNHAM, LLP**  
**1185 AVENUE OF THE AMERICAS**  
**NEW YORK, NY 10036**(21) Appl. No.: **11/439,093**(22) Filed: **May 23, 2006****Related U.S. Application Data**

(60) Provisional application No. 60/684,622, filed on May 24, 2005.

Navigation among breast ultrasound volumes derived from different volumetric ultrasonic scans of a same breast is described. On a display of a breast ultrasound workstation, a first image derived from a first ultrasonic volume is displayed. A user selection of a source region of interest (ROI) in the first image is received. A destination ROI within a second ultrasonic volume is identified that at least roughly corresponds to a same locality of tissue in the breast as the source ROI. A second image derived from the second ultrasonic volume and including the destination ROI is displayed, the destination ROI being highlighted.





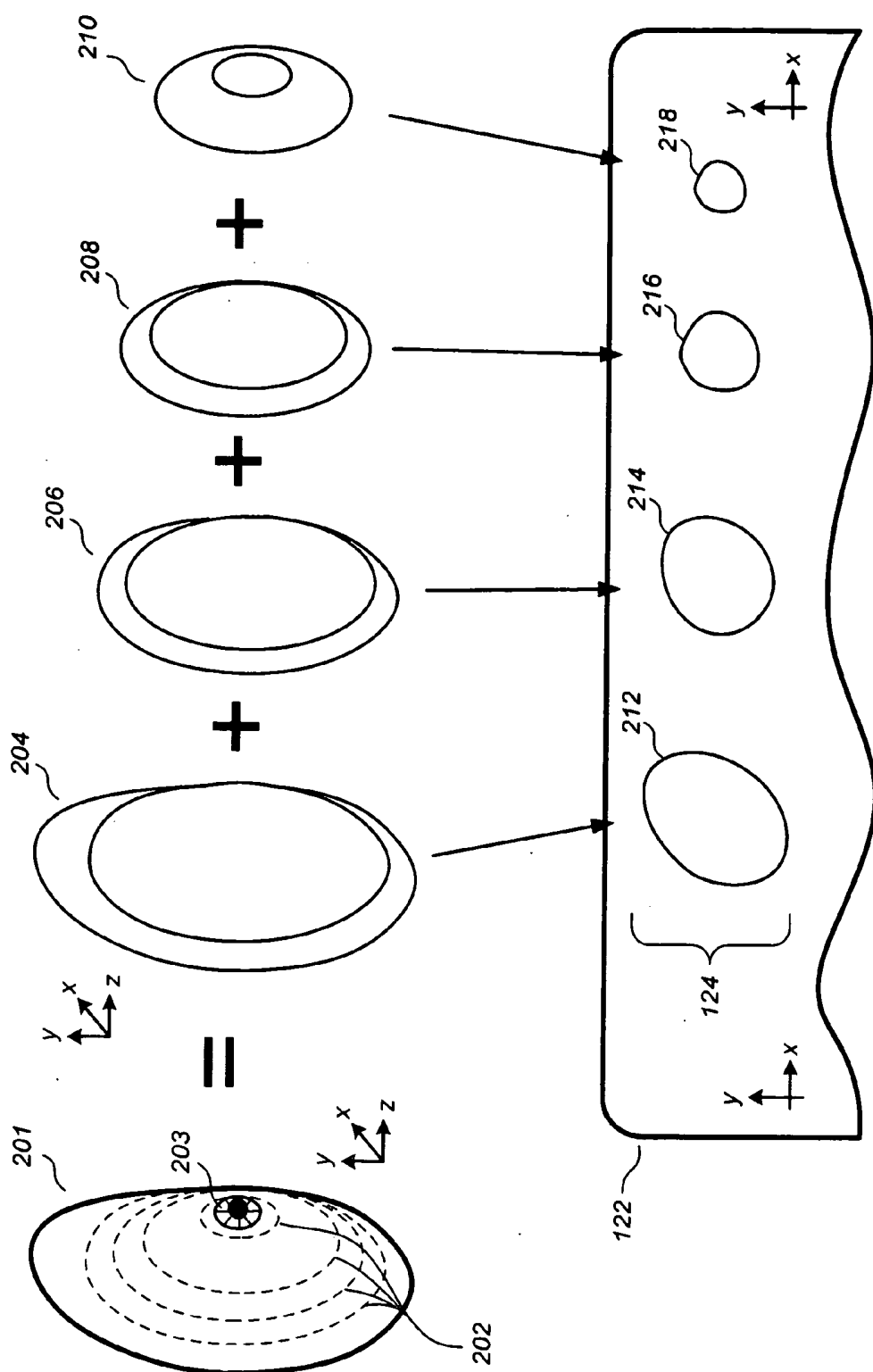


FIG. 2

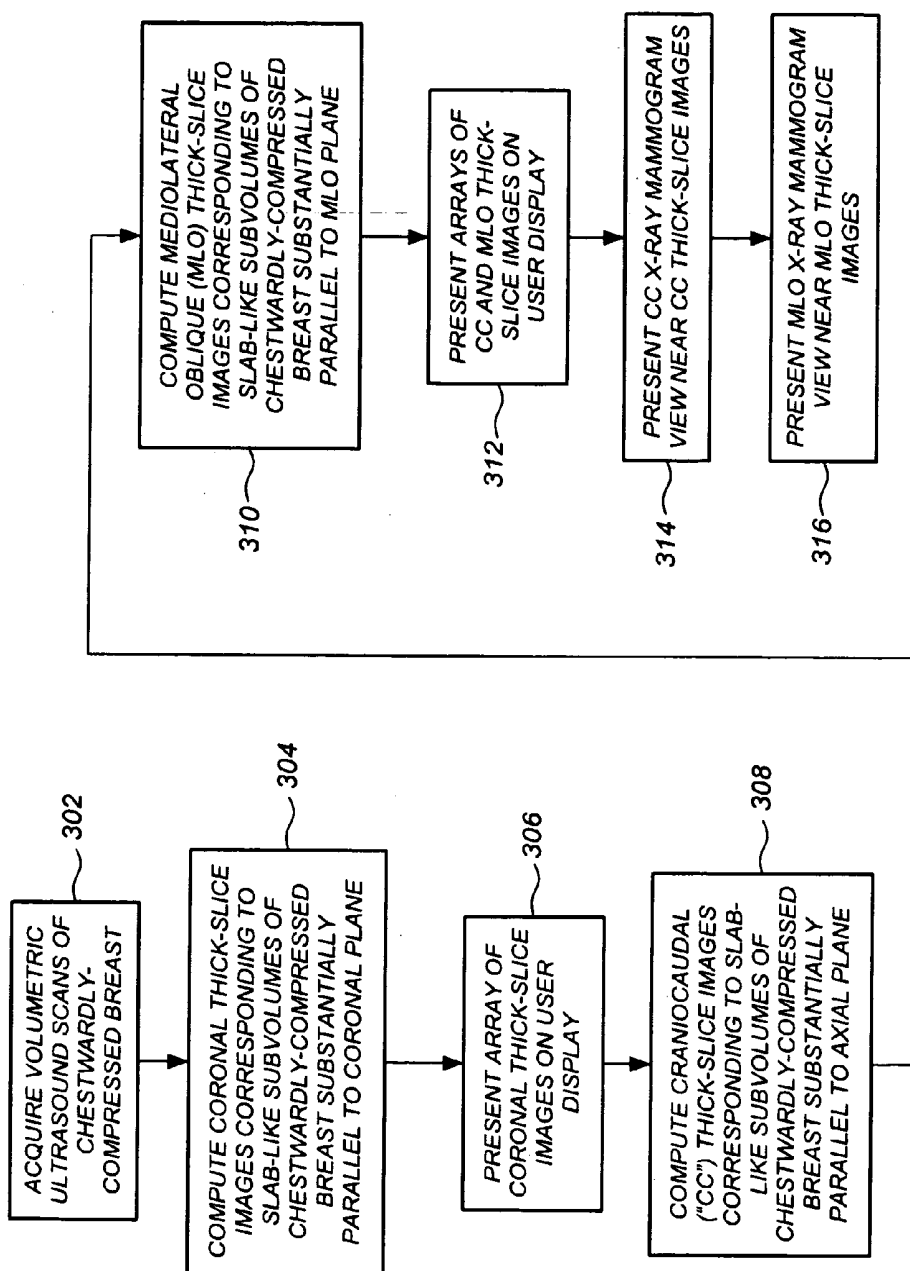
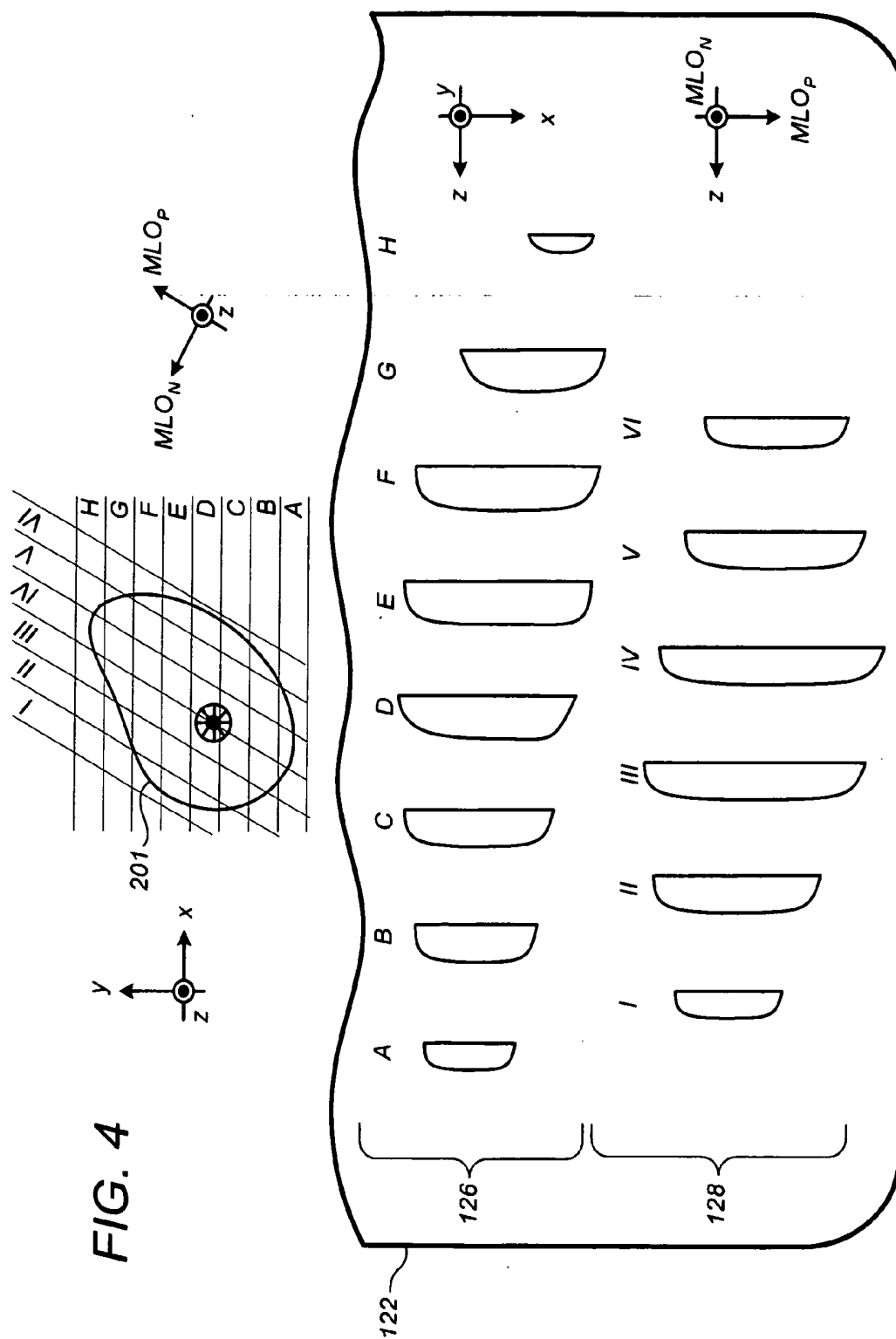


FIG. 3



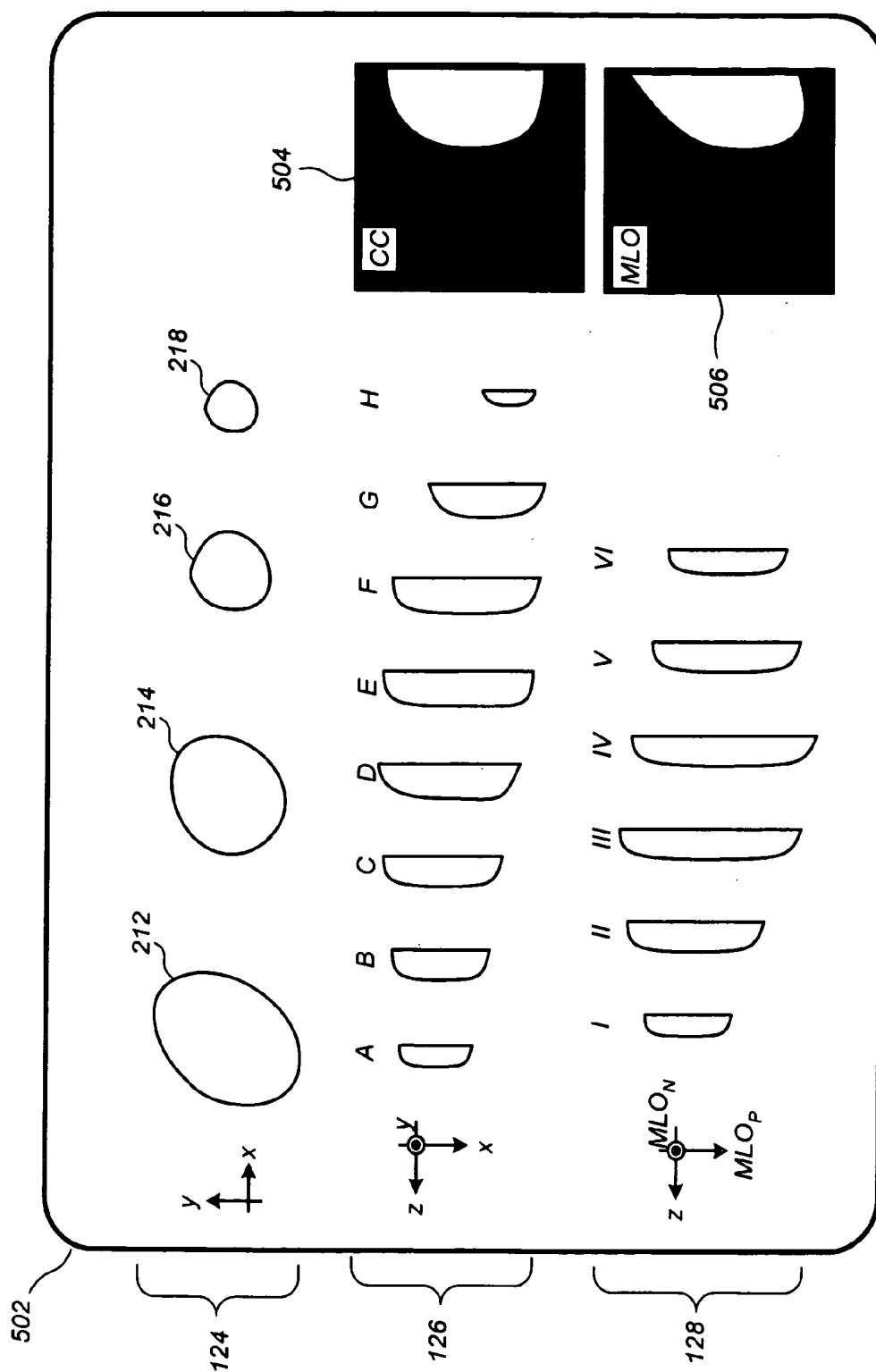


FIG. 5

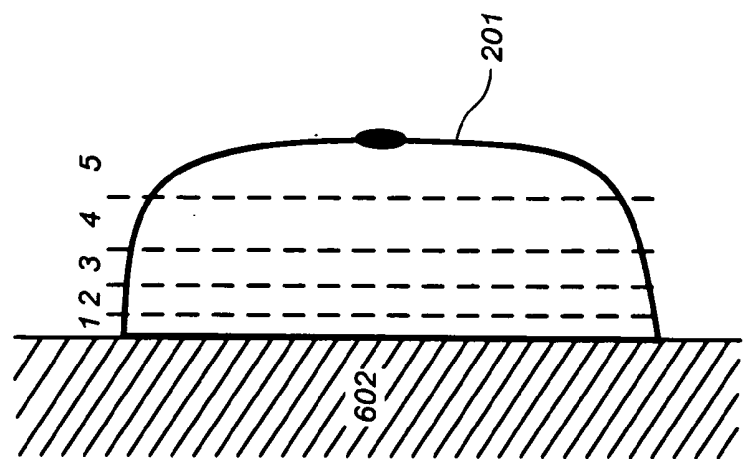


FIG. 6B

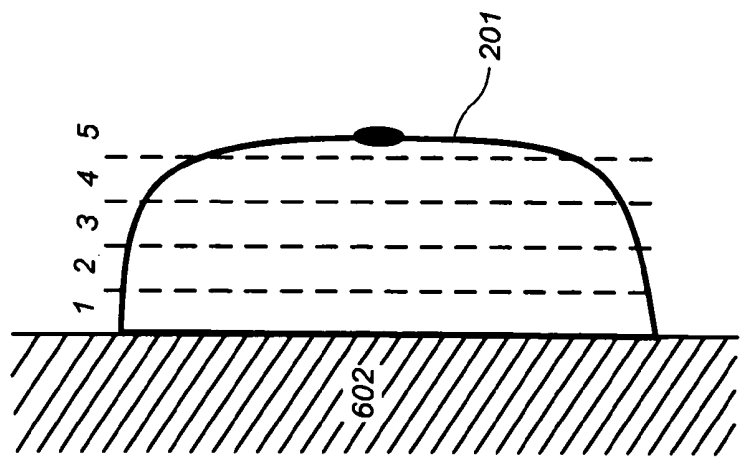


FIG. 6A

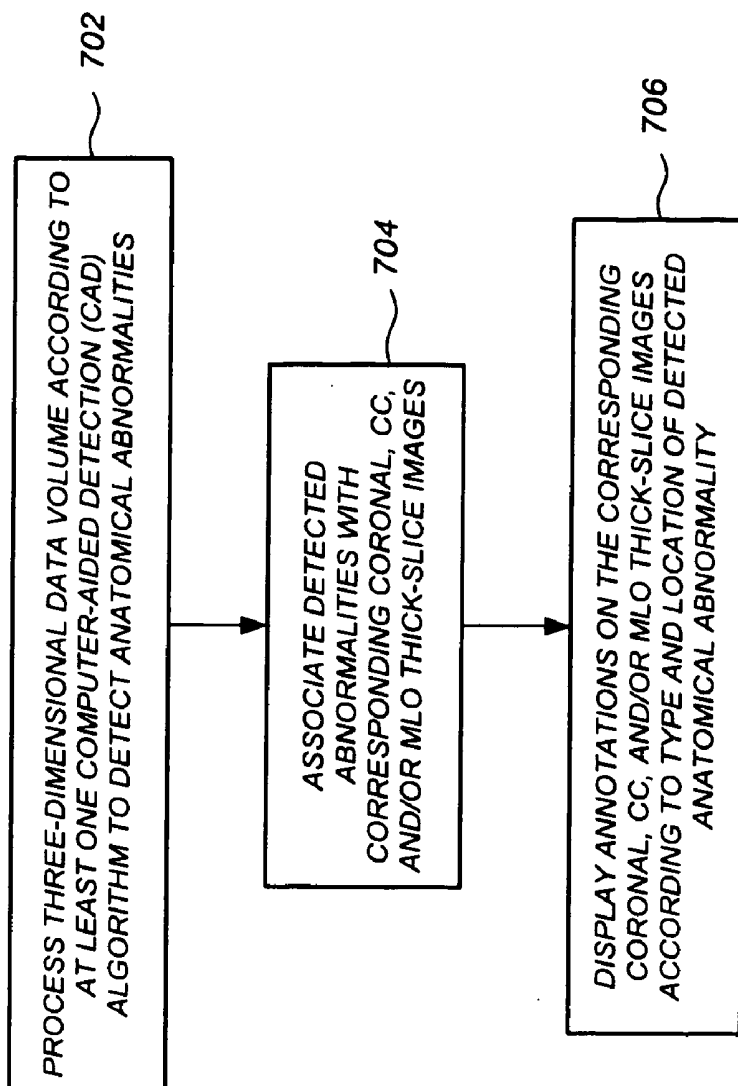
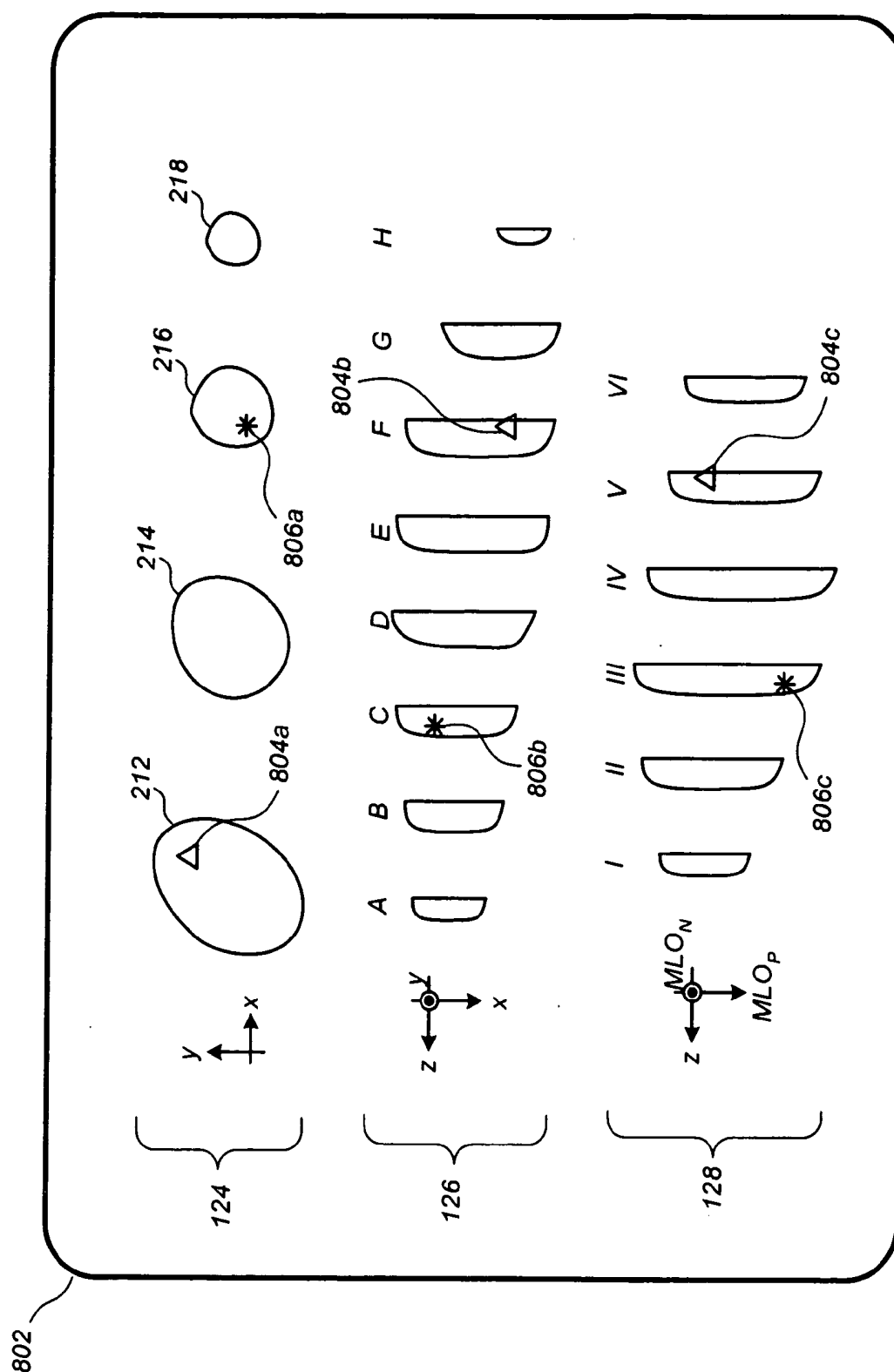


FIG. 7





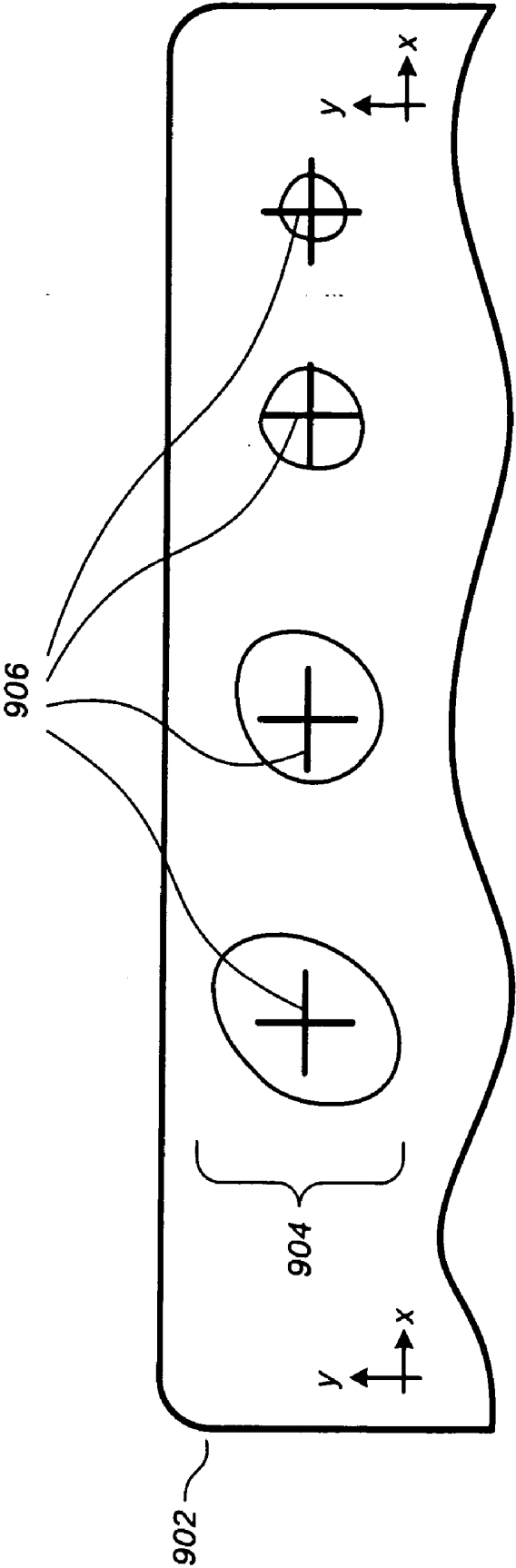


FIG. 9

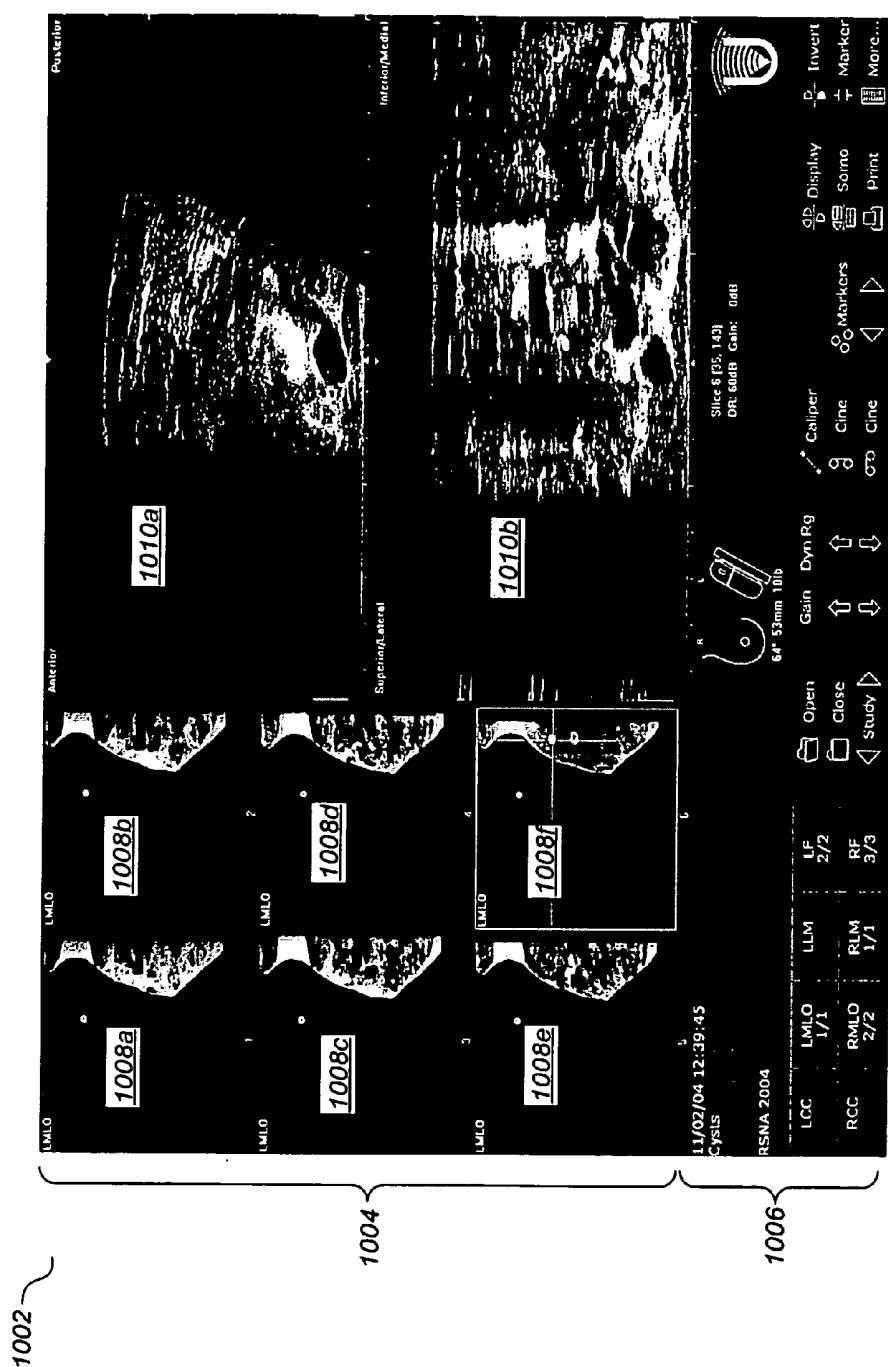


FIG. 10

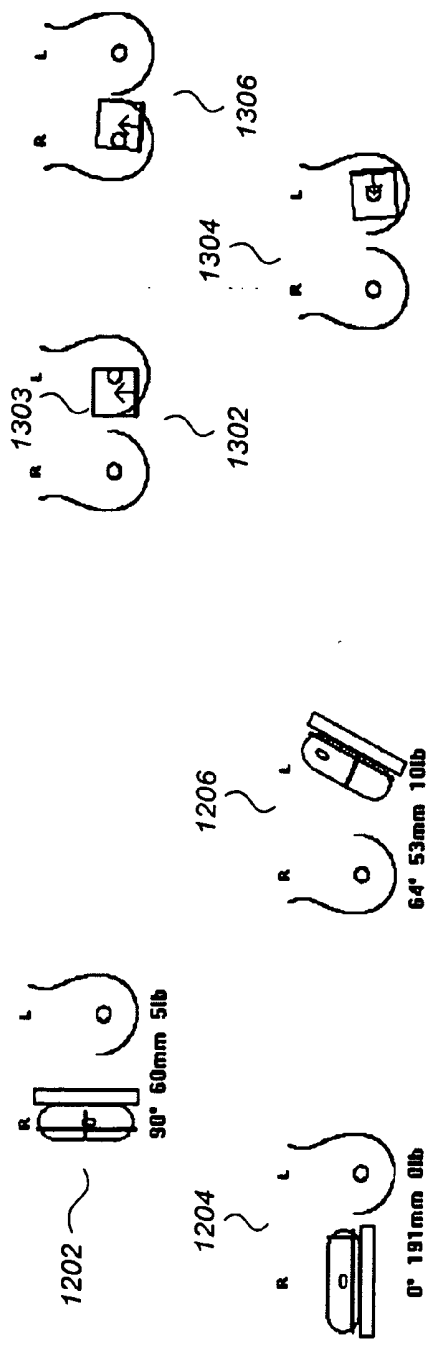
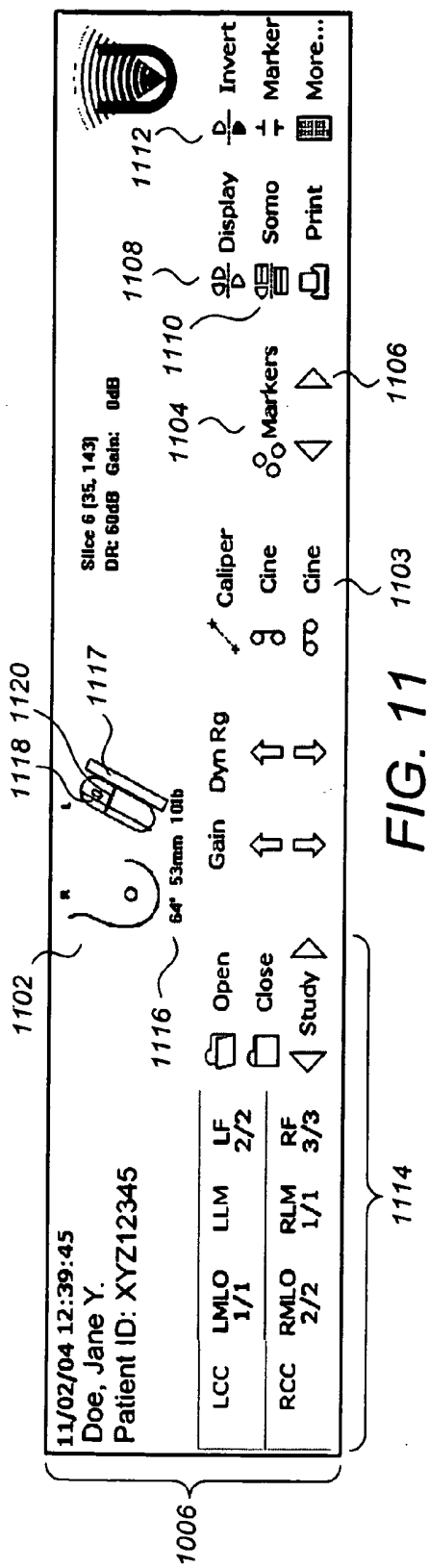


FIG. 13

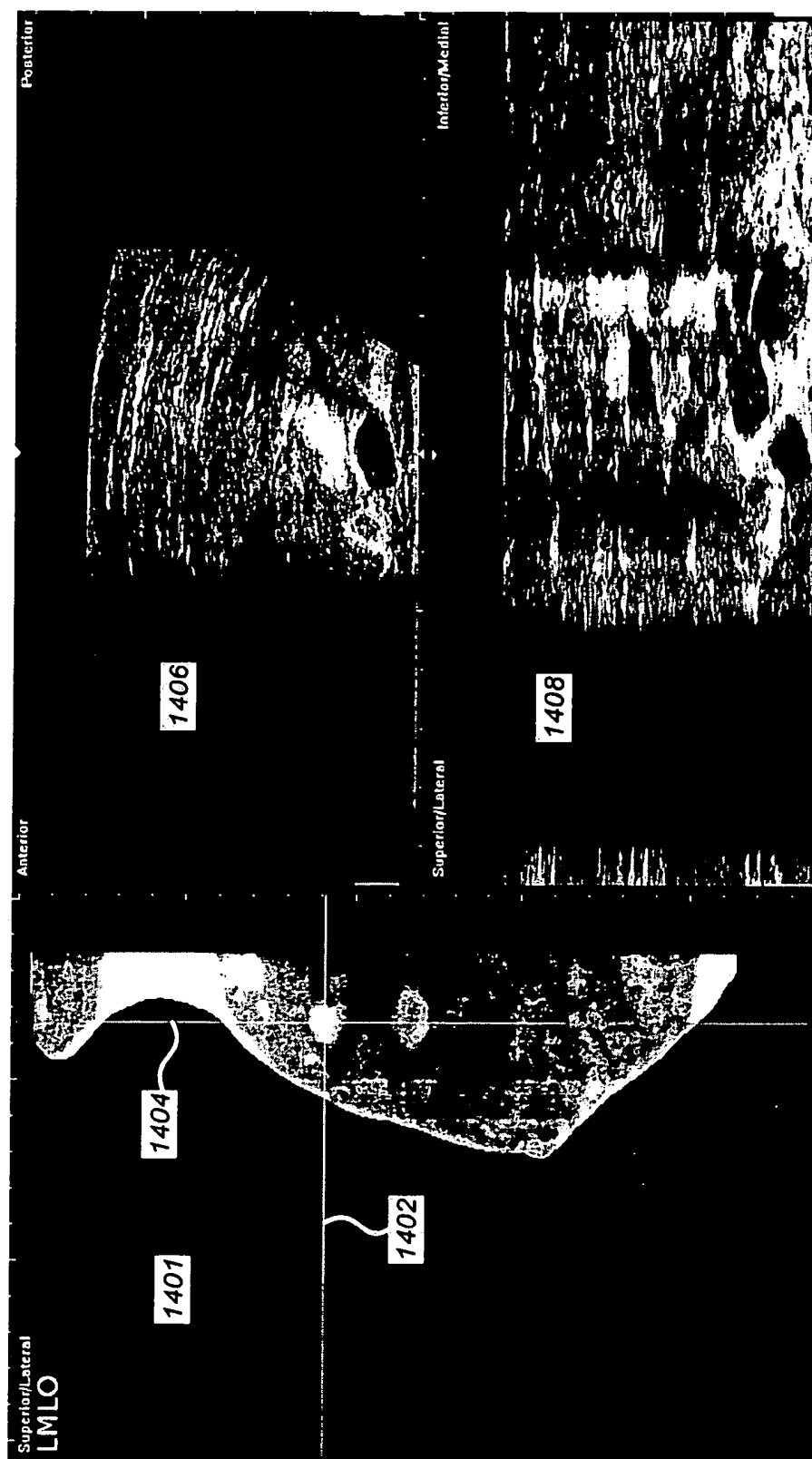
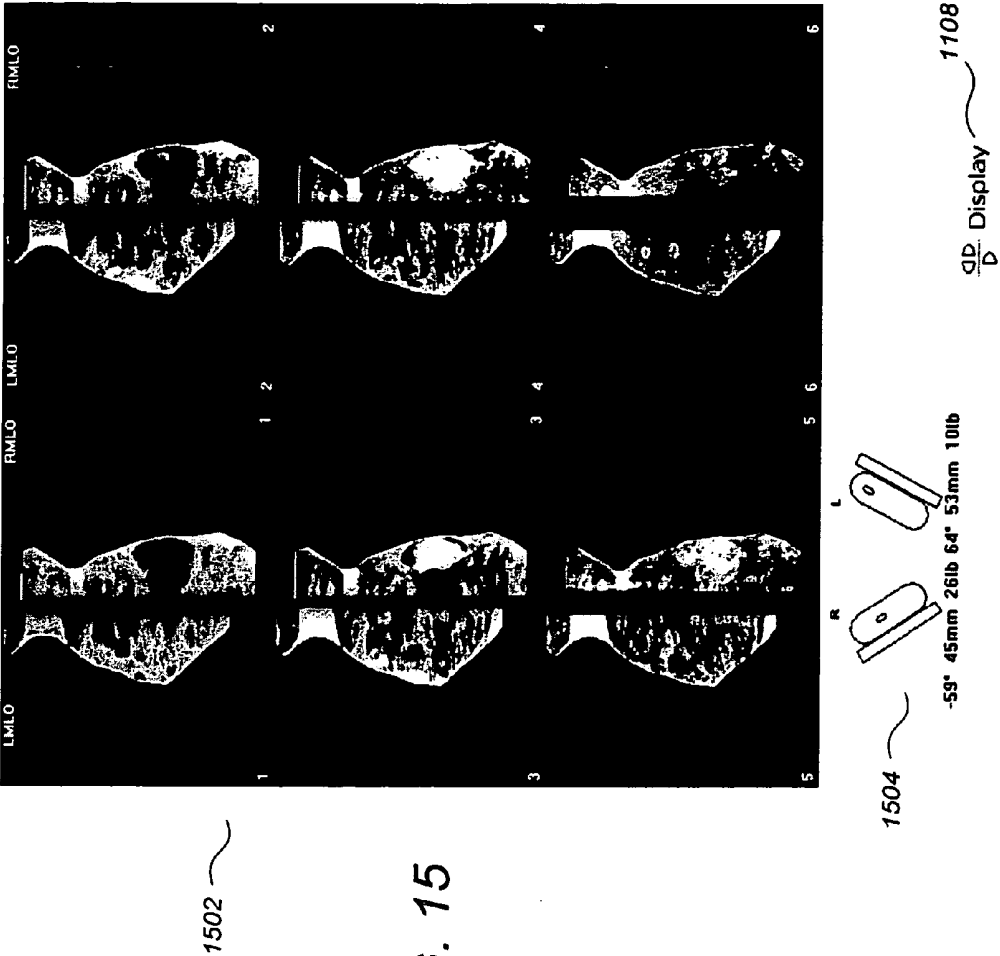


FIG. 14



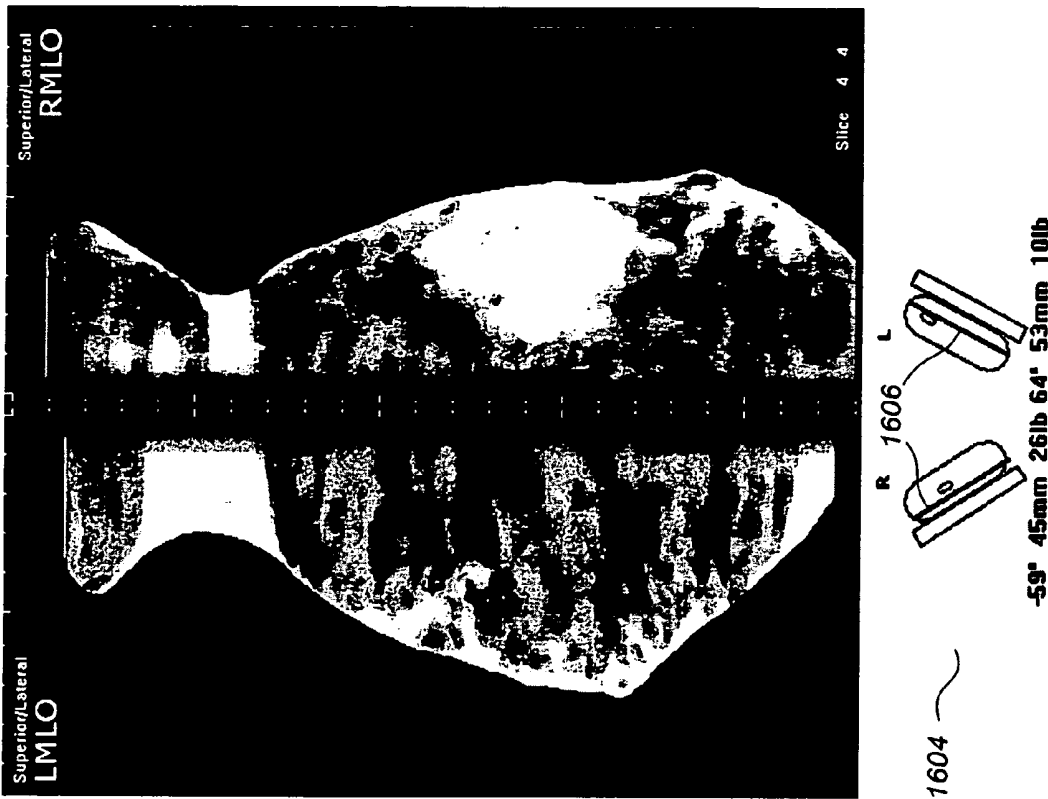
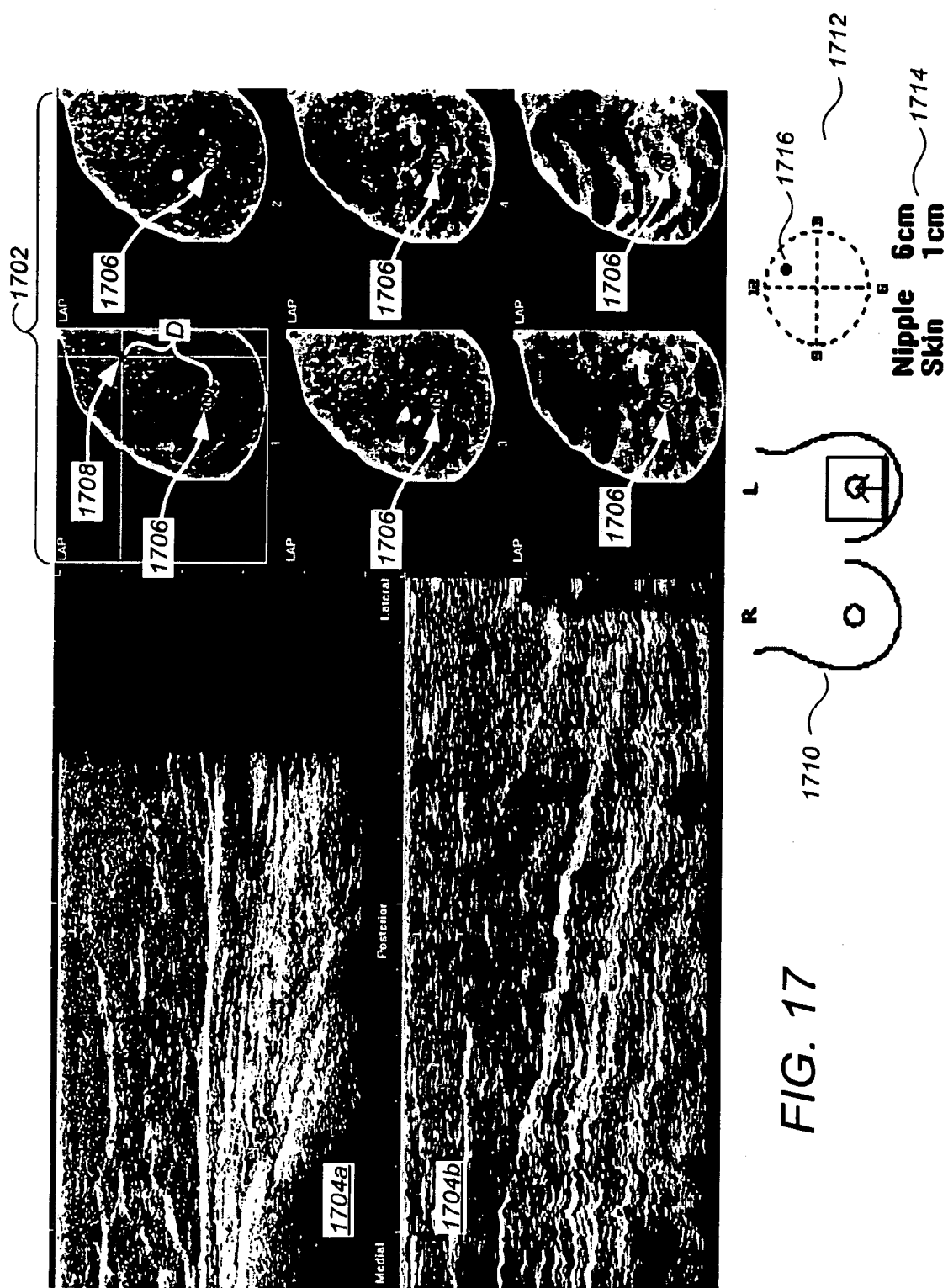
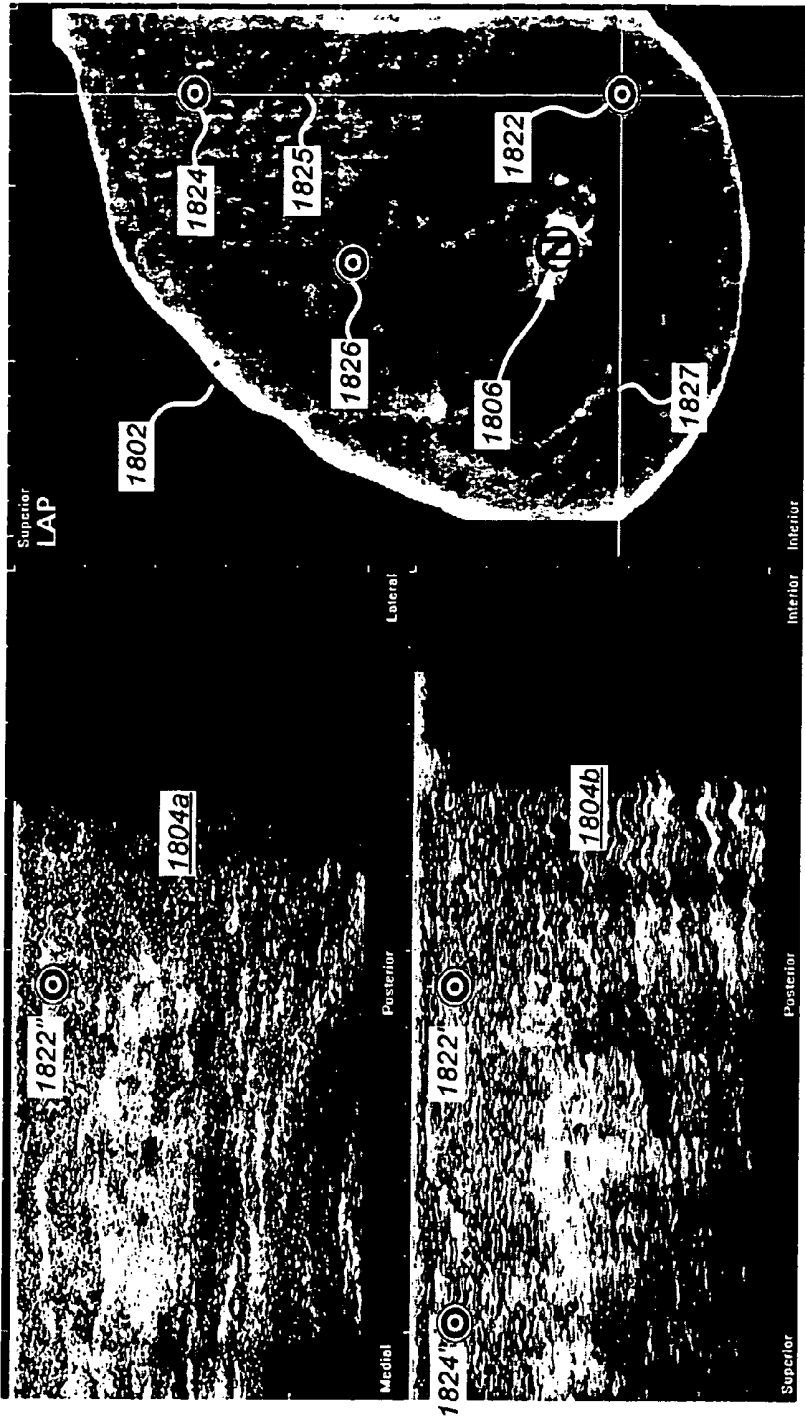


FIG. 16







Markers ~ 1104

~ 1106

FIG. 18

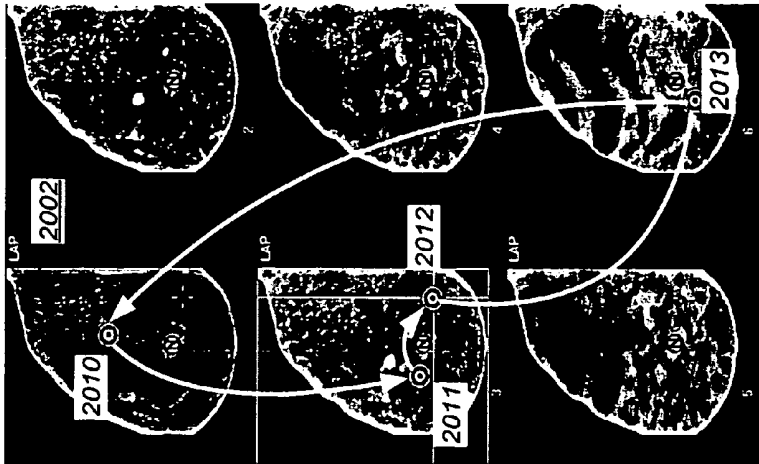


FIG. 20

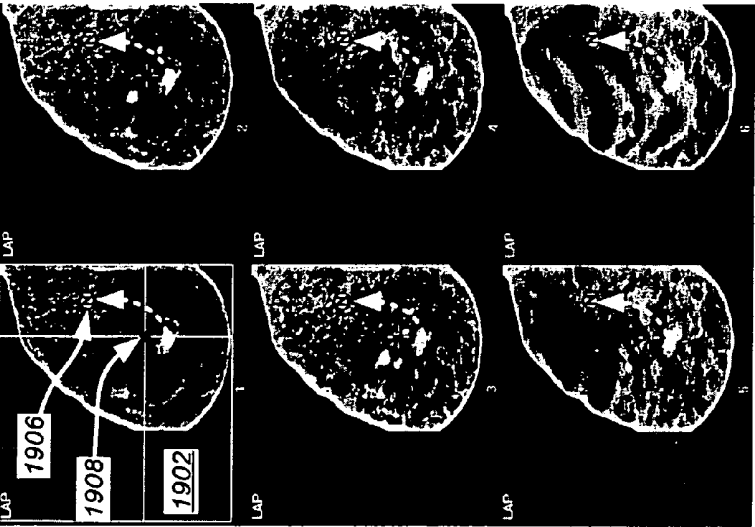

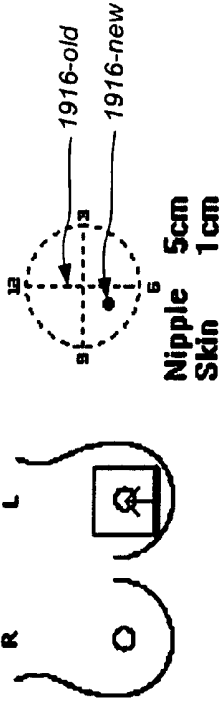
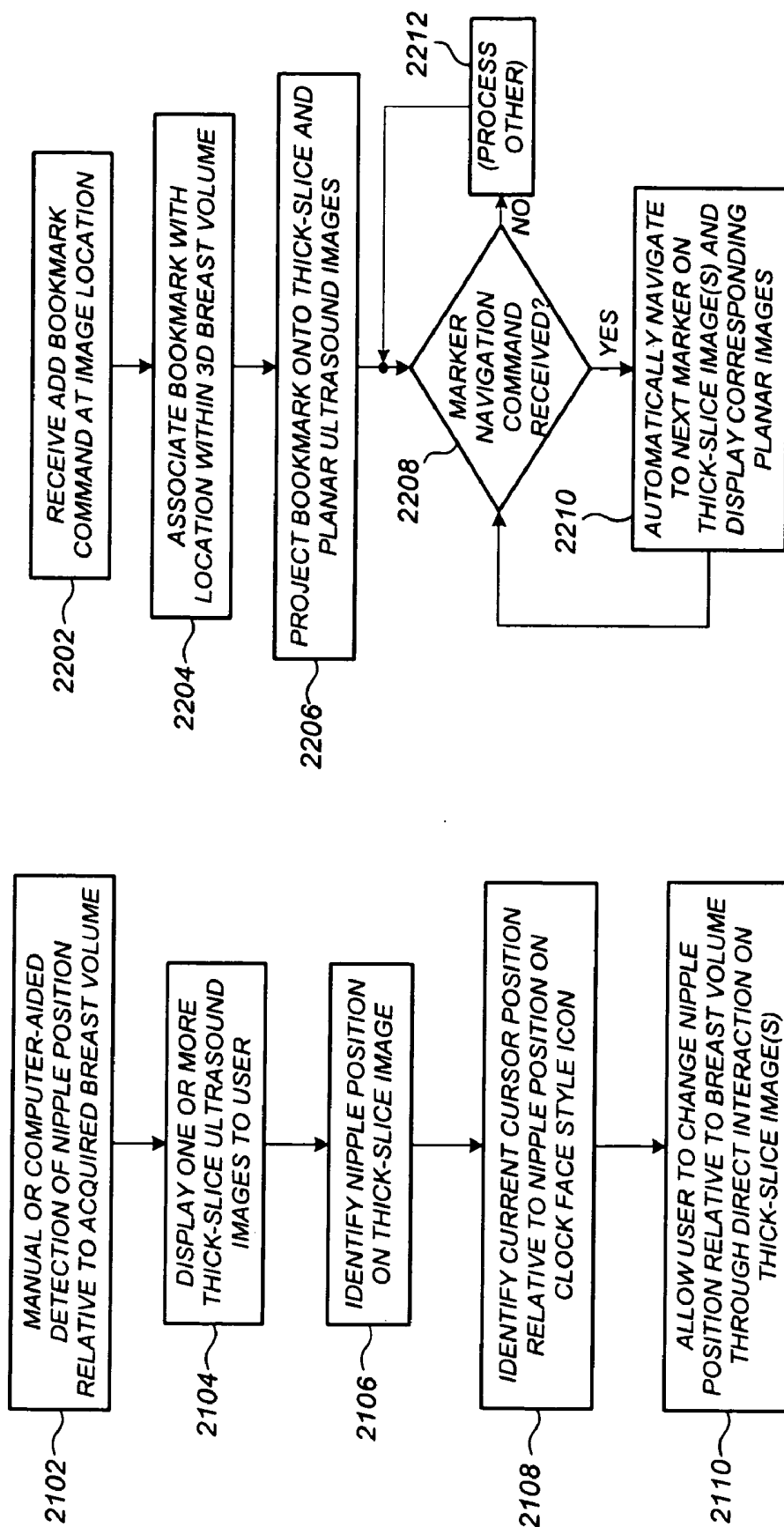


FIG. 19





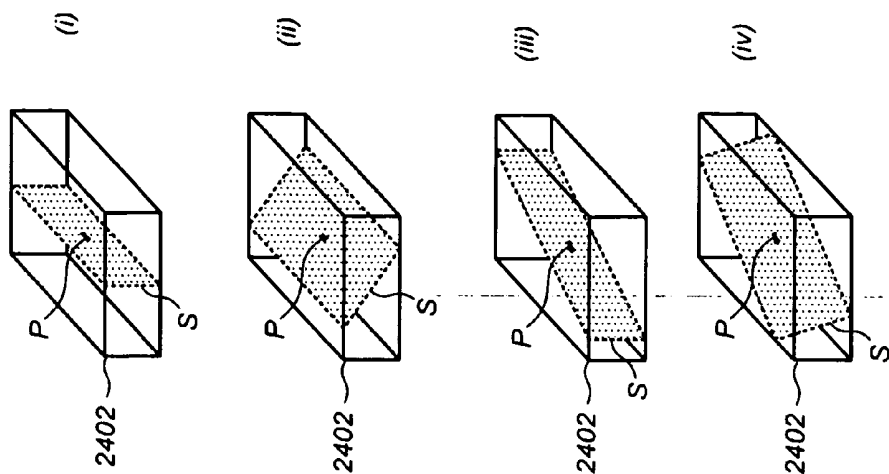


FIG 24

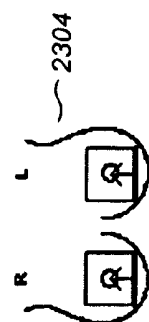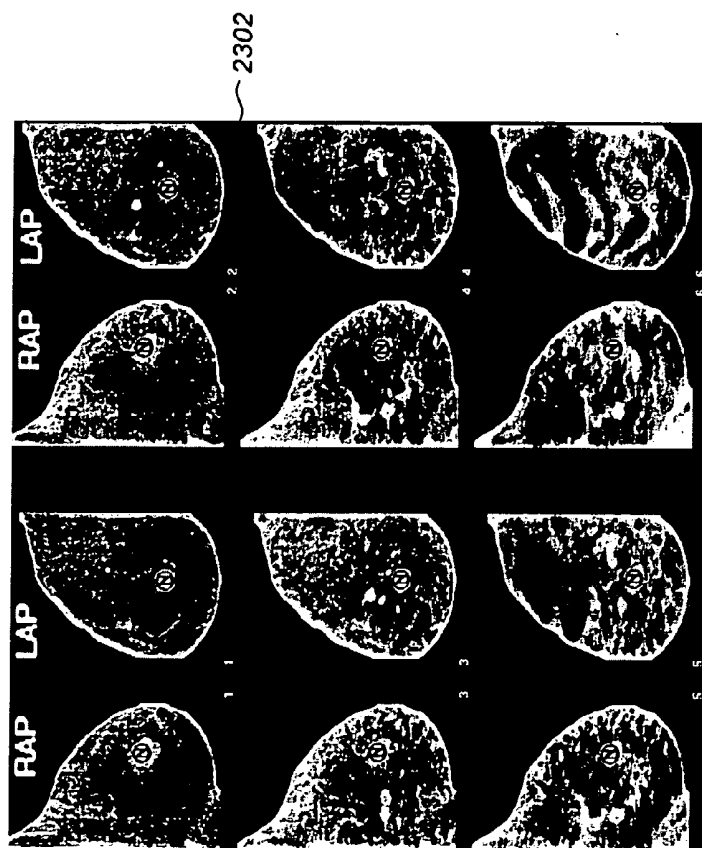


FIG 23

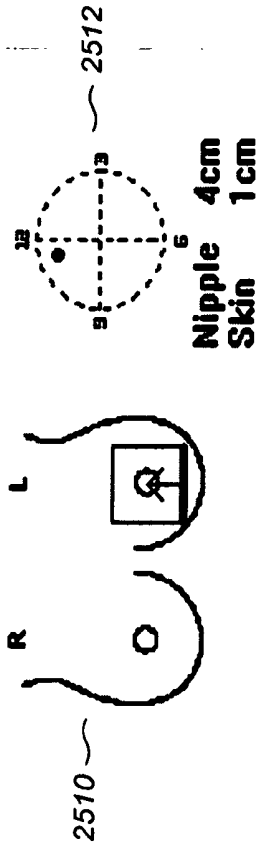
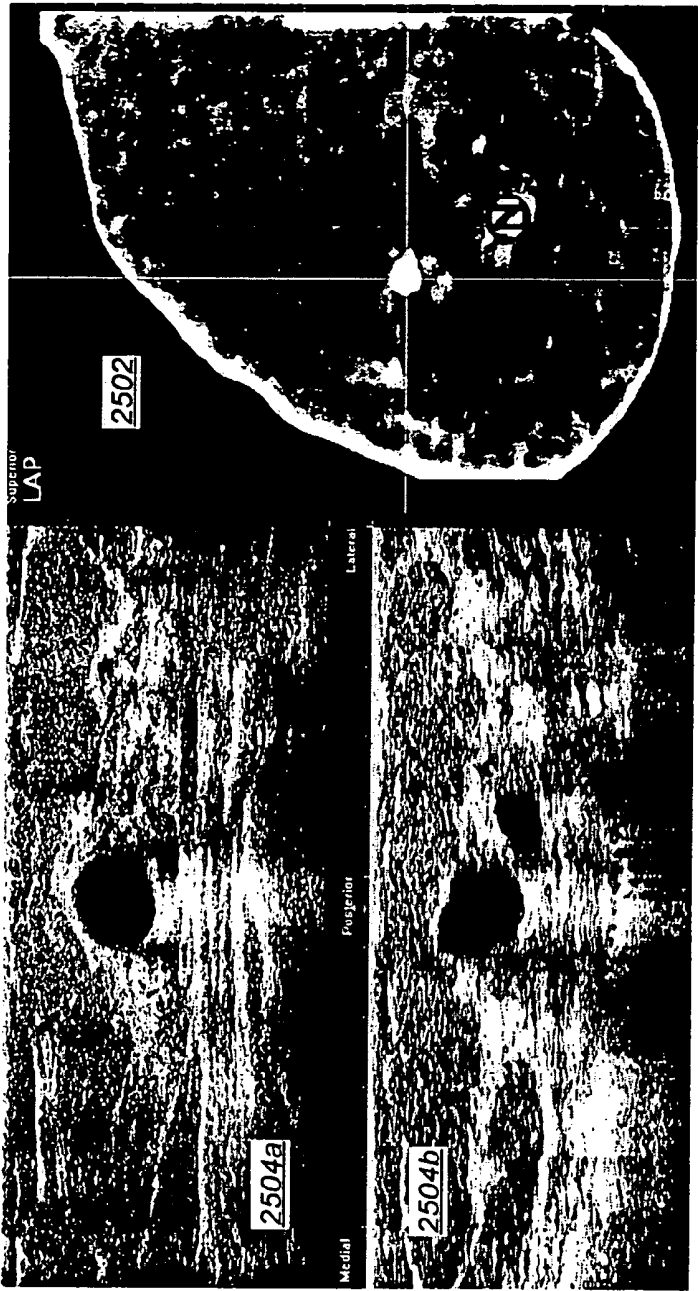


FIG. 25

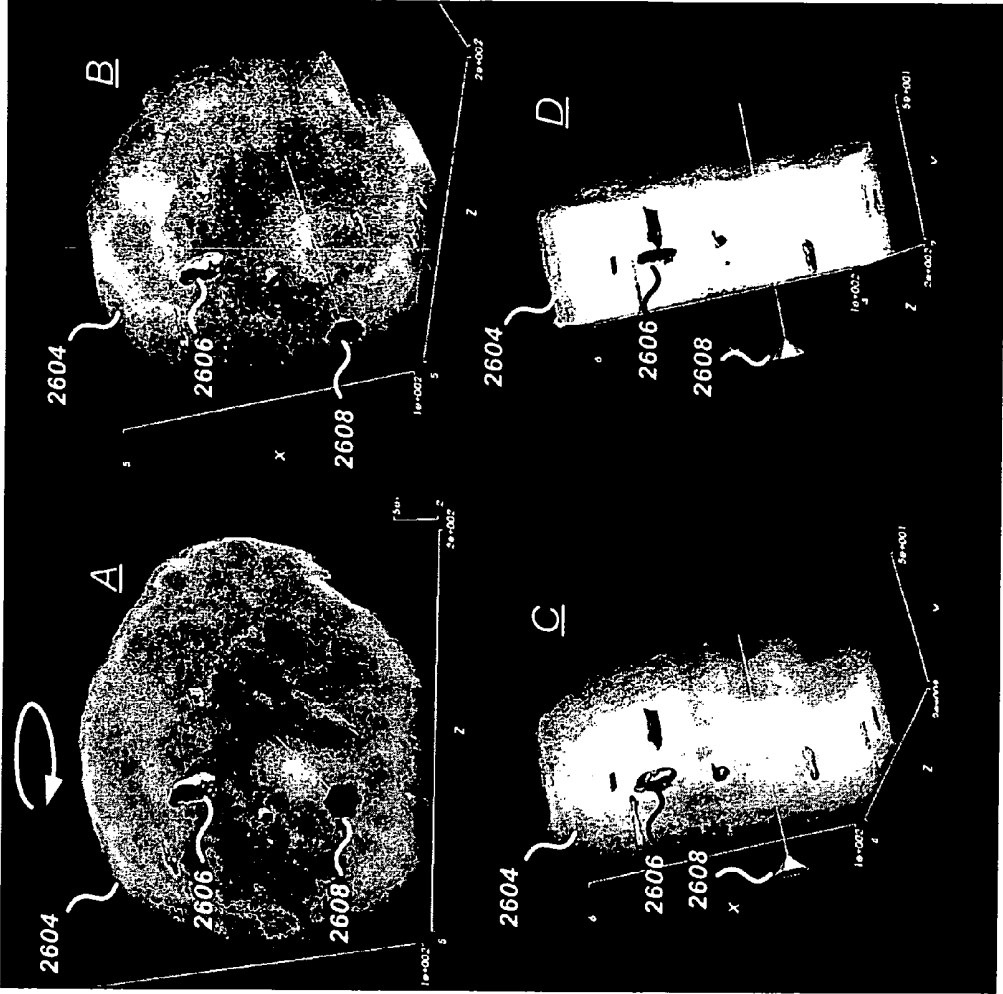


FIG. 26

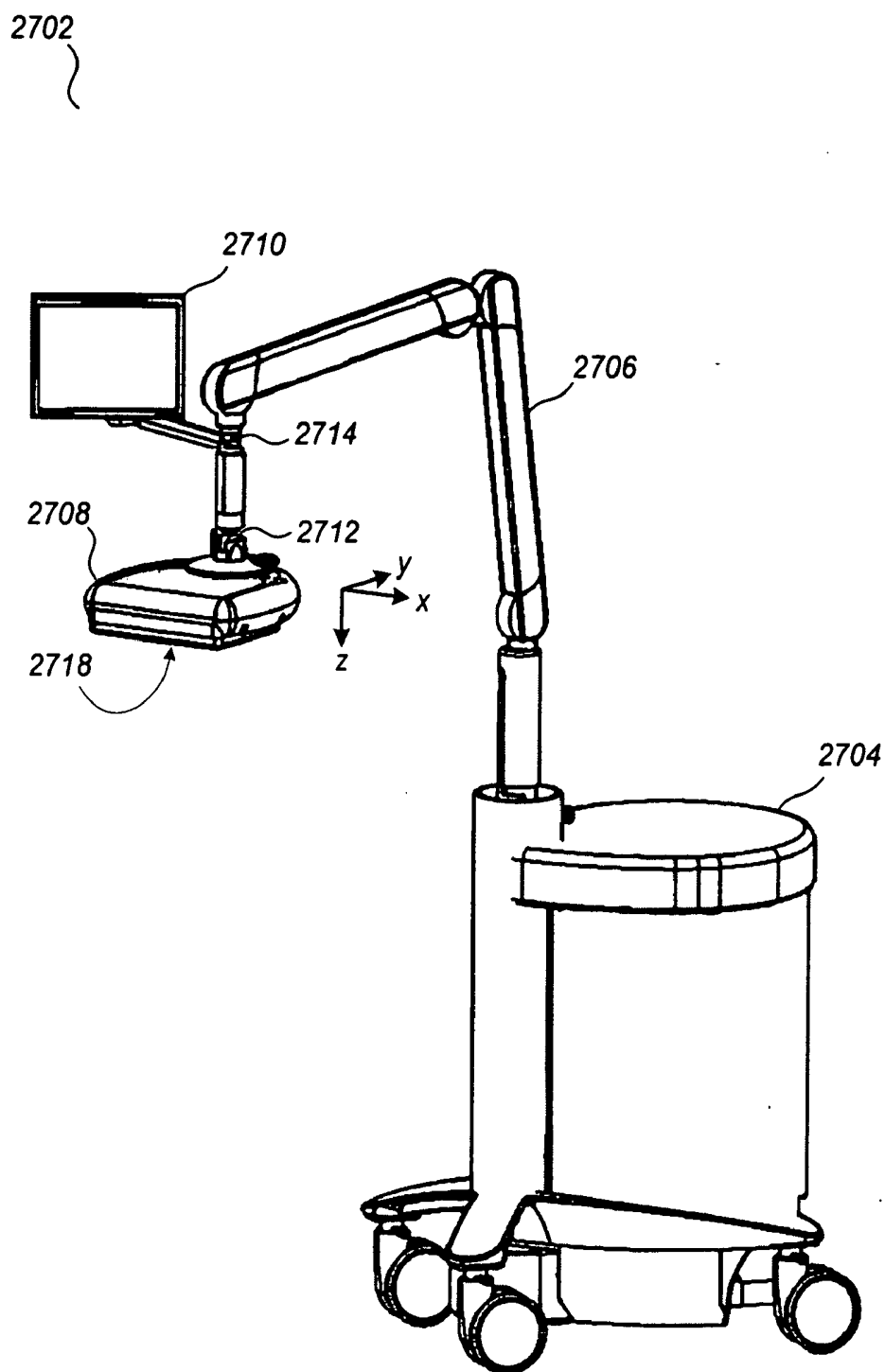
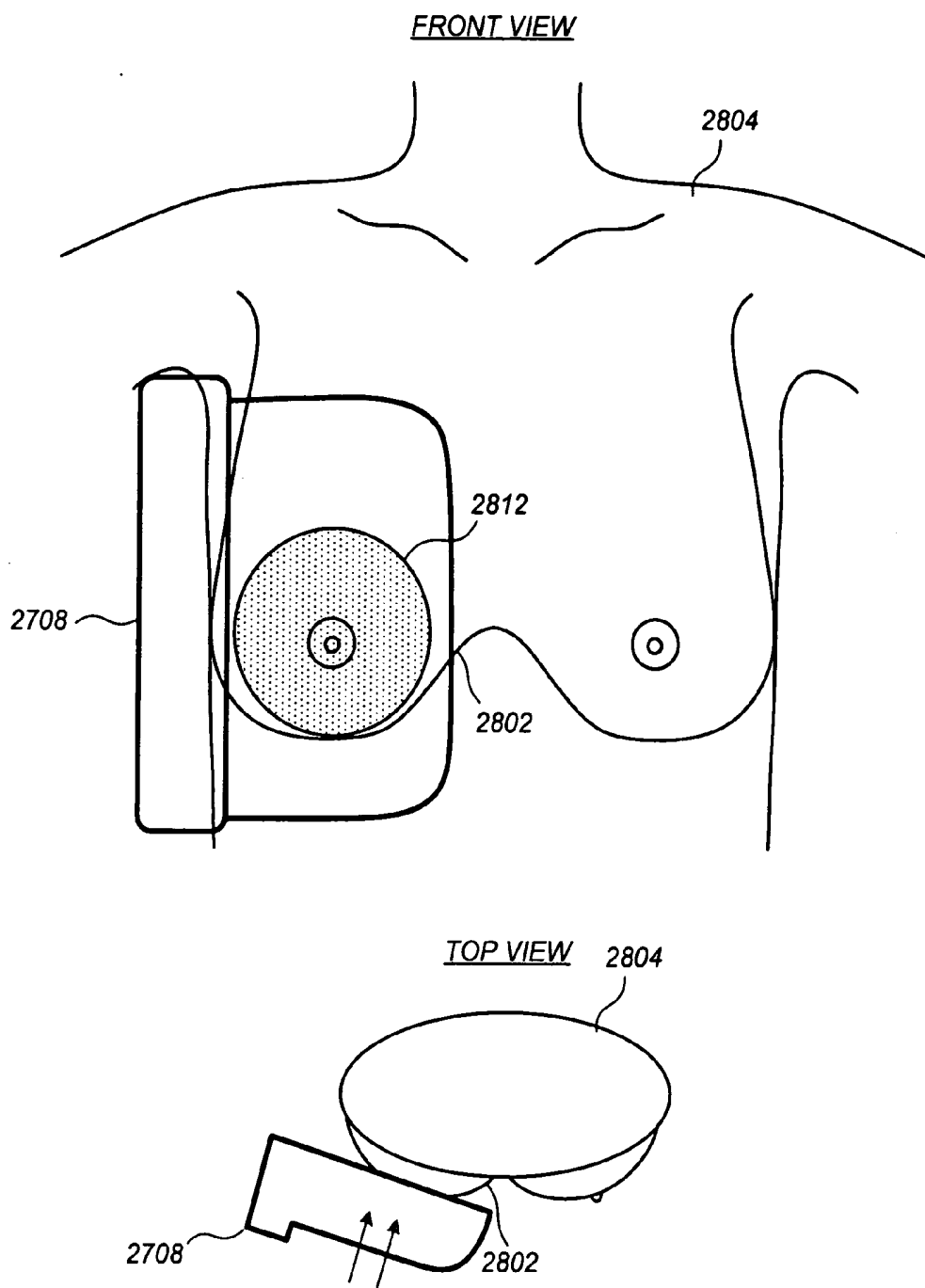
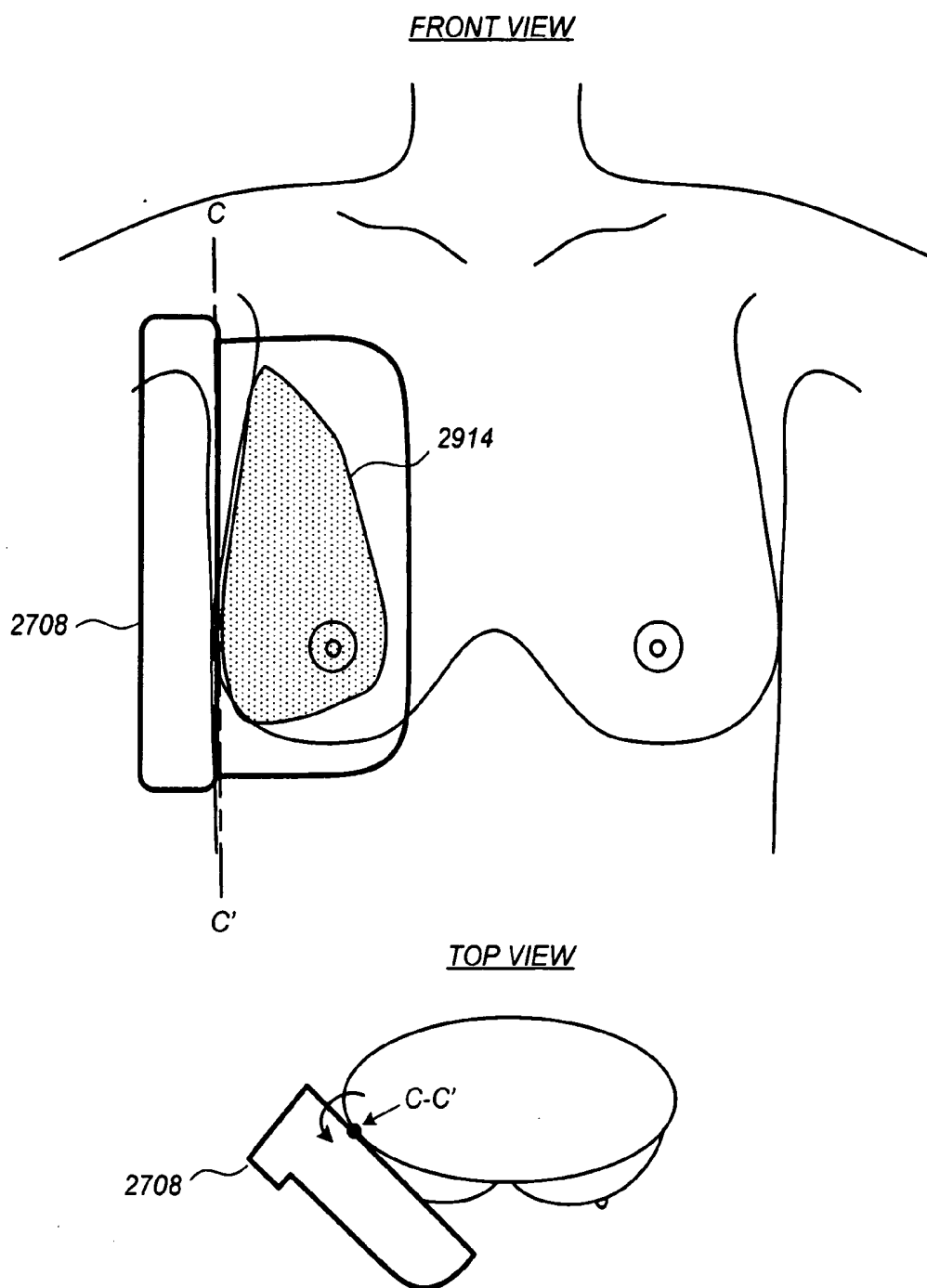


FIG. 27

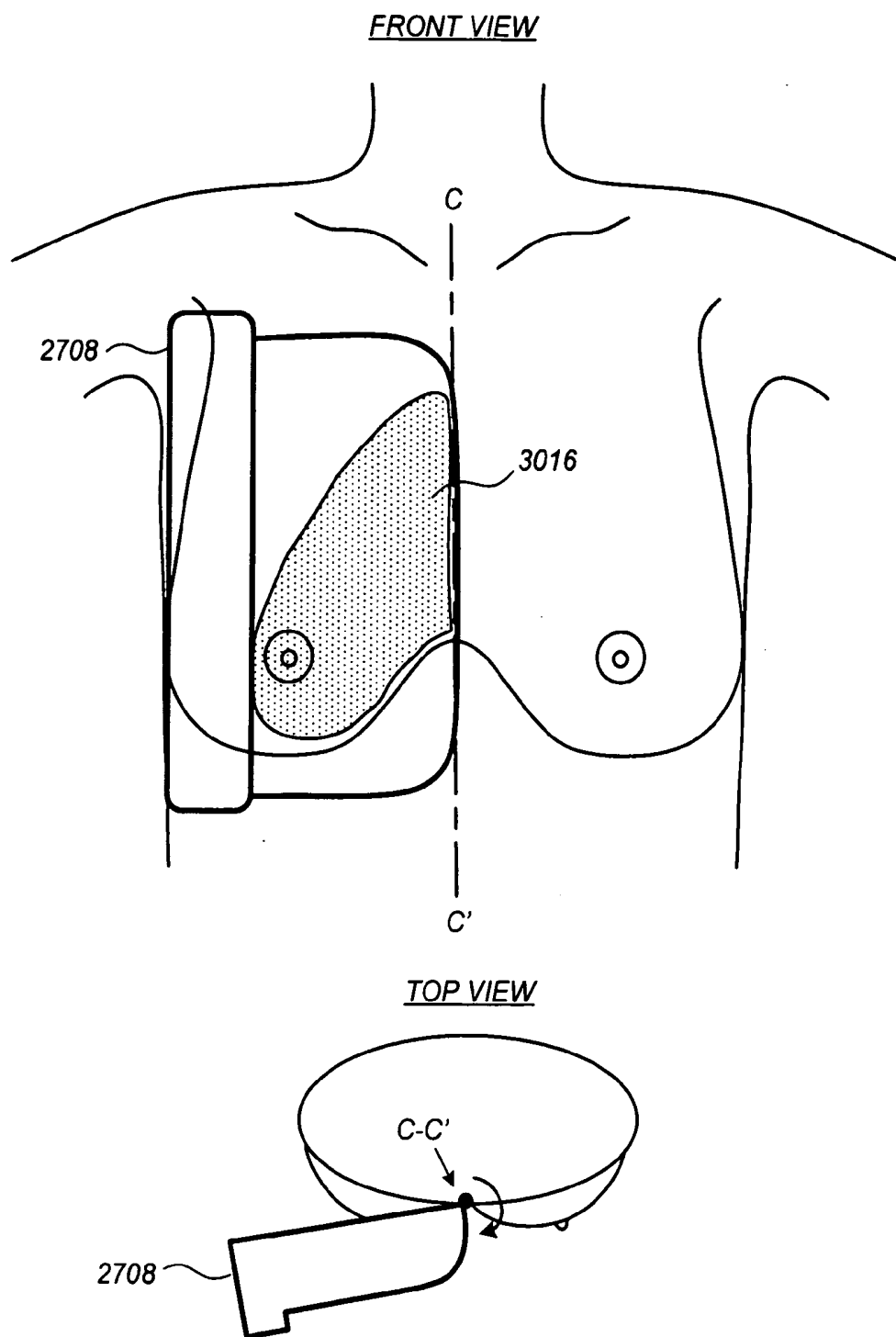


**FIG. 28**

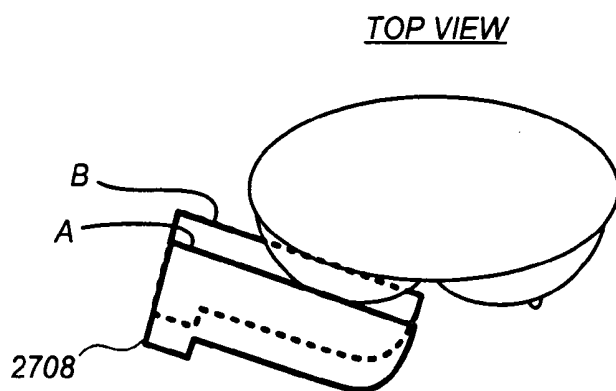
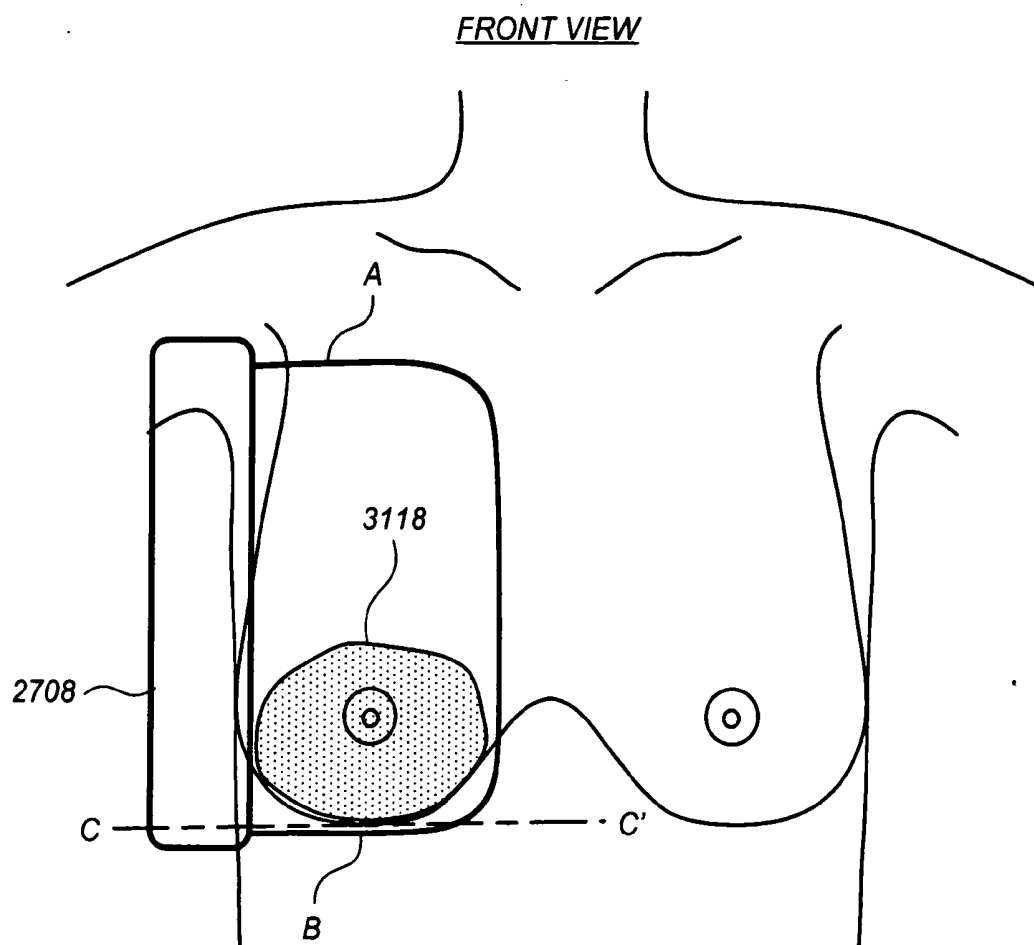




**FIG. 29**

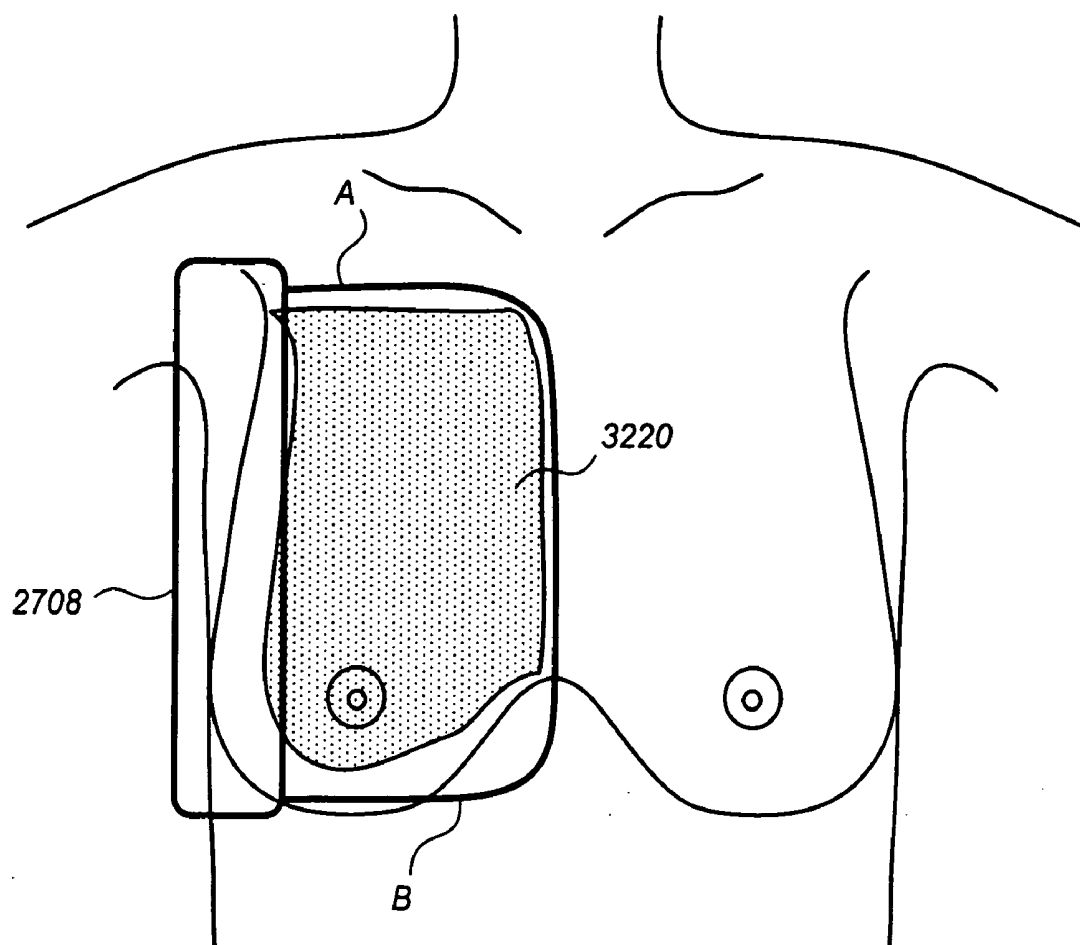


**FIG. 30**



**FIG. 31**

FRONT VIEW



TOP VIEW

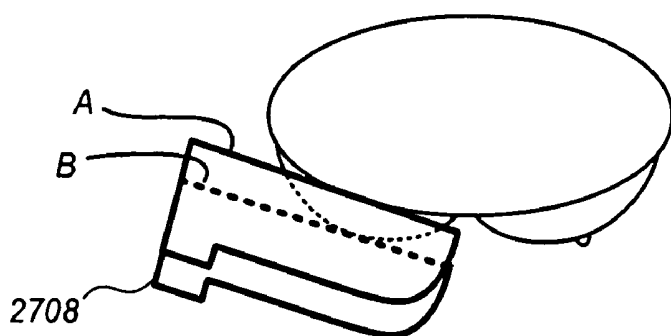


FIG. 32

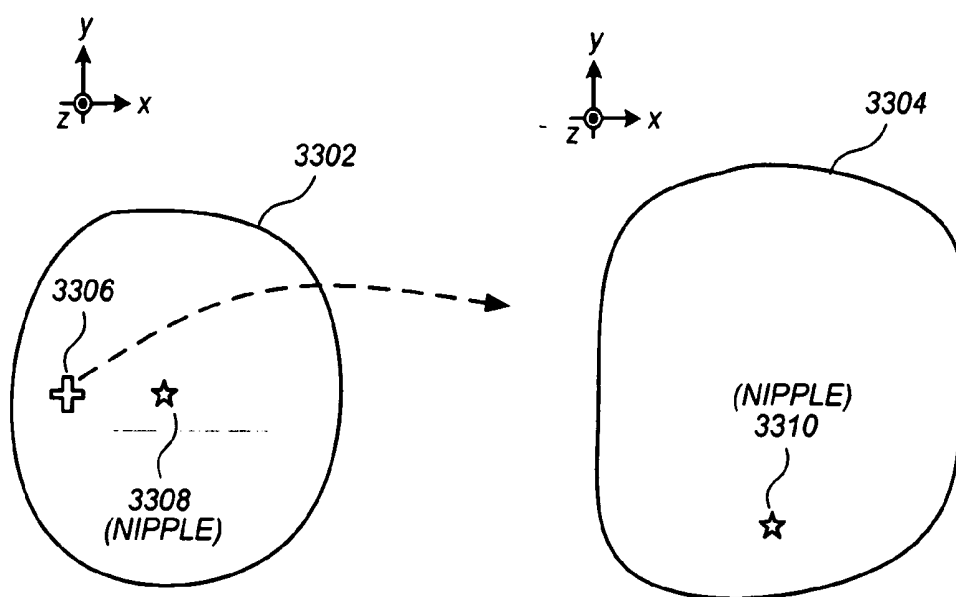


FIG. 33

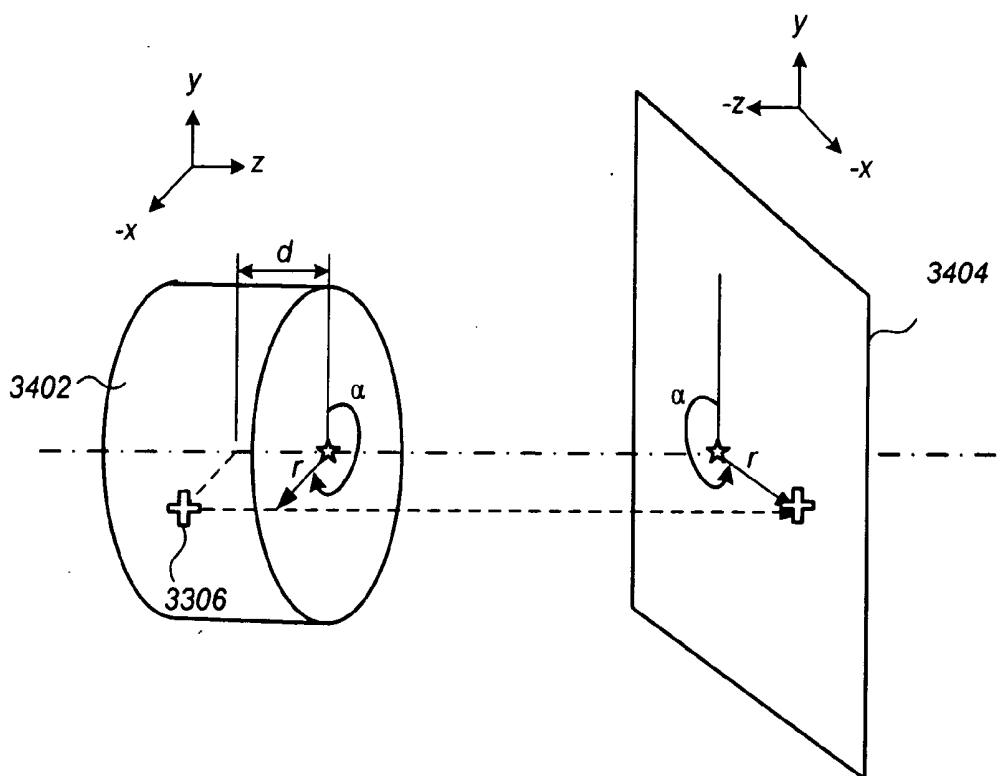
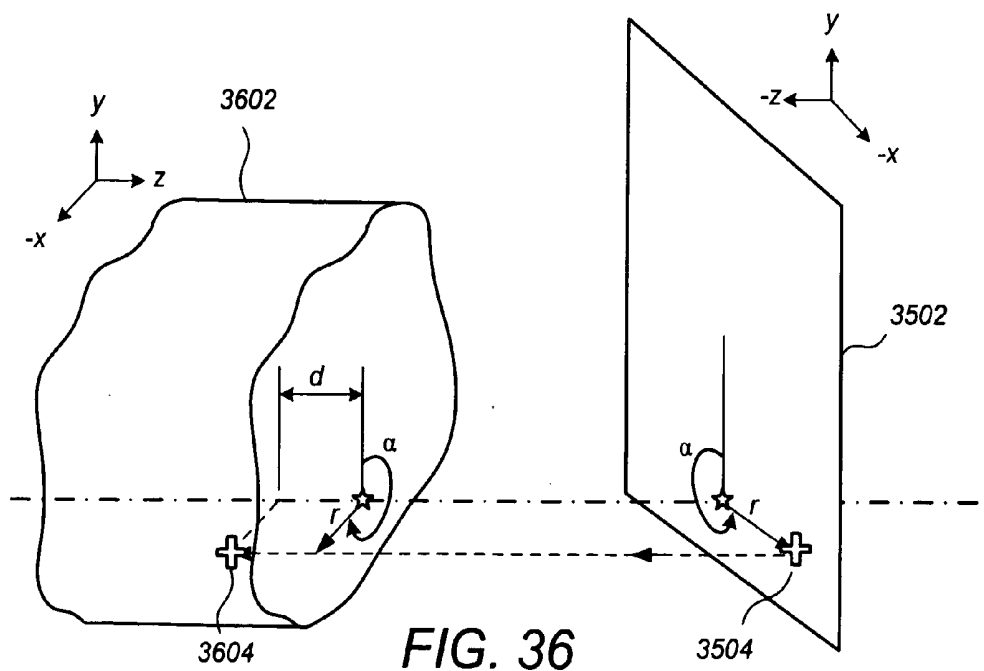
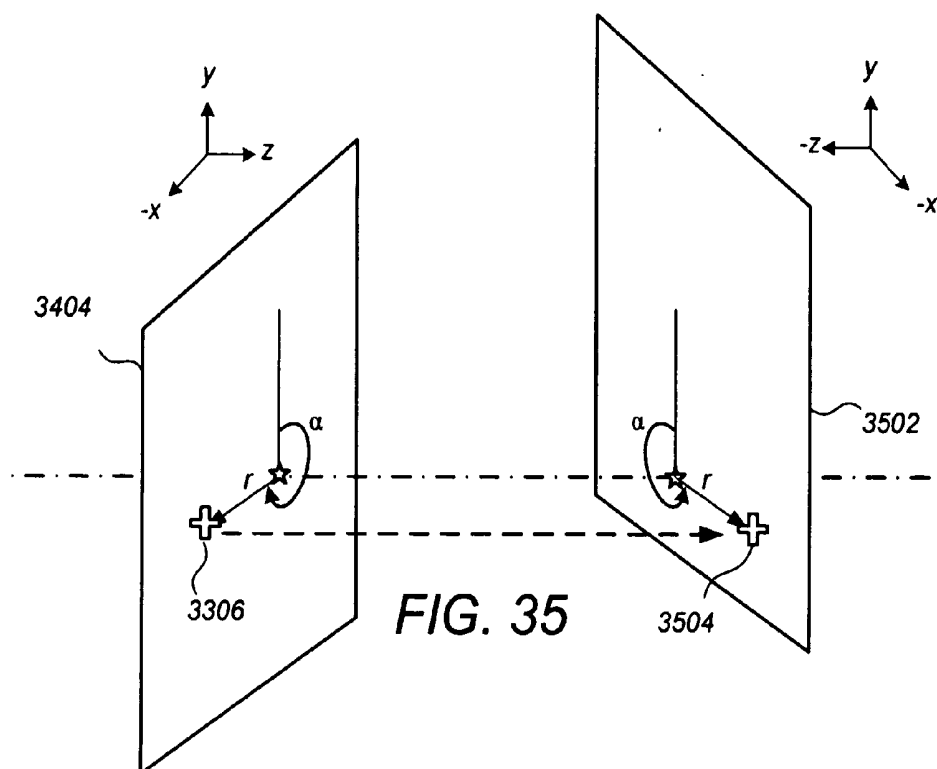


FIG. 34



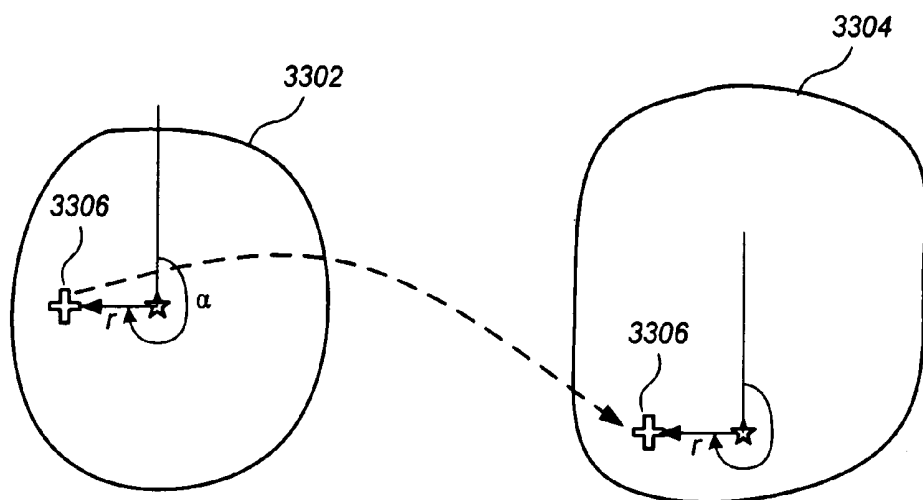


FIG. 37

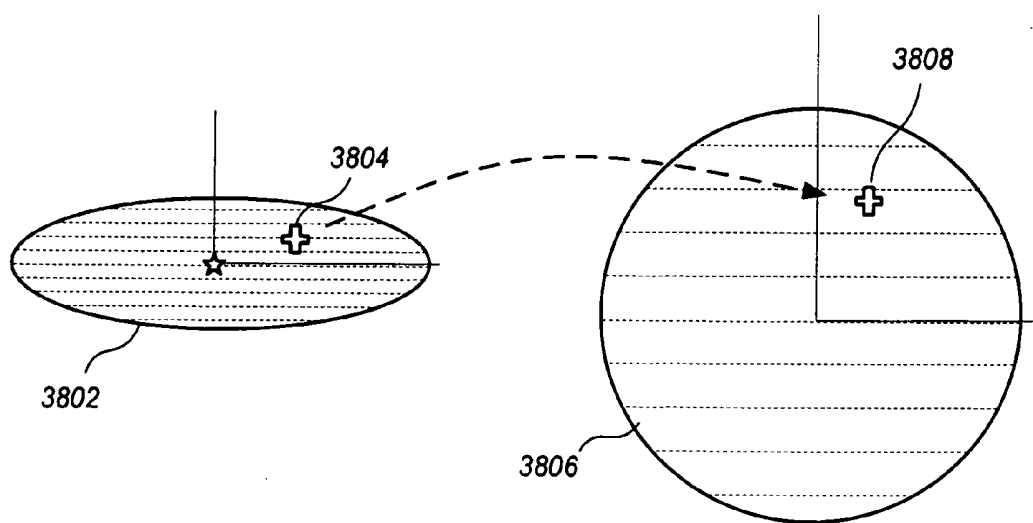


FIG. 38

## NAVIGATION AMONG MULTIPLE BREAST ULTRASOUND VOLUMES

### CROSS-REFERENCE TO RELATED APPLICATIONS

[0001] This application claims the benefit of U.S. Provisional Application No. 60/684,622, filed May 24, 2005, which is incorporated by reference herein.

### FIELD

[0002] This patent specification relates to medical ultrasound imaging. More particularly, this patent specification relates to processing and/or display of breast ultrasound information for breast cancer screening and/or diagnosis purposes.

### BACKGROUND

[0003] The subject matter of this patent specification relates to the processing and display of breast ultrasound information as described, for example, in the commonly assigned US 2003/0007598A1 and US 2003/0212327A1, each of which is incorporated by reference herein. The subject matter of this patent specification also relates to the processing and display of breast ultrasound information acquired according to the commonly assigned U.S. Prov. Ser. No. 60/629,007 filed Nov. 17, 2004, and U.S. Ser. No. 10/997,293 filed Nov. 23, 2005, each of which is incorporated by reference herein.

[0004] In one or more of the above-referenced disclosures, there are presented convenient schemes for viewer navigation between (a) thick-slice images generated from a breast volume and (b) planar ("single-slice") images for that breast volume, as well as navigation in the other direction from the planar images to the thick-slice images. Thus, for example, a viewer can click on a region of interest (ROI) in one of the thick-slice images, and the display will automatically show the appropriate corresponding planar images that pass through that ROI in the breast volume, and will also place markers thereon corresponding to that ROI. This is a valuable capability because the viewer is provided with multiple image presentations of the ROI without having to scan through the various images for corresponding ROIs, which can be a time-consuming and stamina-reducing task. Rather, the viewer simply clicks on the ROI on the image being examined, and that location is automatically "navigated to" and highlighted by the workstation display system in the other views. Generally speaking, such automated navigation between views is not problematic when there is a single ultrasound volume for each breast, because the absolute location of the ROI within the breast becomes known as soon as the viewer clicks on the selected point.

[0005] It has been found desirable in many instances to obtain multiple volumetric ultrasound scans of the same breast during the same session. With reference to FIGS. 28-32 infra, the multiple volumetric ultrasound scans can be head-on scans taken at differing positions or orientations, each of the scans being taken while a taut surface compresses the breast in a generally chestward direction and an ultrasound probe is swept thereacross. In other cases, there may be scans taken while the breast is compressed along differing mammographic planes such as the CC or MLO

planes, as iconically represented, for example, by the body marker icons 1202, 1204, and 1206 of FIG. 12 infra.

[0006] The use of multiple volumetric scans can overcome certain disadvantages associated with of single-volumetric scan scenarios. In particular, for any particular volumetric ultrasound scan, there can be shadowing or other obfuscations of interesting tissue structures because of the presence of other tissue structures that are "in the way" during the scanning process. When there is only a single volumetric scan available, there is generally no way for the viewer to know what structures are behind or underneath the obfuscating structures. However, when there are multiple volumetric ultrasound scans available that were taken from different positions/directions, the viewer can consult a second ultrasound volume to better see the obfuscated structure.

[0007] It would be desirable to streamline the process of viewing additional ultrasonic volumes by providing for automated navigation between a first ultrasonic volume of a breast acquired during a first volumetric scan thereof and a second ultrasonic volume of the same breast taken during a second volumetric scan thereof, the first and second volumetric scans having been taken at differing positions and/or orientations.

### SUMMARY

[0008] A method, system, and associated computer program product is provided for automated navigation between a first ultrasonic volume of a breast acquired during a first volumetric scan thereof and a second ultrasonic volume of the same breast taken during a second volumetric scan thereof. On a display of a breast ultrasound workstation, a first image is displayed, the first image being derived from the first ultrasonic volume and comprising one of (i) a thick-slice image representing the first ultrasonic volume within a slab-like subvolume thereof, and (ii) a planar image representing the first ultrasonic volume along a plane there-through. A user selection of a source region of interest (ROI) in the first image is received. The source ROI is mapped from the first image into the first ultrasonic volume according to the known position of the slab-like subvolume or plane within the first ultrasonic volume. The source ROI is then mapped from within the first ultrasonic volume into a corresponding destination ROI within the second ultrasonic volume of the breast. The destination ROI is then mapped onto a second image, the second image comprising one of (i) a thick-slice image representing the second ultrasonic volume within a slab-like subvolume thereof, and (ii) a planar image representing the second ultrasonic volume along a plane therethrough, this mapping being in accordance with a known position of the slab-like subvolume or plane within the second ultrasonic volume. The second image is displayed to the viewer with the position of the destination ROI therein being highlighted.

[0009] In one preferred embodiment, the mapping from the source ROI within the first ultrasonic volume into the corresponding destination ROI within the second ultrasonic volume first comprises identifying a nipple location of the breast in each of the first and second ultrasonic volumes thereof. A projected location of the source ROI onto a first coronal reference plane passing through the nipple location within the first ultrasonic volume is then identified. A Cartesian offset between the projected source ROI location



and the nipple location on the first coronal reference plane is then determined. That Cartesian offset is then transferred to a second coronal reference plane to identify a transferred offset point thereon, the second coronal reference plane passing through the nipple location within the second ultrasonic volume. The transferred offset point is then back-projected from the second coronal reference plane into the second ultrasonic volume.

[0010] In another preferred embodiment, accommodations are made for compression of the breast along an anti-coronal plane (i.e., along a plane perpendicular to the coronal plane, which would include CC, MLO, and LAT, for example) during one or both of the volumetric scans. In particular, where the breast was so compressed during the first scan or the second scan (but not both), the transferred point on the second coronal reference plane is modified according to an elastic mapping between a coronal projection of the anti-coronally-compressed breast onto a coronal projection of the non-anti-coronally-compressed breast. If the breast was so compressed for both volumetric scans, the breast being compressed along a first anti-coronal plane during the first volumetric scan thereof and compressed along a second anti-coronal plane during the second volumetric scan thereof, the transferred point on the second coronal reference plane is modified according to an elastic mapping between a coronal projection of the breast as compressed along the first anti-coronal plane and a coronal projection of the breast as compressed along the second anti-coronal plane. The elastic mapping is determined at least in part according to a measured compression force and a distance between compression plates during breast compression along the anti-coronal plane.

#### BRIEF DESCRIPTION OF THE DRAWINGS

[0011] FIG. 1 illustrates a conceptual diagram of a breast cancer screening and/or diagnosis system according to a preferred embodiment;

[0012] FIG. 2 illustrates a perspective view of a breast volume and slab-like subvolumes thereof substantially parallel to a coronal plane, and an array of two-dimensional coronal thick-slice images corresponding thereto;

[0013] FIG. 3 illustrates a method for processing and displaying breast ultrasound information according to a preferred embodiment;

[0014] FIG. 4 illustrates a front view of a breast, a front view of slab-like subvolumes thereof substantially parallel to standard x-ray mammogram planes, and arrays of standard-plane thick-slice images corresponding thereto for display in conjunction with the coronal thick-slice images of FIG. 2 according to a preferred embodiment;

[0015] FIG. 5 illustrates a user display according to a preferred embodiment;

[0016] FIGS. 6A and 6B illustrate a side view of a breast and an example of different slab-like coronal subvolume thickness schemes according to a preferred embodiment;

[0017] FIG. 7 illustrates a method for processing and displaying breast ultrasound information according to a preferred embodiment;

[0018] FIG. 8 illustrates a user display according to a preferred embodiment;

[0019] FIG. 9 illustrates a user display according to a preferred embodiment;

[0020] FIG. 10 illustrates a breast ultrasound display according to a preferred embodiment;

[0021] FIG. 11 illustrates a menu bar of a breast ultrasound display according to a preferred embodiment;

[0022] FIGS. 12 and 13 illustrate body marker icons according to a preferred embodiment;

[0023] FIG. 14 illustrates a thick-slice image and planar views according to a preferred embodiment;

[0024] FIG. 15 illustrates a bilateral comparison array of thick-slice images, corresponding body marker icons, and a display control button according to a preferred embodiment;

[0025] FIG. 16 illustrates a bilateral comparison view of thick-slice images and corresponding body marker icons according to a preferred embodiment;

[0026] FIG. 17 illustrates an array of thick-slice images with nipple markers, a body marker icon, and a frontal breast icon according to a preferred embodiment;

[0027] FIG. 18 illustrates a thick-slice image and planar images with displayed bookmarks, a body marker icon, a frontal breast icon, a marker display button, and marker navigation buttons according to a preferred embodiment;

[0028] FIG. 19 illustrates an array of thick-slice images with viewer-shifted nipple markers, a body marker icon, and a frontal breast icon according to a preferred embodiment;

[0029] FIG. 20 illustrates an array of thick-slice images with nipple markers and bookmarks, a marker display button, and marker navigation buttons according to a preferred embodiment;

[0030] FIGS. 21 and 22 illustrate breast ultrasound volume acquisition, processing, and display according to one or more preferred embodiments;

[0031] FIG. 23 illustrates a bilateral comparison array view of thick-slice images and corresponding body marker icons according to a preferred embodiment;

[0032] FIG. 24 illustrates examples of virtual probe reconstruction planes according to a preferred embodiment;

[0033] FIG. 25 illustrates a full-breast composite thick-slice image, a body marker icon, and a frontal breast icon according to a preferred embodiment;

[0034] FIG. 26 illustrates a volume-rendered breast ultrasound volume with surface-rendered computer-assisted diagnosis (CAD) detections therein according to a preferred embodiment.

[0035] FIG. 28 illustrates a diagram of head-on breast ultrasound scanning according to a preferred embodiment;

[0036] FIG. 29 illustrates a diagram of lateral frontal breast ultrasound scanning according to a preferred embodiment;

[0037] FIG. 30 illustrates a diagram of medial frontal breast ultrasound scanning according to a preferred embodiment;

[0038] FIG. 31 illustrates a diagram of inferior frontal breast ultrasound scanning according to a preferred embodiment;

[0039] FIG. 32 illustrates a diagram of superior frontal breast ultrasound scanning according to a preferred embodiment;

[0040] FIG. 33 illustrates thick-slice images from first and second breast ultrasound volumes and a region of interest (ROI) to be mapped from the first breast ultrasound volume to the second breast ultrasound volume according to a preferred embodiment;

[0041] FIG. 34 illustrates a conceptual view of projection of a Cartesian offset from a nipple location in a first breast ultrasound volume to a coronal reference plane according to a preferred embodiment;

[0042] FIGS. 35-36 illustrate transfer of (a) Cartesian offset from the nipple, and (b) depth from the skinline/compressive surface from the first breast ultrasound volume to the second breast ultrasound volume according to a preferred embodiment;

[0043] FIG. 37 illustrates the thick-slice images of FIG. 33 including a highlighted destination ROI according to a preferred embodiment; and

[0044] FIG. 38 illustrates a conceptual view of ROI mapping in which accommodations are made for compression of the breast along one or more anti-coronal planes.

#### DESCRIPTION

[0045] FIG. 1 illustrates a conceptual diagram of a breast cancer screening and/or diagnosis system according to a preferred embodiment. The breast of a patient 101 is ultrasonically scanned by an automated scanning apparatus while the patient is in a prone position (device 102), an upright position (device 102'), a supine position (device 102'') or other position (not shown). By reducing the required ultrasonic penetration depth to the chest wall, scanning of a chestwardly compressed breast can occur at higher frequencies, e.g., 10-20 MHz, which can yield very high resolution images sufficient to facilitate detection of microcalcifications or other structures on the order of 1 mm near the chest wall. However, it is to be appreciated that the scope of the preferred embodiments is not limited to a chestwardly-compressed scenario, with breast ultrasound information processing and display according to the preferred embodiments being generally useful with any scanning system from which a three-dimensional volumetric representation of a sonographic property of the breast can be derived.

[0046] Breast scans are obtained under the control of a scanning engine and workstation 104 including, for example, a monitor 106, keyboard 108, a mouse 110, and a scanning engine (not shown). During or after the scanning process, the ultrasound scan data is provided across a computer network 112 to an ultrasound server 114 that processes and generates display information according to the functionalities described herein. The ultrasound server 114 may perform other HIS/RIS (hospital information system/radiology information system) activities such as archiving, scheduling, etc. It is to be appreciated that the processing of the ultrasound scan data may be performed by any of a variety of different computing devices coupled to the com-

puter network 112 in various combinations without departing from the scope of the preferred embodiments.

[0047] According to a preferred embodiment, a viewing workstation 122 is provided that displays an array 124 of coronal thick-slice images to a clinician 121, each coronal thick-slice image representing a sonographic property of the breast within a slab-like subvolume thereof substantially parallel to a coronal plane. As used herein, the term "clinician" generically refers to a medical professional, such as a radiologist, or other person that analyzes medical images and makes clinical determinations therefrom, it being understood that such person might be titled differently, or might have varying qualifications, depending on the country or locality of their particular medical environment. In another preferred embodiment, as shown in FIG. 1, one or more standard-plane thick slice image arrays are displayed to the clinician 121, such as a craniocaudal (CC) thick-slice image array 126 and a mediolateral oblique (MLO) thick-slice image array 128.

[0048] In another preferred embodiment (not shown), the clinician is also provided with the ability to view individual planar ultrasound slices (along sagittal, axial, coronal, or other cut-planes through the three-dimensional breast volume) as desired. An example of one desirable planar ultrasound display and navigation scheme is provided in the commonly assigned US2003/0212327A1, supra, and in other preferred embodiments described herein.

[0049] FIG. 2 illustrates a perspective view of a breast volume 201 and coronal slab-like subvolumes 204-210 thereof substantially parallel to a coronal plane, along with the array 124 of two-dimensional coronal thick-slice images generated therefrom according to a preferred embodiment. The coronal slab-like subvolumes 204-210, which are separated by planes 202, correspond to the coronal thick-slice images 212-218, respectively. Generally speaking, the coronal slab-like subvolumes nearer to the chest wall (e.g., 204-206) have a larger cross-section in the coronal plane than the slab-like subvolumes nearer to the nipple 203 (e.g., 208-210). As used herein, coronal slab-like subvolumes refer generally to slab-like subvolumes within the breast that are roughly parallel to the chest wall of the patient. The coronal slab-like subvolumes 204-210 typically have a thickness in the range of 2-20 mm. Optionally, the coronal slab-like subvolumes can be gently contoured to more closely follow the contours of the chest wall. In such cases, the coronal slab-like subvolumes would have surfaces roughly reminiscent of a section of a hyperboloid, or roughly reminiscent of a potato chip.

[0050] Generally speaking, a coronal thick-slice image comprises an integration of a plurality of individual ultrasound slices lying within a coronal slab-like subvolume. Thus, for example, where the coronal slab-like subvolume 204 is represented by a three-dimensional voxel array  $V(x, y, z)$  of scalar values, the corresponding coronal thick-slice image 212 would be a two-dimensional pixel array  $P_{COR}(x, y)$  of scalar values. In one preferred embodiment, each pixel value  $P_{COR}(x, y)$  is simply computed as an arithmetic average along the corresponding voxel column at  $(x, y)$  having the voxel values  $V(x, y, z_0), V(x, y, z_1), V(x, y, z_2), \dots, V(x, y, z_N)$ , where  $N$  is the number of individual ultrasound slices lying in the coronal slab-like subvolume. For clarity of

description, the voxel column at (x,y) having the voxel values  $V(x,y,z_0)$ ,  $V(x,y,z_1)$ ,  $V(x,y,z_2)$ , . . . ,  $V(x,y,z_N)$  is expressed herein as  $V_{xy}(z)$ .

**[0051]** Techniques for integrating the component ultrasound slices into the coronal thick-slice images  $P_{COR}(X,y)$  according to the preferred embodiments include arithmetic averaging, geometric averaging, reciprocal averaging, exponential averaging, and other averaging methods, in each case including both weighted and unweighted averaging techniques. Other suitable integration methods may be based on statistical properties of the population of component ultrasound slices at common locations, such as maximum value, minimum value, mean, variance, or other statistical algorithms.

**[0052]** Preferably, the coronal slab-like subvolumes have a thickness related to the size of the lesions to be detected. At an upper end, a larger thickness of 20 mm, for example, may be used if it is desirable to overlook most of the breast details and direct the user's attention to larger features on the order 10 mm in size. At a lower end, a smaller thickness of 2 mm, for example, may be used if it is desirable to view small structures, such as microcalcifications, on the order of 1 mm in size. Thicknesses in the range of 4 mm-10 mm are likely to be suitable for most breast cancer screening purposes.

**[0053]** In other preferred embodiments, the pixel value  $P_{COR}(x,y)$  may be computed according to an algorithm that processes a neighborhood of voxel columns around the voxel column  $V_{xy}(z)$ , the algorithm being designed to result in coronal thick-slice images that emphasize lesions of a predetermined size range. In one such preferred embodiment, the integration method comprises weighting the voxels of the corresponding voxel column by a weighting vector and then summing the results, the weighting vector being computed according to neighborhood characteristics around that voxel column. This can be summarized by Eq. (1) below:

$$P_{COR}(x, y) = FUNC\{V_{xy}(z)\} = \sum_{n=1}^N W_{xy}(n) V_{xy}(z_n) \quad \{1\}$$

**[0054]** Using known three-dimensional segmentation and computer-aided detection (CAD) techniques, the locations and sizes of lesions in the coronal thick-slice volume are identified, either directly or by way of a mapping from the overall three-dimensional breast volume. Any of a variety of known three-dimensional segmentation and/or CAD algorithms can be used such as those discussed in U.S. Pat. No. 6,317,617 to Gilhuijs, Giger, and Bick, which is incorporated by reference herein. In one preferred embodiment, for a given voxel column, the weighting vector  $W_{xy}(n)$  comprises peaks at locations lying within the lesions and valleys elsewhere, thus causing the resulting coronal thick-slice image to emphasize mass lesions in the output. In another preferred embodiment, the weighting vector  $W_{xy}(n)$  can be computed as described in the commonly assigned WO 02/101303A1, which is incorporated by reference herein. The CAD-detected abnormalities can include microcalcifications, suspicious masses, and/or other known breast abnormalities.

**[0055]** FIG. 3 illustrates a method for processing and displaying breast ultrasound information according to a preferred embodiment. At step 302, volumetric ultrasound scans of the chestwardly-compressed breast are acquired, either in real-time as the breast is being scanned, or in an off-line manner as from a database or archive of previously-acquired images. At step 304, coronal thick-slice images are computed corresponding to slab-like subvolumes of the chestwardly-compressed breast substantially parallel to coronal plane. At step 306, the array of coronal thick-slice images is displayed on a user display, preferably in a side-by-side manner. However, a variety of different spatial arrangements of the coronal thick-slice images are within the scope of the preferred embodiments. For example, the array may be presented in circular or matrix fashion. In one preferred embodiment, all of the coronal thick-slice images collectively corresponding to the entire breast volume are simultaneously displayed to the viewer, so that the whole breast is effectively shown at the same time, thereby facilitating clinical workflow efficiency. In another preferred embodiment, the coronal thick-slice images can be progressively displayed at successive time intervals, either automatically or responsive to user controls.

**[0056]** According to one preferred embodiment, at step 308 craniocaudal (CC) thick-slice images, which are one type of standard-plane thick-slice image, are computed corresponding to slab-like subvolumes of the chestwardly-compressed breast substantially parallel to an axial plane, which corresponds to the CC view. At step 310 mediolateral oblique (MLO) thick-slice images, which are another type of standard-plane thick-slice image, are computed corresponding to slab-like subvolumes of the chestwardly-compressed breast substantially parallel to an MLO plane. At step 312, the arrays of CC and MLO thick-slice images are presented on the user display.

**[0057]** FIG. 4 illustrates a conceptual front view of the breast 201 upon which are drawn (i) front-view outlines of slab-like subvolumes A-H corresponding to CC slab-like subvolumes, and (ii) front-view outlines of slab-like subvolumes I-VI corresponding to MLO slab-like subvolumes. Also shown in FIG. 4 is a portion of the viewing workstation 122 illustrating the CC thick-slice image array 126 and the MLO thick-slice image array 128 with indicators mapping them into the slab-like subvolumes A-H and I-VI, respectively. The CC and MLO thick-slice image arrays can be generated from the three-dimensional breast volume in a manner analogous to that described in WO 02/101303A1, supra. As known in the art, the MLO plane is usually about 55 degrees away from the CC plane. It is to be appreciated, however, that a variety of angles for the MLO plane can be used without departing from the scope of the preferred embodiments, including 90 degrees (in which case it corresponds to the mediolateral "ML" view) or greater.

**[0058]** Referring again to FIG. 3, according to one preferred embodiment, standard CC and MLO x-ray mammogram views of the breast are displayed at steps 314 and 316, respectively. FIG. 5 illustrates a viewing workstation 502 similar to the viewing workstation 122, supra, with the addition of CC and MLO x-ray mammogram images 504 and 506, respectively, which can further facilitate screening and diagnosis through back-and-forth viewing of interesting areas. The CC and MLO x-ray mammogram images 504 and 506 are preferably in digitized form for practical reasons,

although it is within the scope of the preferred embodiments for these to be film-based x-ray mammograms on a light-box background.

[0059] FIGS. 6A and 6B illustrate side views of a breast 201 next to a chest wall 602 for the purpose of describing coronal slab-like subvolume thickness schemes according to the preferred embodiments. In the preferred embodiment of FIG. 6A, the thicknesses of coronal slab-like subvolumes 1-5 are substantially equal. However, in the preferred embodiment of FIG. 6B, there is a graded or phased approach to the thicknesses of coronal slab-like subvolumes 1-5. More particularly, the inner subvolumes 1-2 are thinner than the outer subvolumes 4-5. Thus, an average thickness of a first subset of said slab-like subvolumes located closer to the chest wall is less than an average thickness of a second subset of said slab-like subvolumes located farther from the chest wall.

[0060] The graded or phased approach of FIG. 6B has been found advantageous because a large percentage of breast lesions are nearby to the chest wall, and so a more precise viewing of these tissues (i.e., approaching the precision of conventional thin-slice ultrasound images) is warranted. At the same time, however, it is still desirable to avoid "too much information" on the user display, and so thicker subvolumes for the regions farther away from the chest wall are used to keep the overall number of required images at manageable levels.

[0061] FIG. 7 illustrates a method for processing and displaying breast ultrasound information according to a preferred embodiment. At step 702, the three-dimensional data volume is processed according to at least one computer-aided detection (CAD) algorithm to detect anatomical abnormalities therein. These CAD algorithms can be the same as used supra for enhancing the visual appearance of lesions in the thick-slice images, or alternatively can be different and/or additional CAD algorithms. At step 704, the detected lesions in the three-dimensional data volume are mapped into their corresponding coronal thick-slice images. The detected lesions are also mapped into their corresponding CC and/or MLO thick-slice images if present. At step 706, annotations are superimposed on the corresponding coronal, CC, and/or MLO thick-slice images according to type and location of detected anatomical abnormality.

[0062] FIG. 8 illustrates a viewing workstation 802 according to a preferred embodiment, which is similar to the viewing workstation 122 but also includes CAD annotations on the coronal, CC, and MLO thick-slice images. The CAD annotations are placed according to type and location of detected anatomical abnormality. In the example of FIG. 8, a CAD-detected suspicious microcalcification cluster is denoted by triangles 804a, 804b, and 804c on the appropriate members of the coronal, CC, and MLO thick-slice image arrays, respectively. A CAD-detected suspicious mass is denoted by asterisk-shaped markers 806a, 806b, and 806c on the appropriate members of the coronal, CC, and MLO thick-slice image arrays, respectively. 10063FIG. 9 illustrates a portion 902 of a viewing workstation according to a preferred embodiment, including an array 904 of coronal thick-slice images. It has been found useful to identify the x-y location of the nipple relative to the coronal thick-slice images on the user display, as indicated by the nipple markers 906. For example, it will not always be the case that

the nipple will be at the center of each coronal thick-slice image, for anatomical reasons as well as the fact that there may be variations in the angle of attack of the chestward compressive force on the breast. These variations in the angle of attack may be unintentional, as in the case of imperfect patient positioning, or may be intentional, as in the case where a particular area of the breast (e.g., the upper inner quadrant) may be of concern in a follow-up scan. The position of the nipple can be determined using CAD algorithms on the three-dimensional data volume based on nipple shadow effects. Alternatively, the nipple position may be identified manually by the technician at the time of scanning, e.g., by ensuring that the nipple falls on a predetermined point on the compression plate, or by interacting with the scanning system based on a quick exploratory sweep across the breast by the probe, or by manually positioning the probe at the nipple location and pressing a nipple identification button, or by any of a variety of other manual nipple identification schemes.

[0063] FIG. 10 illustrates a breast ultrasound display 1002 according to a preferred embodiment, generally comprising an image area 1004 and a menu bar 1006. In the particular display of FIG. 10, an array of six thick-slice images 1008a-1008e is displayed, as well as two planar ultrasound images 1010a-1010b. The display 1002 can be used in the viewing workstation 122 of FIG. 1, supra. The display 1002 can be used as part of a multi-modality PACS workstation, as a stand-alone device, and/or in conjunction with an x-ray mammography softcopy or hardcopy (i.e., lightbox) viewing station.

[0064] FIG. 11 illustrates a closer view of the menu bar 1006 comprising a variety of controls and information displays relating to the image area 1004. Menu bar 1006 comprises a body marker icon 1102, cine control (soft) buttons 1103, a marker display button 1104, marker navigation buttons 1106, a bilateral comparison control button 1108, a somogram button 1110, an invert button 1112, and a variety of file control buttons 1114. A designation of "N" (N=2, 3, ...) on a view-related one of the file control buttons 1114 indicates that N sets of data are available for display for that view, e.g., N scans were taken corresponding to that view. The number preceding the "N" denotes which of those sets is being displayed.

[0065] The cine control buttons 1103 allow the viewer to start a slice-by-slice ultrasound view cine loop sequence of the current breast view. It will start at the current cursor location, moving toward a first edge of the breast volume. It will delay there for a short period of time, then restart at the other edge of the breast volume. Pressing any button or moving the mouse while the cine is active will stop the cine loop, leaving the cursor at its most recent cine position. The invert button 1112 enables toggling of the thick-slice images between two different grayscale mapping modes, one for a generally white-on-black image mode, and another for a generally black-on-white image mode.

[0066] The bilateral comparison control button 1108 allows the viewer to dynamically toggle between displaying a bilateral comparison view format, as described further infra with respect to FIGS. 15-16 and FIGS. 19-20, or thick-slice views of a single breast. The somogram button 1110 allows the viewer to toggle between a first configuration in which only planar views are shown, a second

configuration in which only thick-slice images are shown, and a third configuration in which combinations of thick-slice images and planar images are shown.

[0067] The marker display button **1104** allows the viewer to toggle between (i) non-annotated versions of the displayed images, and (ii) versions showing bookmarks as described further infra. The marker navigation buttons **1106** allow the viewer to perform bookmark-centric navigation wherein, upon selection, there is automatically displayed a corresponding one of the thick-slice images associated with a location of a next bookmark (forward) or prior bookmark (backward), as well as a one or more planar ultrasound images corresponding to that location. The bookmarks themselves may be entered by the viewer using a simple right-click and pull-down menu process, although the scope of the preferred embodiments is not so limited. By way of example, bookmarks may be provided by other users, automatically generated according to archived data, or by any of a variety of other processes.

[0068] Although not shown in FIG. 11, in another preferred embodiment there is provided a CAD display button and CAD navigation buttons providing similar navigational functionality as the marker display button **1104** and the marker navigation buttons **1106**. In still another preferred embodiment, a nipple marker display button is provided for toggling between displaying nipple markers, described further infra, and not displaying nipple markers.

[0069] Body marker icon **1102** is automatically generated and provides fast communication of several different aspects of the images being displayed. A text section **1116** communicates a compression angle (for non-frontal, i.e., non-coronal, compression planes such as CC, MLO, LAT, etc.), a separation distance between compression plates (again for non-frontal compression planes), and a compression force used during the scans. The body marker icon **1102** further displays a compression plane **1117** against which the breast was compressed, a thick-slice depth marker **1118** corresponding to the depth of the displayed thick-slice image (when one thick-slice image is displayed), and a plane marker **1120** corresponding to a planar ultrasound image being displayed, if applicable.

[0070] FIG. 12 illustrates body marker icons for various non-frontal compression scenarios. The body marker icon **1202** corresponds to a LAT view of the right breast, the body marker icon **1204** corresponds to a CC view of the right breast, and the body marker icon **1206** corresponds to an MLO view of the left breast.

[0071] FIG. 13 illustrates body marker icons **1302**, **1304**, and **1306** for various frontal compression scenarios, each comprising a probe sweep indicator (e.g., **1303**) indicating a trajectory and orientation of the linear scanning probe that scanned the breast. The body marker icon **1302** corresponds to a frontal scan of a medial side of the left breast in the inferior-to-superior direction, the body marker icon **1306** corresponds to a frontal scan of a medial side of the right breast in a direction close to the inferior-to-superior direction, and the body marker icon **1304** corresponds to a frontal scan of the center area of the left breast in a direction close to a lateral-to-medial direction.

[0072] FIG. 14 illustrates a single thick-slice image **1401**, which corresponds to the thick-slice image **1008** when the

cursor is clicked at the location indicated in FIG. 10. It is to be appreciated that the menu bar **1006** is preferably displayed below all images but is omitted in this and subsequent figures for clarity. FIG. 14 further illustrates planar ultrasound images **1406** and **1408** corresponding respectively to the plane indicators **1402** and **1404**, which intersect at the current cursor location.

[0073] FIG. 15 illustrates a bilateral comparison array **1502** of thick-slice images that is accessed by selection of the bilateral comparison control button **1108**, comprising members of an LMLO thick-slice image array as positionally paired with corresponding members of an RMLO thick-slice image array, wherein the slab-like subvolumes of the left breast corresponding to the LMLO thick-slice image array have an at least general positionwise association with the slab-like subvolumes of the right breast corresponding to the RMLO thick-slice image array. A body marker icon **1504** illustrates the scanning orientations and other scanning parameters associated with each of the volumetric scans.

[0074] FIG. 16 illustrates an expanded bilateral comparison view **1602** of the fourth thick-slice image pair of the bilateral comparison array **1502**, which is displayed to when either of those fourth thick-slice images is clicked by the viewer on the display of FIG. 15. A body marker icon **1604** includes thick-slice depth markers **1606** showing the location of the fourth thick-slice subvolume within each of the left and right breasts. Nipple locations are also indicated on the body marker icon **1602**.

[0075] Notably, it is not required that the associations between slab-like subvolumes of the left and right breasts be precise for the preferred embodiments of FIGS. 15-16. The opposing breasts can be of different sizes and there can be many incidental variations between the ways they were scanned. Nevertheless, it has been found highly useful to present thick-slice image data in bilateral comparison formats such as those of FIGS. 15-16. For example, breast symmetry is readily analyzed.

[0076] FIG. 17 illustrates an array of thick-slice images **1702**, two planar images **1704a-b** corresponding to a current cursor position **1708** on a selected thick-slice image, a body marker icon **1710**, nipple markers **1706**, and a frontal breast icon **1712** according to a preferred embodiment. The nipple markers **1706** can be placed on the thick-slice images according to any of (i) a manually-entered nipple position provided with the associated volumetric ultrasound scan, (ii) a computer-derived nipple position automatically generated from the associated volumetric ultrasound scan, (iii) a computer-derived nipple position automatically generated based on manual placement of a physical nipple token for the associated volumetric ultrasound scan, and (iv) a viewer-determined position for the nipple marker. Physical nipple token can refer to a marker placed on the skin of the breast at the nipple location that is at least partially transparent to ultrasound but that also provides a degree of obscuration sufficient for automatic identification of its presence. Examples can include small silicone toroids, optionally with specks of metal therein, or any of a variety of other objects that can have similar effects. Physical nipple token can alternatively refer to a such a marker placed on the ultrasound scanning device itself, e.g., on one of the compression plates, at the nipple location.

[0077] Frontal breast icon **1712** comprises a cursor position indicator **1716** variably disposed thereon in a manner

that reflects a relative position between the cursor **1708** and the nipple marker **1706** on the selected thick-slice image. Preferably, the frontal breast icon **1712** has a layout at least roughly resembling a clock face, and the cursor position indicator **1716** is positioned relative to the center of that clock face to reflect both (i) the distance "D" between the cursor **1708** and the nipple marker **1706**, and (ii) the direction of the cursor **1708** from the nipple marker **1706** on the display (e.g., about 1:00 in the example of FIG. 17). The location of the cursor position indicator **1716** dynamically moves on the clock face as the cursor **1708** is moved around the thick-slice image. The combined display of the frontal breast icon **1712** and the body marker icon **1710** facilitates quick, intuitive comprehension of the physical and positional relevance of the images being displayed. Frontal breast icon **1712** further comprises a text portion **1714** numerically indicating (i) the distance "D," and (ii) the depth of the currently selected thick-slice image from the compressed surface across which the ultrasound probe was swept.

[0078] FIG. 18 illustrates a thick-slice image **1802**, two planar images **1804a-b** corresponding to a current cursor position on the thick-slice image, a body marker icon **1810**, nipple markers **1806**, a plurality of bookmarks **1822**, **1824**, and **1826**, and a frontal breast icon **1812**. According to a preferred embodiment, the bookmarks are projected onto corresponding locations of the currently displayed planar images **1804a-b**, if applicable, under an assumption that the bookmark spot is volumetrically in the middle plane of the slab-like subvolume corresponding to the thick-slice image. Accordingly, FIG. 18 illustrates corresponding bookmarks **1822'** and **1824'** on the superior-inferior planar image **1804b**, because the bookmarks **1822** and **1824** lie along the vertical plane indicator **1825** passing through the current cursor location. The medial-lateral planar image **1804a** only shows a corresponding bookmark **1822''** because only the bookmark **1822** lies along the horizontal plane indicator **1827**. Since neither plane indicator **1825** or **1827** intersects the bookmark **1826**, there is no corresponding bookmark on the planar images **1804a-b** for that bookmark.

[0079] The presence of all of the bookmarks can be toggled on and off by pressing the marker display button **1104**. The marker navigation buttons **1106** allow the viewer to perform bookmark-centric navigation wherein, upon selection, the cursor is moved to a next bookmark (forward) or prior bookmark (backward), and the corresponding planar images are instantly displayed. As a default setting, navigation among the bookmarks is ordered in the same order as the bookmarks were entered by the viewer, although the scope of the preferred embodiments is not so limited. In the example of FIG. 18, the viewer has just pressed the one of the marker navigation buttons and has landed at the bookmark **1822**. Notably, as indicated by the cursor position indicator **1816**, the frontal breast icon **1812** keeps up automatically with the current cursor position, which in FIG. 18 is about 3 cm from the nipple marker location at a clock angle of roughly 4:00. The nipple markers and bookmarks can have any of a variety of shapes, sizes, colors, etc. without departing from the scope of the preferred embodiments.

[0080] FIG. 19 illustrates an array of thick-slice images **1902** with nipple markers **1906** that have been shifted by the viewer (using a click-and-drag method, for example).

Although not necessarily warranted in this example (because the original position appears accurate based on nipple shadow positions), it may be desirable for the viewer to move the nipple marker location based on their observations, or on other extrinsic information. The position of the cursor **1908** relative to the nipple marker **1906** having shifted, the position of the cursor position indicator **1916** automatically shifts on the clock face of the frontal breast icon from **1916-old** to **1916-new** (e.g., from about 0.5 cm at 12:00 to about 3 cm at 4:00).

[0081] FIG. 20 illustrates an array of thick-slice images **2002** with bookmarks **2010**, **2011**, **2012**, and **2013** placed thereon, for illustrating a multi-slice bookmark-centric navigation process according to a preferred embodiment. By the viewer clicking on the forward marker navigation button **1106**, the cursor is instantly taken to the next bookmark, and corresponding planar images (not shown) are displayed.

[0082] Generally speaking, as in the example of FIG. 20, there will often be bookmarks on several of the thick-slice images. Convenient navigation analogous to that shown in FIG. 20 is provided when only one of the thick-slice images is displayed at a time (see, e.g., FIG. 14, supra). In particular, when only a single thick-slice image is being shown and one of the marker navigation buttons **1106** is pressed, the current thick-slice image is replaced (if applicable) with a next thick-slice image corresponding to a next bookmark, and the cursor is placed at the next bookmark in that thick-slice image with corresponding planar views being displayed. Rapid navigation among bookmarks is thereby achieved.

[0083] In another preferred embodiment, similar navigation capabilities are provided among CAD detections, i.e., by the viewer clicking on a CAD navigation button, the cursor is instantly taken to the next CAD marker location, and corresponding planar images are displayed. Among other advantages, bookmark-centric and/or CAD-centric navigation according to the preferred embodiments can substantially reduce the time needed to examine a case and increase radiologist productivity.

[0084] FIG. 21 illustrates breast ultrasound volume processing and display according to a preferred embodiment. At step **2102**, nipple position is obtained either manually or in an automated manner relative to an acquired breast volume that is preferably chestwardly-compressed for head-on scanning. At step **2104**, one or more thick-slice ultrasound images is displayed. At step **2106**, nipple markers are shown on the thick-slice image(s), the nipple marker positions representing a projection of the nipple location thereupon. At step **2108**, the current cursor position relative to the displayed nipple marker position is communicated on a clock face style icon. At step **2110**, the viewer is allowed to change the nipple marker position relative to the breast volume through direct interaction on thick-slice image(s).

[0085] FIG. 22 illustrates breast ultrasound volume processing and display according to a preferred embodiment. At step **2202**, bookmarks are added via bookmarking commands, e.g., through a right-click and drop-down menu style command upon a thick-slice image or a planar image. At step **2204**, that bookmark location is associated with its corresponding location within the 3D breast volume. At step **2206**, that bookmark is projected onto all relevant displayed thick-slice and planar ultrasound images as required to properly reflect its position in the 3D breast volume. If a

marker navigation command is received at step **2208**, then the display automatically navigates to a next bookmark location and shows the appropriate thick-slice image and corresponding planar images at step **2210**.

[**0086**] FIG. **23** illustrates a bilateral comparison array **2302** of thick-slice images that is easily navigated to by selection of the bilateral comparison control button **1108**, supra, comprising members of an LAP (left anterior-posterior) thick-slice image array as positionally paired with corresponding members of an RAP (right anterior-posterior) thick-slice image array, wherein the slab-like subvolumes of the left breast corresponding to the LAP thick-slice image array have an at least general positionwise association with the slab-like subvolumes of the right breast corresponding to the RAP thick-slice image array. A body marker icon **2304** illustrates the scanning orientations for each breast volume.

[**0087**] FIG. **24** illustrates examples of a virtual probe reconstruction (VPR) plane “S” around a point “P” within a breast volume **2402** according to a preferred embodiment. The viewer is provided with a pointing device, which can be the regular mouse in a particular mode, or which can be a separate joystick or similar control. With at least one thick-slice image and at least one planar image being displayed, the viewer can invoke a VPR command for the present cursor position. This causes the cursor to freeze at the present location “P” within the breast volume, wherein the viewer can then change the orientation of the plane “S” corresponding to the displayed planar image from a normal “vertical” position within the breast volume, see FIG. **24** at (i), to any of a variety of different orientations under control of the pointing device. For example, as indicated in FIG. **24**, there is provided a roll capability, see FIG. **24** at (ii), a yaw capability, see FIG. **24** at (iii), and combinations of roll and yaw, see FIG. **24** at (iv).

[**0088**] FIG. **25** illustrates a full-breast composite thick-slice image **2502**, corresponding planar images **2504a-b**, a body marker icon **2510**, and a frontal breast icon **2512** according to a preferred embodiment. Composite thick-slice image **2502** is preferably a CAD-enhanced expression of the sonographic properties of substantially the entire breast volume, i.e., all of the tissue imaged by the volumetric ultrasound scans. Any of a variety of CAD algorithms can be used such as those discussed U.S. Pat. No. 6,317,617, supra, and those described in the commonly assigned WO 03/101303 A1, supra. The lesions can then be enhanced according to their likelihood of malignancy (or other metric of interest) on the composite thick-slice image **2502**. The composite thick-slice image **2502** can serve as a useful “guide” or “road map” for viewing the planar ultrasound images and the other thick-slice images, and can optionally be provided with explicit CAD markings near the enhanced lesion locations.

[**0089**] FIG. **26** illustrates a display **2602** comprising a volume-rendered breast ultrasound volume **2604** with surface-rendered computer-assisted diagnosis (CAD) detections **2606** therein according to a preferred embodiment. A three-dimensional nipple marker **2608** is provided to properly orient the viewer in visualizing the breast volume. In one preferred embodiment, the volume-rendered breast ultrasound volume **2604** is rotated in a cine-like fashion, as indicated by the sequence A-D in FIG. **26**.

[**0090**] Whereas many alterations and modifications of the present invention will no doubt become apparent to a person

of ordinary skill in the art after having read the foregoing description, it is to be understood that the particular embodiments shown and described by way of illustration are in no way intended to be considered limiting. By way of example, although primarily described supra in the context of ultrasound imaging, it is to be appreciated that data from other full-field breast imaging modalities (e.g., MRI, CT, PET) can be advantageously processed and displayed according to one or more of the described preferred embodiments. One or more of the displays described herein is similar to SOMOGRAM™ displays provided by U-Systems, Inc. of San Jose, Calif. By way of further example, although described supra as being volumetrically segregated, the coronal slab-like subvolumes from which the coronal thick-slice images are computed can be partially overlapping, which can be useful in dealing with lesions that would otherwise straddle the borders of the subvolumes. By way of even further example, although most nipple markers are described in the preferred embodiments supra in the context of coronal thick-slice images, in other preferred embodiments the nipple markers are shown on the MLO, CC, and other thick-slice image views.

[**0091**] By way of further example, it is to be appreciated that substantially parallel to a coronal plane is used herein to generally reflect the practical realities of situations such as head-on scanning of the breast, and that there may be some deviation from the plane of the chest wall. For example, for a particular patient having highly pendulous breasts it might be found most optimal to compress the breast at some small angle, such as 15 degrees, away from the plane of the chest wall. In this case, slab-like subvolumes that are taken parallel to the plane of compression would still be considered substantially parallel to the coronal plane.

[**0092**] By way of still further example, in alternative preferred embodiments the coronal slab-like subvolumes described supra can be replaced by thin-slice coronal images, i.e. thin-slice planar ultrasound images along planes substantially parallel to a coronal plane. This can be particularly useful in a follow-up diagnosis setting in which fine details are desired for viewing. By way of still further example, in another alternative preferred embodiment, the clinician is given the ability to interchangeably switch among, or pick-and-choose between, displaying the coronal slab-like subvolumes and the thin-slice coronal images. Therefore, reference to the details of the preferred embodiments are not intended to limit their scope, which is limited only by the scope of the claims set forth below.

[**0093**] FIG. **27** illustrates a perspective view of a full-field breast ultrasound (FFBU) scanning apparatus **2702** according to a preferred embodiment, comprising a frame **2704** that may contain an ultrasound processor, a movable support arm **2706**, a compression/scanning assembly **2708** connected to the support arm **2706** via a ball-and-socket connector **2712**, and a monitor **2710** connected to the support arm **2706** at a joint **2714**. Preferably, the support arm **2706** is configured and adapted such that the compression/scanning assembly **2708** is either (i) neutrally buoyant in space, or (ii) has a light net downward weight (e.g., 2-3 pounds) for breast compression, while allowing for easy user manipulation. According to a preferred embodiment, the compression/scanning assembly **2708** comprises an at least partially conformable membrane **2718** in a substantially taut state, the membrane **2718** having a bottom surface contacting the breast while a

transducer is swept across a top surface thereof to scan the breast. Optionally, the support arm **2706** may comprise potentiometers (not shown) to allow position and orientation sensing for the compression/scanning assembly **2708**, or other types of position and orientation sensing (e.g., gyroscopic, magnetic, optical) can be used. By way of example and not by way of limitation, a miniBIRD® 3D position sensor from Ascension Technologies can be used to determine the position and orientation of the compression/scanning assembly **2708** on a per-frame basis.

[0094] Within frame **2704** may be provided a fully functional ultrasound engine for driving an ultrasound transducer and generating volumetric breast ultrasound data from the scans in conjunction with the associated position and orientation information. The volumetric scan data can be transferred to another computer system for further processing using any of a variety of data transfer methods known in the art. A general purpose computer, which can be implemented on the same computer as the ultrasound engine, is also provided for general user interfacing and system control. The general purpose computer can be a self-contained stand-alone unit, or can be remotely controlled, configured, and/or monitored by a remote station connected across a network.

[0095] The compression/scanning assembly **2708** is preferably a substantially self-contained, pod-like module that can be grasped by the hands of a user and manipulated to compress the breast in a generally chestward direction. By generally chestward, it is meant that membrane **2718** of the compression/scanning assembly **2708** urges the breast surface toward the chest wall of the patient while the membrane is an angle of 45 degrees or less from a coronal plane. It has been found that, generally speaking, the breasts of supine or reclining women can have many different tendencies depending on the anatomy of the woman. For example, for first fully supine woman the breast may droop upward toward the shoulder, while for a second fully supine woman the breast may droop downward toward the abdomen or inward toward the sternum. For these breasts it may be desirable to tilt the scanning surface somewhat relative to the coronal plane, obtaining a scan of the breast while pushing the breast at least partially sideways toward the theoretical center of the breast and while also pushing it inward toward the chest wall.

[0096] Notably, the scope of the preferred embodiments is not limited to the above-referenced angles relative to the coronal plane. In other preferred embodiments any of a variety of different angles and orientations may be used, depending on the circumstances.

[0097] FIG. **28** illustrates a diagram of head-on breast ultrasound scanning according to a preferred embodiment, in which a breast **2802** of a patient **2804** is scanned using the compression/scanning assembly **2708** of FIG. **12**, supra. More generally any similar assembly having a substantially planar scanning surface that is rigid or semi-rigid as compared to the general softness of a breast can be used. For some clinical settings and/or patient groups, it is often considered sufficient to use a single head-on scan to volumetrically image a dense-disk region **2212** of the breast, the compressive surface being substantially parallel to the coronal plane and chestwardly pressed against the breast.

[0098] In other clinical settings and/or for other patient groups, it is often desired to more thoroughly scan the breast

by obtaining ancillary compressive scans at one or more off-coronal angles. However, according to a preferred embodiment, at least some degree of systemization and/or standardization is maintained by using lateral frontal, medial frontal, inferior frontal, and/or superior frontal compression and scanning orientations as described herein. In one preferred embodiment, the image volumes acquired from the ancillary compressive scans are used to supplement the image volume acquired from the head-on scan. In another embodiment, the single head-on scans are omitted and only the image volumes acquired from the ancillary compressive scans are used.

[0099] FIG. **29** illustrates a diagram of lateral frontal breast ultrasound scanning according to a preferred embodiment, in which the compression/scanning assembly **2708** is manipulated to image a lateral frontal region **2914**. Preferably, in a positioning process preceding the probe sweep, one side of the compressive surface is pinned adjacent to the outer edge of the breast (near the line C-C' in FIG. **29**) and then the compressive surface is "rolled" toward the medial side of the breast, until a position is reached in which the compressive surface would lift away from C-C' if the rolling continued. This has been found to allow capturing of a relatively large lateral frontal region **2914** that usually includes the nipple, while also minimizing small air pockets, bubbles, etc. that can degrade image quality.

[0100] FIG. **30** illustrates a diagram of medial frontal breast ultrasound scanning according to a preferred embodiment, in which the compression/scanning assembly **2708** is manipulated to image a medial frontal region **3016**. In a manner analogous to the lateral frontal scan, one side of the compressive surface is preferably pinned adjacent to the medial edge of the breast (near the line C-C' in FIG. **30**) and then the compressive surface is "rolled" toward the outer side of the breast, until a position is reached in which the compressive surface would lift away from C-C' if the rolling continued.

[0101] FIG. **31** illustrates a diagram of inferior frontal breast ultrasound scanning according to a preferred embodiment, in which the compression/scanning assembly **2708** is manipulated to image an inferior frontal region **3118**. In a manner analogous to the lateral and medial frontal scans, one side of the compressive surface is pinned at the inferior mammary fold (IMF, near the line C-C' in FIG. **31**) and then the compressive surface is "rolled" upward toward the superior surface of the breast, until a position is reached in which the compressive surface would lift away from C-C' if the rolling continued. FIG. **32** illustrates a diagram of superior frontal breast ultrasound scanning according to a preferred embodiment, in which the compression/scanning assembly **2708** is manipulated to image a superior frontal region **3220**.

[0102] In one embodiment, the number and selection of ancillary compressive scans is determined according to a size category of the breast. For a small breast, the lateral frontal scan (FIG. **29**) and the medial frontal scan (FIG. **30**) can suffice to ultrasonically image the clinically relevant tissues. For a medium sized breast, the inferior frontal scan (FIG. **31**) is acquired in addition to the lateral and medial frontal scans to facilitate sufficient imaging of the clinically relevant tissues. For a large-sized breast, the superior frontal scan (FIG. **32**) is acquired in addition to the lateral, medial,



and inferior scans for capturing the clinically relevant tissues. Advantageously, a set of generally standard and comparable ultrasound image volumes is acquired according to the size of the breast for facilitating year-over-year comparisons, comparisons of similarly-sized breasts, and/or a variety of other useful purposes.

[0103] Automated navigation between a first ultrasonic volume of a breast acquired during a first volumetric scan thereof and a second ultrasonic volume of the same breast taken during a second volumetric scan thereof is now described. FIG. 33 illustrates one example of the overall goal of the method, showing a first coronal thick-slice image 3302 derived from a first ultrasound volume that may have been acquired according to FIG. 28, that is, a direct head-on scan. A second coronal thick-slice image 3304 is derived from a second ultrasound volume that may have been acquired according to FIG. 32, that is, a superior frontal scan. Alternatively, one or both of these images may be a planar ultrasound slice, the method proceeding in substantially the same way for planar slices as for thick-slice images. Generally speaking, the ultrasound display will segregate the images corresponding to the first and second ultrasonic volumes such that the viewer is aware of the distinction between the two. The user has selected a source region of interest (ROI) in the first image 3302, and according to a preferred embodiment, automatic navigation is provided by computing a corresponding location (termed a destination ROI) in the second thick-slice image and highlighting that location, allowing the user to quickly take a “different look” at the region of interest. The automated navigation is preferably nipple-centric, i.e., the mapping between volumes is based on a position of the source ROI relative to the nipple in the first ultrasonic volume, with the destination ROI being identified as that location in the second subvolume having the same relationship with the nipple location as it appears in the second subvolume. More particularly, the relative positions are based on distance and direction from the nipple when the ROI is projected onto a coronally oriented plane going through the nipple location. The described method has been found to yield sufficiently accurate results without requiring intensive internal feature-based volume mappings, while also being flexible for the large variety of different scan orientations that might be used.

[0104] Nipple locations 3308 and 3310 in the first and second ultrasonic volumes are identified either automatically or manually according to any of the above-described methods. Notably, the nipple is positioned directly in the middle for the head-on scan thick-slice image 3302 while it is skewed toward the bottom for the superior frontal scan thick-slice image 3304. When the ROI 3306 is selected (termed a source ROI herein), it is mapped from the thick-slice image 3302 into the corresponding first ultrasonic volume, according to the known position of the associated slab-like subvolume within the first ultrasonic volume. The source ROI is then mapped from within the first ultrasonic volume into a corresponding destination ROI within the second ultrasonic volume of the breast. The destination ROI is then mapped onto the second image 3304 according to the known position of the second thick-slice image within the second ultrasonic volume. The second image is displayed to the viewer with the position of the destination ROI therein being highlighted (see FIG. 37).

[0105] With reference herein to FIGS. 34-38, in one preferred embodiment, the mapping from the source ROI 3306 within the first ultrasonic volume 3402 into the corresponding destination ROI 3604 (see FIG. 36) within the second ultrasonic volume 3602 first comprises identifying a nipple location 3308 and 3310 of the breast in each of the first and second ultrasonic volumes 3306 and 3604. A projected location of the source ROI 3306 onto a first coronal reference plane 3404 passing through the nipple location within the first ultrasonic volume is then identified (see FIG. 34). A Cartesian offset (by Cartesian, it is meant that the offset is within a plane and can be identified by two coordinates such as  $\Delta x$ ,  $\Delta y$  or, in this case, a radius  $r$  and angle  $\alpha$ ; the term “in-plane offset” may alternatively be used) between the projected source ROI location and the nipple location on the first coronal reference plane 3404 is then determined.

[0106] With reference to FIG. 35, that Cartesian offset ( $r, \alpha$ ) is then transferred to a second coronal reference plane 3502 to identify a transferred offset point 3504 thereon, the second coronal reference plane 3502 passing through the nipple location within the second ultrasonic volume 3602. The transferred offset point 3504 is then backprojected (see FIG. 36) from the second coronal reference plane 3502 into the second ultrasonic volume 3604. The distance “ $d$ ” in the chestward direction from the nipple is known (see FIG. 34) by virtue of the known thick-slice that was clicked upon, and applied in the backprojection in FIG. 36.

[0107] In another preferred embodiment, with reference to FIG. 38, accommodations are made for compression of the breast along an anti-coronal plane (i.e., along a plane perpendicular to the coronal plane, which would include CC, MLO, and LAT, for example) during one or both of the volumetric scans. In particular, where the breast was so compressed during the first scan or the second scan (but not both), the transferred point 3804 on the second coronal reference plane 3802 is modified according to an elastic mapping (38024→3806) between a coronal projection 3802 of the anti-coronally-compressed breast onto a coronal projection 3806 of the non-anti-coronally-compressed breast. The “clock position” of the transferred point changes due to an expansion of the breast along the vertical direction in FIG. 38 to a different clock position 3808. The elastic mapping is determined at least in part according to a measured compression force and a distance between compression plates during breast compression along the anti-coronal plane. In one preferred embodiment, the breast can be modeled as a three-dimensional object having known compressibility, and so the compressed outline (as projected onto the coronal plane) can be re-expanded outward where the compression force and the plate distance are known.

[0108] If the breast was so compressed for both volumetric scans, the breast being compressed along a first anti-coronal plane during the first volumetric scan thereof and compressed along a second anti-coronal plane during the second volumetric scan thereof, the transferred point on the second coronal reference plane is modified according to an elastic mapping between a coronal projection of the breast as compressed along the first anti-coronal plane and a coronal projection of the breast as compressed along the second anti-coronal plane.

[0109] Whereas many alterations and modifications of the present invention will no doubt become apparent to a person

of ordinary skill in the art after having read the foregoing description, it is to be understood that the particular embodiments shown and described by way of illustration are in no way intended to be considered limiting. By way of example, there can be many different ways of displaying the first ultrasound volume (and, when selected, the source ROI thereon) and the second ultrasound volume (including the destination ROI thereon) without departing from the scope of the preferred embodiments. For example, two side-by-side display monitors can be provided that are each similar to FIG. 18, supra, the first monitor showing the breast as scanned in Year N, and the second monitor showing the breast as scanned from Year N+1. The user can select a particular location of interest in the Year N breast volume on the first monitor, and then invoke a "map" command or similar input. Responsive thereto, the second display would automatically navigate to the appropriate thick-slice and planar images that intersect that selected location in the Year N+1 breast volume. Alternatively, instead of showing Year N and Year N+1 volumes simultaneously on two different monitors, a single monitor can be used to alternate between displaying Year N and Year N+1. Thus, while Year N is being displayed, the user would select a location of interest in the Year N breast volume and then invoke the "map" command or similar input. Responsive thereto, the display would automatically replace the Year N volume with the Year N+1 volume, with the corresponding location in the Year N+1 volume being automatically navigated to and highlighted. When viewing for temporal comparison, this alternative method provides a sort of "time travel" on the user display, because the user is staying in the same location but is being thrust forward or backward in time. When viewing for alternative views taken on the same date (e.g., navigating between a lateral frontal scan and a medial frontal scan of a breast taken during the same session), this alternative method provides a sort of "hyperspace" on the user display, because the user is staying at the same general point in time but is being instantly transported to different views of the ROI. In one illustration, when a suspicious location is occluded (e.g., by shadowing) in the lateral frontal scan, the user can use the above-described methods to instantly view the medial frontal scan at that suspicious location for a clearer view. Therefore, reference to the details of the preferred embodiments are not intended to limit their scope, which is limited only by the scope of the claims set forth below.

What is claimed is:

1. A computer-implemented method for facilitating review of data associated with different volumetric ultrasonic scans of a same breast, the breast having been compressed in a generally chestward direction by a compressive surface for each of the different volumetric ultrasonic scans, the compressive surface encompassing a nipple of the breast, comprising:

receiving, at one or more computer processing units, first and second data volumes derived respectively from the different volumetric ultrasound scans;

displaying a first image representative of values at a first plurality of known locations within said first data volume;

receiving, at the one or more computer processing units, a selection of a first location within the first data volume relative to said first displayed image;

operating the one or more processing units to identify a second location within the second data volume having a similar spatial disposition relative to the nipple and the compressive surface as said first location within said first volume, whereby said second location at least roughly corresponds to a same locality of tissue within the breast as said first location; and

displaying a second image representative of values at a second plurality of known locations within said second data volume including said second location, said second image comprising a visible mark denoting said second location thereon.

2. The computer-implemented method of claim 1, further comprising receiving a manual identification of a nipple location in each of said first and second data volumes.

3. The computer-implemented method of claim 1, wherein said first images comprises one of a planar image and a thick-slice image derived from the first data volume.

4. The computer-implemented method of claim 1, wherein said different volumetric ultrasound scans of the breast were acquired contemporaneously and comprise different ones of the group consisting of: lateral frontal view, medial frontal view, inferior frontal view, and superior frontal view.

5. The computer-implemented method of claim 1, wherein said operating the one or more processing units to identify the second location comprises determining a Cartesian offset of said first location relative to the nipple in a coronal reference plane and identifying said second location in the second data volume to have a similar Cartesian offset relative to the nipple in the coronal reference plane.

6. The computer-implemented method of claim 5, wherein said operating the one or more processing units to identify the second location comprises determining a depth of said first location relative to the compressive surface in the first data volume and identifying said second location in the second data volume to have a similar depth relative to the compressive surface.

7. The computer-implemented method of claim 1, wherein said different volumetric ultrasound scans of the breast comprise identical views acquired at substantially different times.

8. A computer-implemented method for facilitating review of data associated with different volumetric ultrasonic scans of a same breast, comprising:

receiving, at one or more computer processing units, first and second data volumes derived respectively from the different volumetric ultrasound scans;

displaying on a display device a first image representative of values at a first plurality of known locations within said first data volume;

receiving, at the one or more computer processing units, a selection of a first location within the first data volume relative to said first displayed image;

operating the one or more processing units to identify a second location within the second data volume at least roughly corresponding to a same locality of tissue within the breast as said first location; and

replacing said first image on said display device with a second image representative of values at a second plurality of known locations within said second data

volume including said second location, said second image comprising a visible mark denoting said second location thereon.

9. The computer-implemented method of claim 8, the breast having been compressed in a generally chestward direction by a compressive surface for each of the different volumetric ultrasonic scans, the compressive surface encompassing a nipple of the breast, wherein said second location within the second data volume is identified as that which has a similar spatial disposition relative to the nipple and the compressive surface as said first location within said first volume.

10. The computer-implemented method of claim 9, wherein said operating the one or more processing units to identify the second location comprises determining a Cartesian offset of said first location relative to the nipple in a coronal reference plane and identifying said second location in the second data volume to have a similar Cartesian offset relative to the nipple in the coronal reference plane.

11. The computer-implemented method of claim 10, wherein said operating the one or more processing units to identify the second location comprises determining a depth of said first location relative to the compressive surface in the first data volume and identifying said second location in the second data volume to have a similar depth relative to the compressive surface.

12. The computer-implemented method of claim 8, further comprising receiving a manual identification of a nipple location in each of said first and second data volumes.

13. The computer-implemented method of claim 8, wherein said first images comprises one of a planar image and a thick-slice image derived from the first data volume.

14. The computer-implemented method of claim 8, wherein said different volumetric ultrasound scans of the breast were acquired contemporaneously and comprise different ones of the group consisting of: lateral frontal view, medial frontal view, inferior frontal view, and superior frontal view.

15. A method for automated navigation of breast ultrasound information, comprising:

displaying a first image derived from a first ultrasonic volume of a breast acquired during a first volumetric scan thereof, said first image comprising one of (i) a thick-slice image representing said first ultrasonic volume within a slab-like subvolume thereof, and (ii) a planar image representing said first ultrasonic volume along a plane therethrough;

receiving a user selection of a source region of interest (ROI) in said first image;

mapping said source ROI from said first image into said first ultrasonic volume according to a known position of the slab-like subvolume or plane associated with the first image within the first ultrasonic volume;

mapping said source ROI within said first ultrasonic volume into a corresponding destination ROI within a second ultrasonic volume of the breast acquired during a second volumetric scan thereof taken at a different position or orientation relative to said first volumetric scan;

mapping said destination ROI within said second ultrasonic volume onto a second image, said second image

comprising one of (i) a thick-slice image representing said second ultrasonic volume within a slab-like subvolume thereof, and (ii) a planar image representing said second ultrasonic volume along a plane therethrough, said mapping being in accordance with a known position of said slab-like subvolume or plane within the second ultrasonic volume;

displaying said second image to the viewer; and

highlighting said destination ROI on said second image.

16. The method of claim 15, said mapping said source ROI within said first ultrasonic volume into the corresponding destination ROI within the second ultrasonic volume comprising:

identifying a nipple location of the breast in each of said first and second ultrasonic volumes thereof;

identifying a projected location of the source ROI onto a first coronal reference plane passing through the nipple location within the first ultrasonic volume;

determining a Cartesian offset between said projected source ROI location and said nipple location on said first coronal reference plane;

transferring said Cartesian offset to a second coronal reference plane to identify a transferred offset point thereon, said second coronal reference plane passing through the nipple location within the second ultrasonic volume; and

backprojecting said transferred offset point from said second coronal reference plane into said second ultrasonic volume.

17. The method of claim 16, wherein said breast is compressed along an anti-coronal plane during one of said first or second volumetric scans thereof and not compressed along an anti-coronal plane during the other volumetric scan thereof, further comprising modifying said transferred point on said second coronal reference plane according to an elastic mapping between a coronal projection of the anti-coronally-compressed breast onto a coronal projection of the non-anti-coronally-compressed breast.

18. The method of claim 17, wherein said elastic mapping is determined at least in part according to a measured compression force along the anti-coronal plane and a distance between compression plates during breast compression.

19. The method of claim 17, wherein said breast is compressed along a first anti-coronal plane during said first volumetric scan thereof and compressed along a second anti-coronal plane during said second volumetric scan thereof, further comprising modifying said transferred point on said second coronal reference plane according to an elastic mapping between a coronal projection of the breast as compressed along the first anti-coronal plane and a coronal projection of the breast as compressed along the second anti-coronal plane.

20. The method of claim 19, wherein said elastic mapping is determined at least in part according to a measured compression force along the anti-coronal plane and a distance between compression plates during breast compression.

专利名称(译)	在多个乳房超声波体积中导航		
公开(公告)号	<a href="#">US20070038085A1</a>	公开(公告)日	2007-02-15
申请号	US11/439093	申请日	2006-05-23
[标]申请(专利权)人(译)	张伟 陈家瑜 NEFF THOMAS P REED迈克尔· RADER珍妮中号		
申请(专利权)人(译)	张伟 陈嘉鱼县 NEFF THOMAS P REED迈克尔· RADER珍妮中号		
当前申请(专利权)人(译)	U-SYSTEMS INC.		
[标]发明人	ZHANG WEI CHEN JIAYU NEFF THOMAS P REED MICHAEL E RADER JEANINE M		
发明人	ZHANG, WEI CHEN, JIAYU NEFF, THOMAS P. REED, MICHAEL E. RADER, JEANINE M.		
IPC分类号	A61B8/00		
CPC分类号	A61B6/463 A61B8/483 A61B6/5247 A61B6/563 A61B8/0825 A61B8/13 A61B8/406 A61B8/4281 A61B8/4405 A61B8/462 A61B8/463 A61B8/467 A61B8/469 A61B8/5238 A61B8/565 A61B6/502 A61B8/465 A61B8/466		
优先权	60/684622 2005-05-24 US		
其他公开文献	US7727151		
外部链接	<a href="#">Espacenet</a> <a href="#">USPTO</a>		

#### 摘要(译)

描述了从同一乳房的不同体积超声扫描得到的乳房超声体积中的导航。在乳房超声工作站的显示器上，显示从第一超声体积导出的第一图像。接收用户对第一图像中的源感兴趣区域 ( ROI ) 的选择。识别第二超声体积内的目的地ROI，其至少粗略地对应于乳房中与组织ROI相同的组织局部性。显示从第二超声波体积导出并包括目的地ROI的第二图像，目的地ROI被突出显示。

