



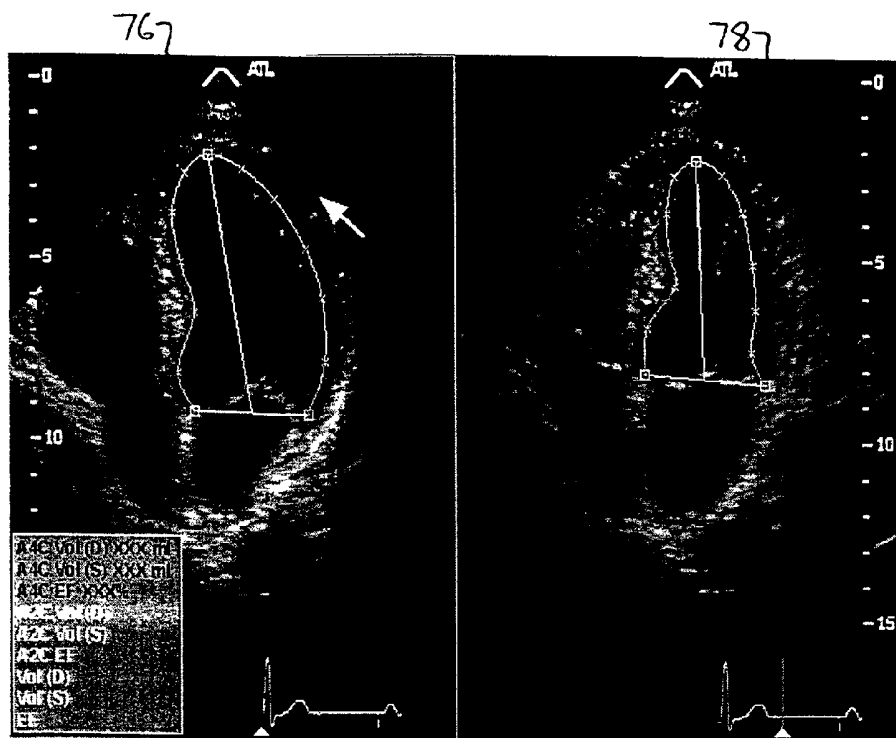
US 20020072672A1

(19) **United States**(12) **Patent Application Publication**  
**Roundhill et al.**(10) **Pub. No.: US 2002/0072672 A1**(43) **Pub. Date: Jun. 13, 2002**(54) **ANALYSIS OF CARDIAC PERFORMANCE  
USING ULTRASONIC DIAGNOSTIC IMAGES**(76) **Inventors:** **David N. Roundhill**, Woodinville, WA  
(US); **Cedric Chenal**, Kirkland, WA  
(US); **Aline Laure Criton**, Seattle, WA  
(US)

Correspondence Address:

**ATL ULTRASOUND****P.O. BOX 3003****22100 BOTHELL EVERETT HIGHWAY**  
**BOTHELL, WA 98041-3003 (US)**(21) **Appl. No.: 09/732,614**(22) **Filed: Dec. 7, 2000****Publication Classification**(51) **Int. Cl.<sup>7</sup>** ..... **A61B 8/02; A61B 8/12**(52) **U.S. Cl.** ..... **600/450; 600/454**(57) **ABSTRACT**

Ultrasonic cardiac image information is acquired and segmented by automatic border detection. The segmented ultrasonic information is used to display regional wall motion over time. The segmented information may be presented in a color-coded representation, or entered automatically as qualitative or quantitative measures on a scorecard of cardiac performance. The inventive technique is applicable to both two dimensional and three dimensional ultrasonic image information.



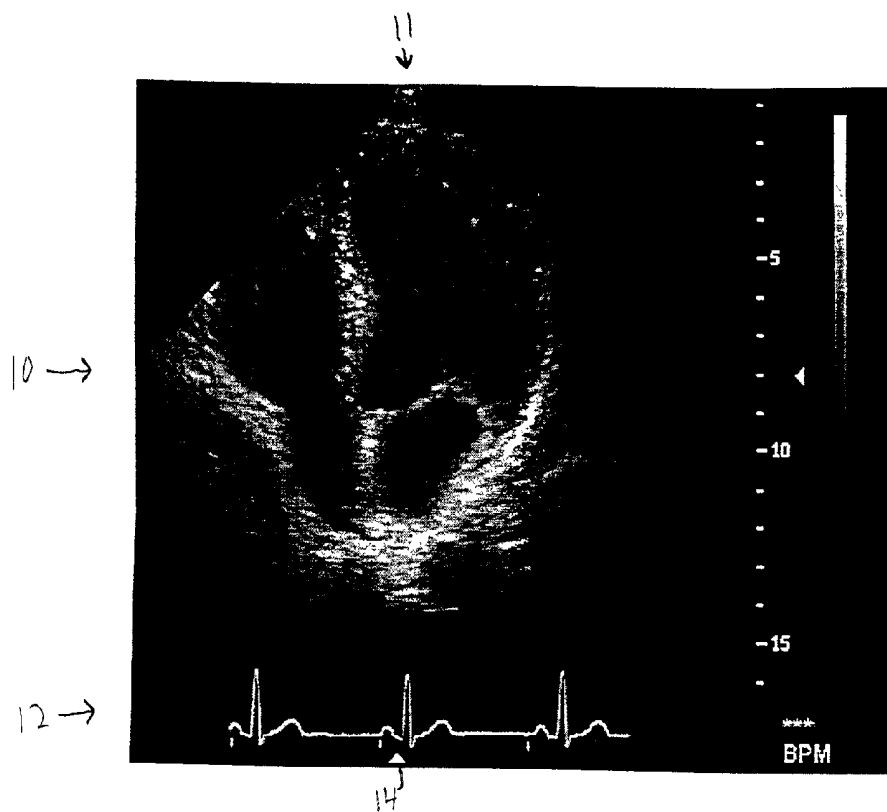


Fig. 1

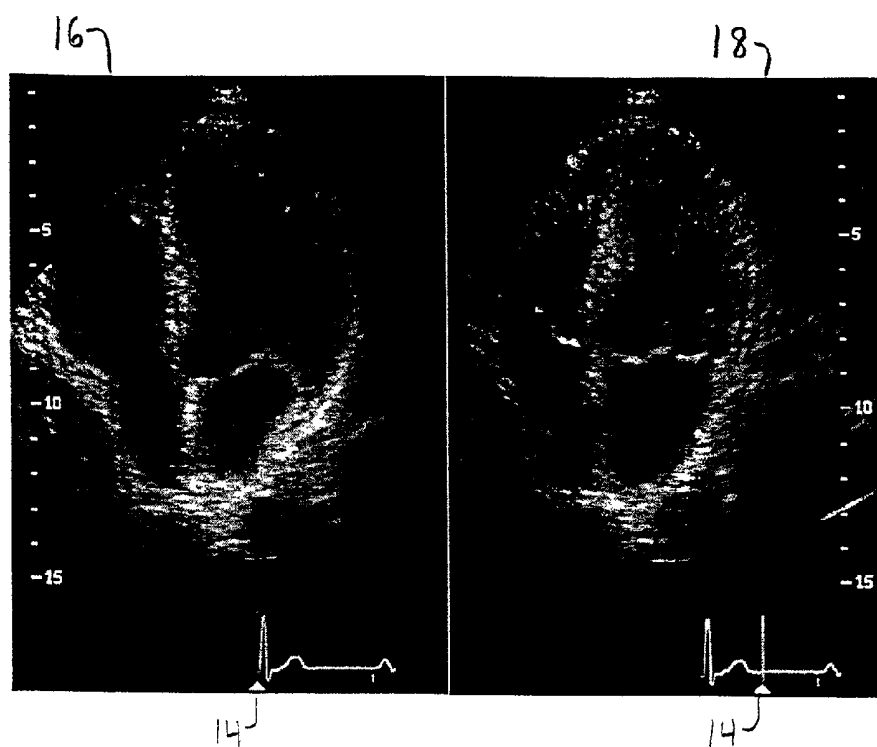


Fig. 2



Fig. 3b

Fig. 3a




Fig. 4

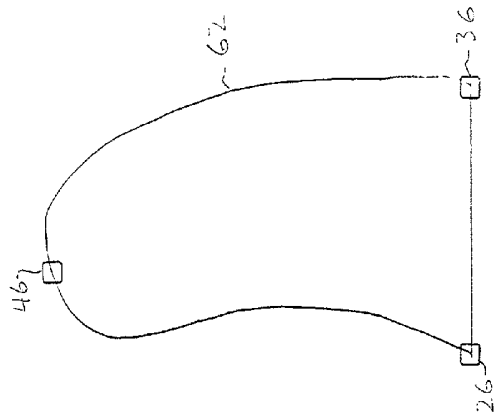


Fig. 5a

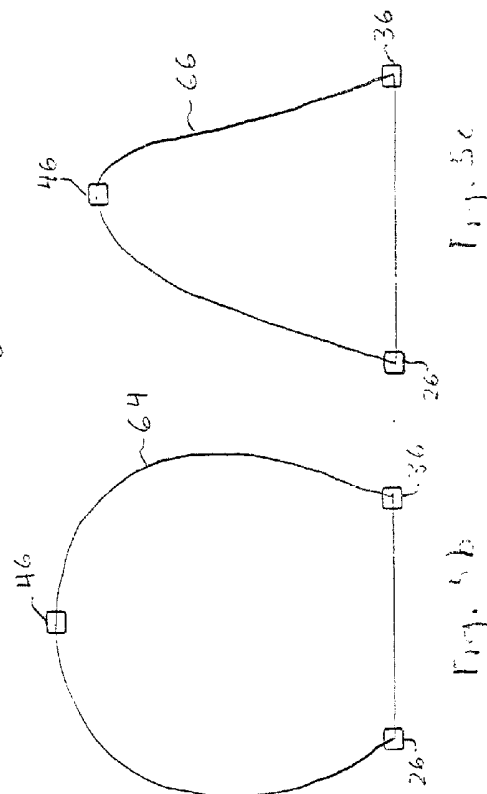


Fig. 5b

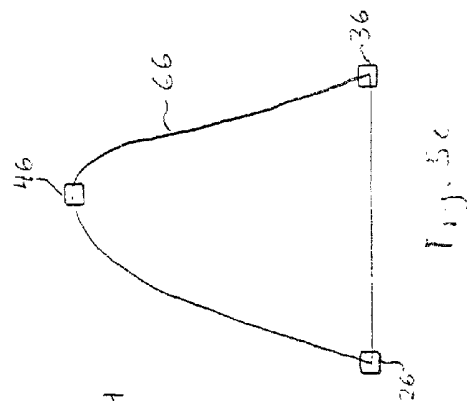


Fig. 5c




Fig. 6a

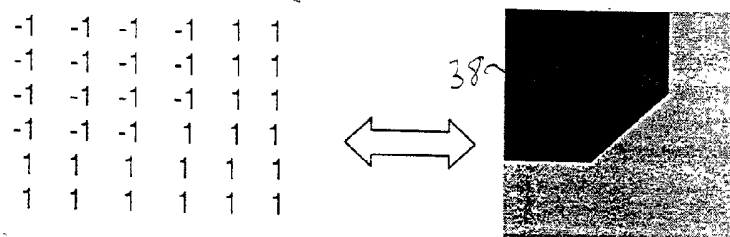


Fig. 6b

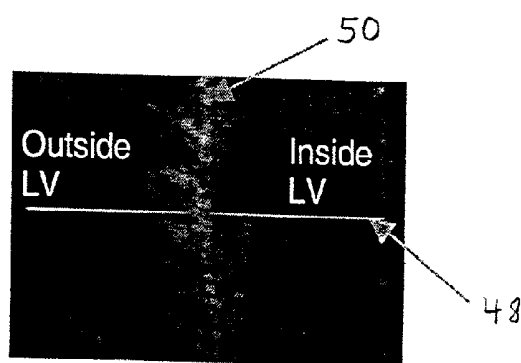


Fig. 7a

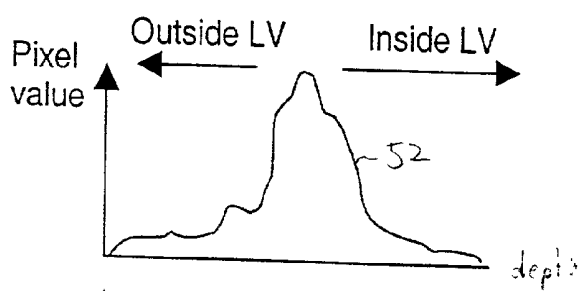


Fig. 7b

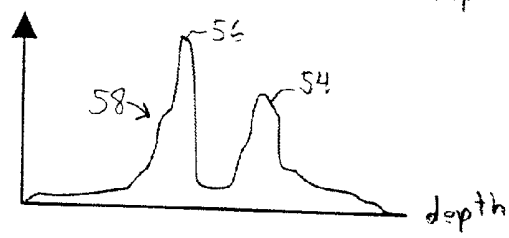


Fig. 7c

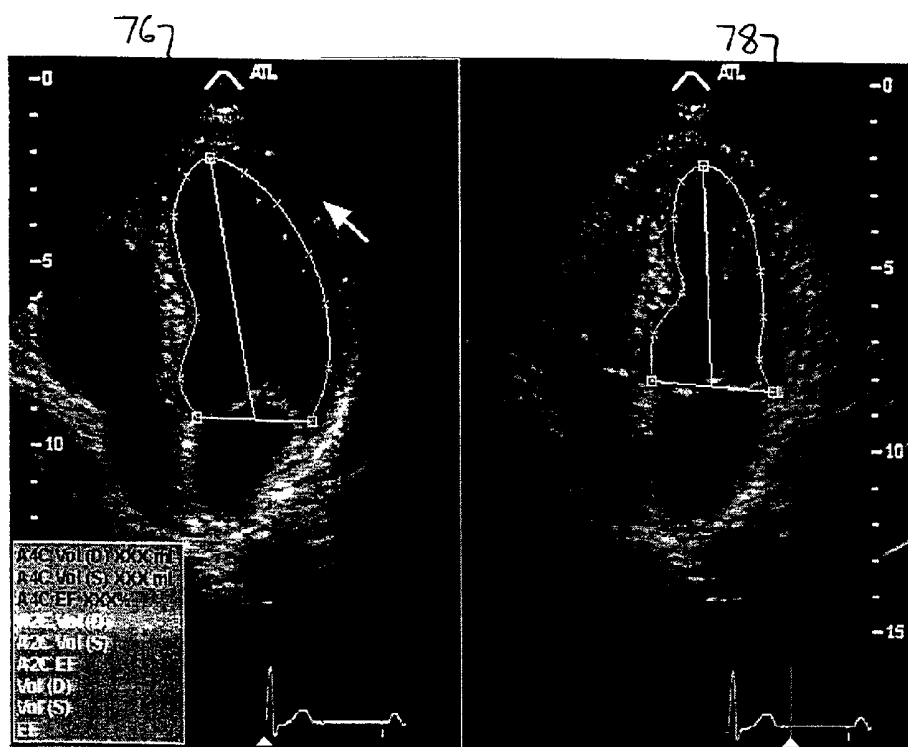


Fig. 8

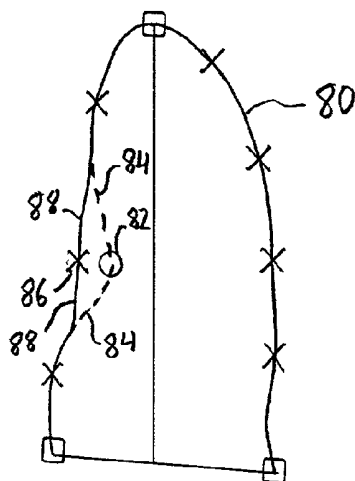


Fig. 9

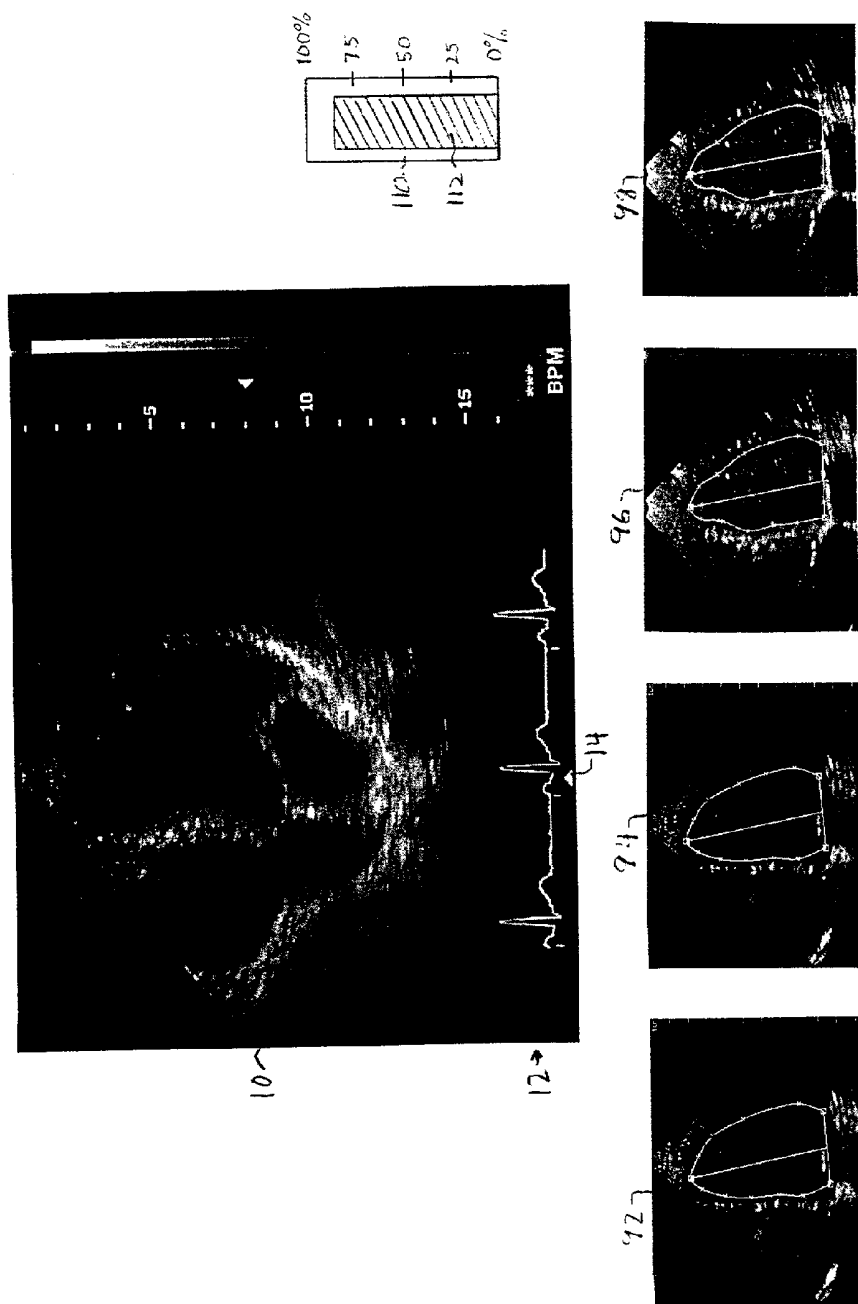


Fig. 10

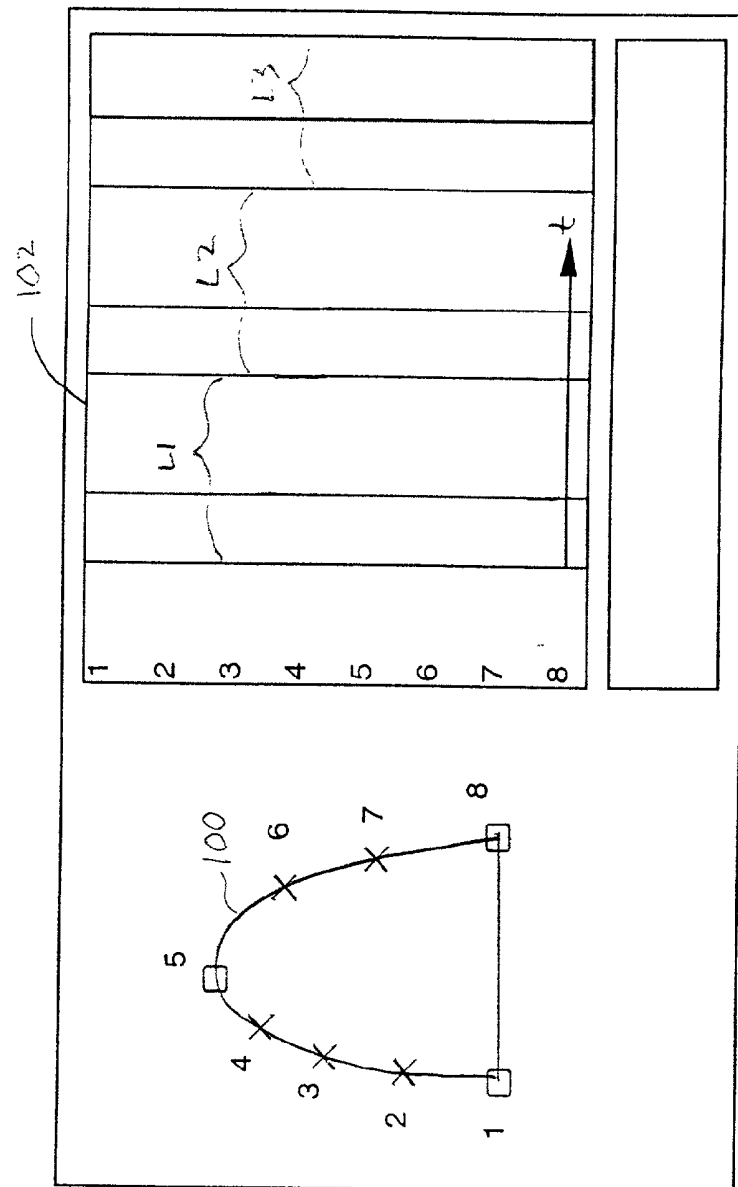


Fig. 11



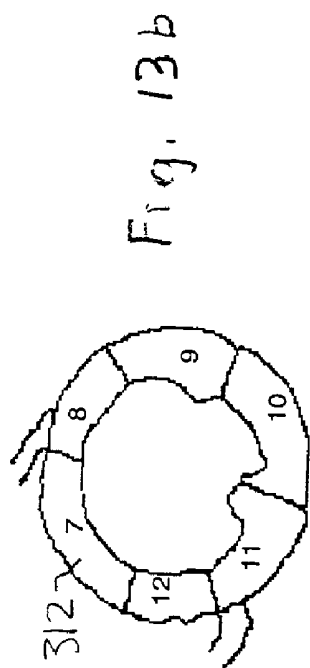


Fig. 13b

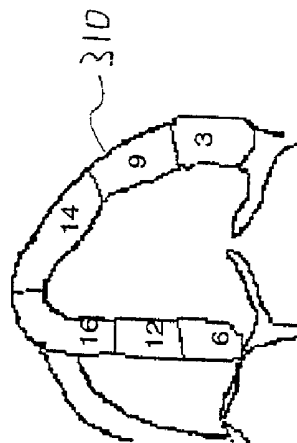


Fig. 13a

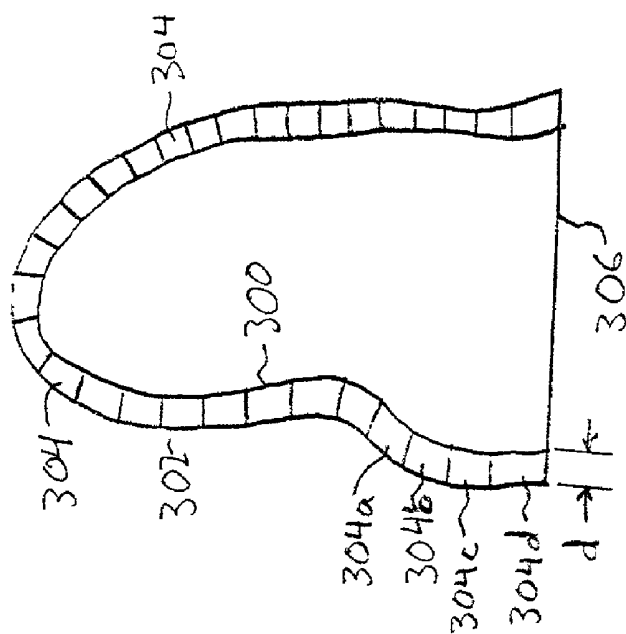


Fig. 12

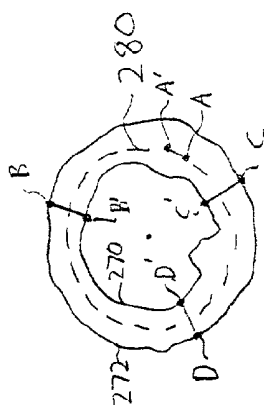


Fig. 14b

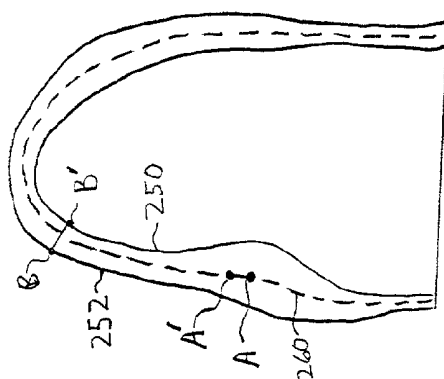


Fig. 14a

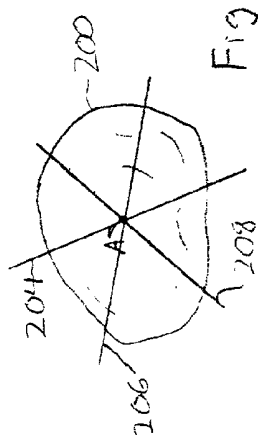


Fig. 15c

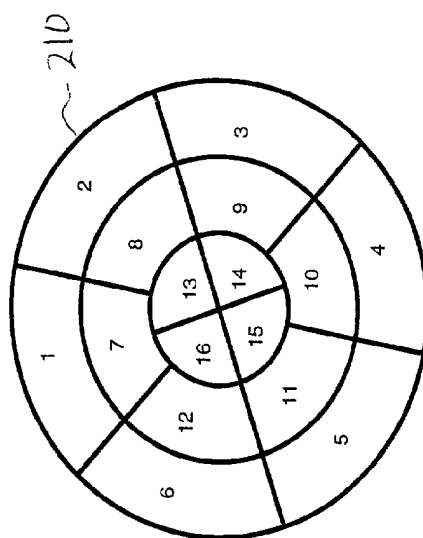
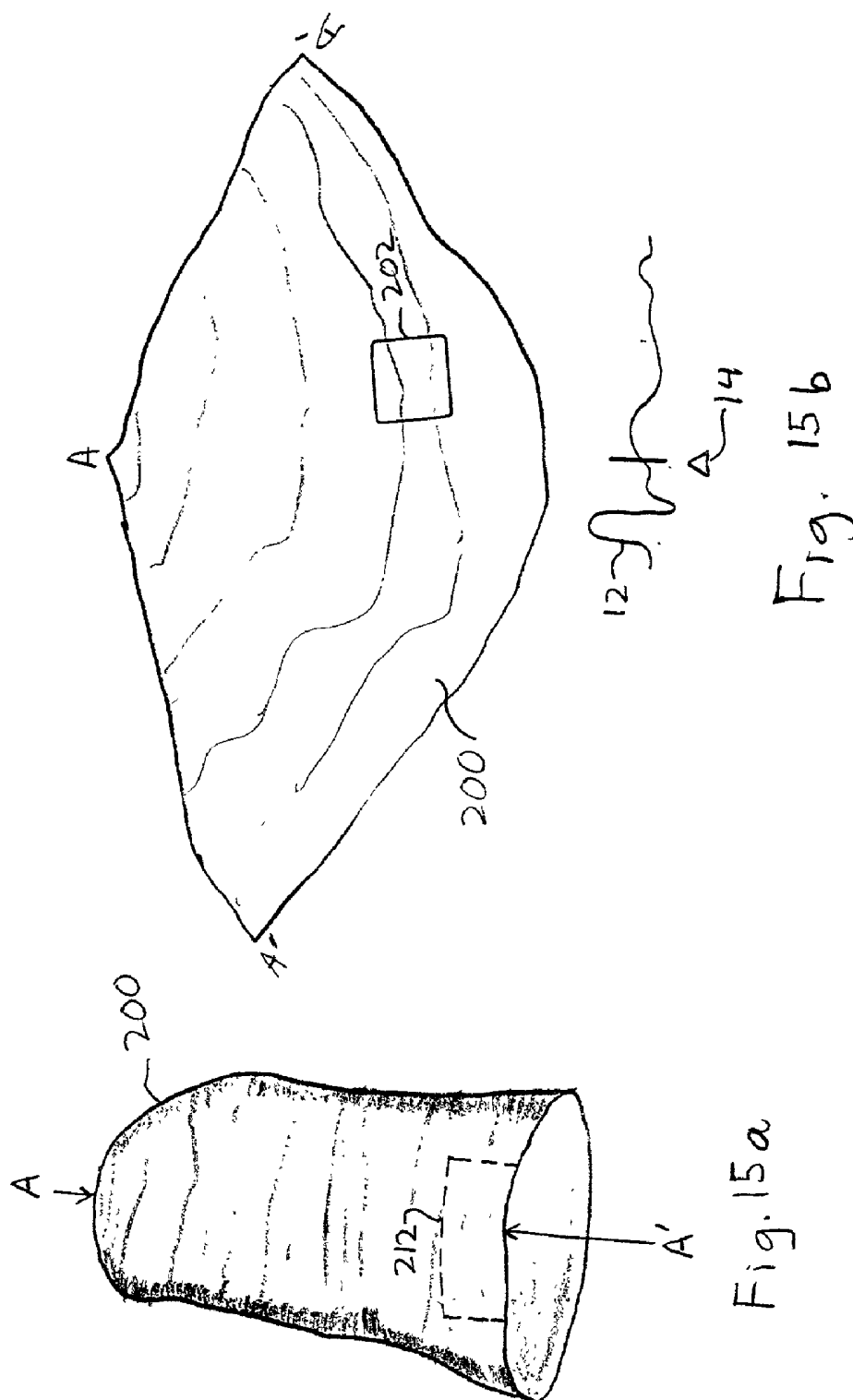


Fig. 15d



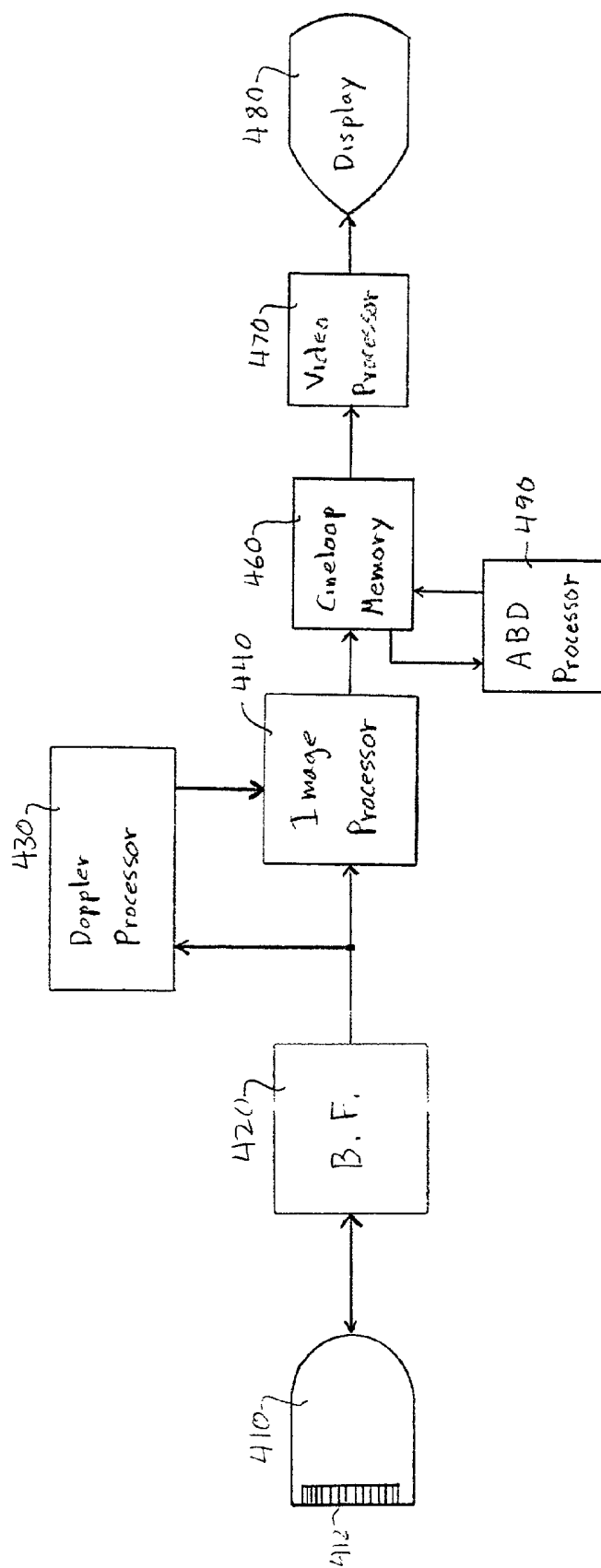


Fig. 16

## ANALYSIS OF CARDIAC PERFORMANCE USING ULTRASONIC DIAGNOSTIC IMAGES

[0001] This invention relates to ultrasonic diagnostic imaging systems and, in particular, to ultrasonic diagnostic imaging systems which automatically assist in the assessment of cardiac performance and deficiencies.

[0002] Many ultrasonic diagnostic procedures in which bodily functions and structures are quantified rely upon clear delineation and definition of the body structures and organs which are being measured. When the quantification or measurement procedure uses static images or a small set of measurements, the delineation of the bodily structure being measured can be done manually. An example of such a procedure is the obstetrical measurements of a developing fetus. Static images of the developing fetus can be acquired during periods when fetal activity is low. Once an image is acquired, only a few circumference or length measurements are usually required to compute development characteristics such as gestational age and anticipated delivery date. These measurements can readily be made manually on the fetal images. Other diagnostic procedures, particularly those involving measurements of the heart and its functioning, present a further set of difficulties. The heart is always beating and hence is always in motion. As it moves, the contours of the heart constantly move and change as the organ contracts and expands. To fully assess many characteristics of cardiac function it is necessary to evaluate many and at times all of the images acquired during the heart cycle (one heartbeat), which can amount to thirty to one hundred and fifty or more images. The structure of interest such as the endocardium, epicardium or valves must then be delineated in each of these images, a painstaking, time-consuming task. Since these structures are constantly in motion, they appear slightly different in each image acquired during the cardiac cycle, and can also vary significantly from one patient to another. While applications such as obstetrical procedures would benefit from a processor which automatically delineates specific anatomy in an ultrasonic image, cardiac diagnosis would benefit even more so.

[0003] Once anatomy can automatically be delineated in cardiac images, it then becomes desirable how to make the best diagnostic use of the delineated image information. It is desirable, for instance, to convey a sense of regional wall motion but in a format which enables the user to specifically diagnose particular locations of the heart wall and to be able to do so over the full cardiac cycle. Furthermore, it is desirable to give the user a visual, automated assessment of regional cardiac performance, enabling the user to quickly pinpoint and thereafter examine potentially deficient regions of the heart.

[0004] In accordance with the principles of the present invention, ultrasonic cardiac image information is acquired and segmented by automatic border detection. The segmented ultrasonic information is used to display regional wall motion over time. The segmented information may be presented in a color-coded representation, or entered automatically as qualitative or quantitative measures on a scorecard of cardiac performance. The inventive technique is applicable to both two dimensional and three dimensional ultrasonic image information.

[0005] In the drawings:

[0006] **FIG. 1** is a four chamber ultrasound image of the heart;

[0007] **FIG. 2** illustrates an ultrasound display of both end diastole and end systole cardiac images;

[0008] **FIGS. 3a** and **3b** illustrate the step of locating the medial mitral annulus (MMA) and the lateral mitral annulus (LMA) in an ultrasound image of the left ventricle (LV);

[0009] **FIG. 4** illustrates the step of locating the apex of the LV;

[0010] **FIGS. 5a-5c** illustrate standard border shapes for the LV;

[0011] **FIGS. 6a-6b** illustrate geometric templates used to locate the MMA and LMA;

[0012] **FIGS. 7a-7c** illustrate a technique for fitting a standard border shape to the endocardial boundary of the LV;

[0013] **FIG. 8** illustrates an end diastole and end systole display with endocardial borders drawn automatically in accordance with the principles of the present invention;

[0014] **FIG. 9** illustrates the rubber-banding technique for adjusting an automatically drawn border;

[0015] **FIG. 10** illustrates the selection of a cardiac cycle by viewing automatically drawn borders;

[0016] **FIG. 11** illustrates a tissue Doppler map of endocardial motion over a plurality of cardiac cycles;

[0017] **FIGS. 12** illustrates the use of automated border detection to segment an image of the heart wall;

[0018] **FIGS. 13a** and **13b** illustrate scorecards for scoring segments of the heart wall;

[0019] **FIGS. 14a** and **14b** illustrate techniques for making strain rate measurements as a function of tissue motion;

[0020] **FIGS. 15a-15c** illustrate 3D techniques for evaluating cardiac performance;

[0021] **FIG. 15d** illustrates a scorecard for scoring a three dimensional image of the heart; and

[0022] **FIG. 16** illustrates in block diagram form an ultrasonic diagnostic imaging system constructed in accordance with the principles of the present invention.

[0023] Referring first to **FIG. 1**, an ultrasound system display is shown during the acquisition of cardiac images. The ultrasound image **10** is a four-chamber view of the heart which is acquired by a phased array transducer probe to produce the illustrated sector-shaped image. The image shown is one of a sequence of real-time images acquired by placement of the probe for an apical 4-chamber view of the heart, in which the probe is oriented to view the heart from the proximity of its apex **11**. The largest chamber in the image, in the central and upper right portion of the image, is the left ventricle (LV). As the real-time ultrasound image sequence is acquired an ECG trace **12** of the heart cycle is simultaneously acquired and displayed at the bottom of the display, with a triangular marker **14** denoting the point or phase of the cardiac cycle at which the currently-displayed image was acquired. A typical duration of the heart cycle

when the body is at rest is about one second, during which time approximately 30-90 image frames of the heart are acquired and displayed in rapid succession. A sequence of image frames for a heart cycle is referred to herein as a "loop" of images, as a clinician will often acquire and save the sequence of images of a heart cycle and then replay them in a continuous "loop" which repetitively displays the selected cardiac cycle. As the clinician views the display of **FIG. 1**, the heart is seen beating in real time in the ultrasound display as the ECG waveform **12** scrolls beneath the ultrasound images **10**, with the instantaneously displayed heart phase indicated by the marker **14**.

[0024] In one mode of acquisition in accordance with the present invention, the clinician observes the beating heart in real time while manipulating the transducer probe so that the LV is being viewed distinctly in maximal cross-section. When the four chamber view is being acquired continuously and clearly, the clinician depresses the "freeze" button to retain the images of the current heart cycle in the image frame or Cineloop® memory of the ultrasound system. The Cineloop memory will retain all of the images in the memory at the time the freeze button is depressed which, depending upon the size of the memory, may include the loop being viewed at the time the button was depressed as well as images of a previous or subsequent loop. A typical Cineloop memory may hold 400 image frames, or images from about eight to ten heart cycles. The clinician can then scan through the stored images with a trackball, arrow key, or similar control to select the loop with the images best suited for analysis. When the clinician settles on a particular loop, the "ABD" protocol is actuated to start the border drawing process.

[0025] When the ABD protocol is actuated the display changes to a dual display of the end diastole image **16** and the end systole image **18** displayed side-by-side as shown in **FIG. 2**. The ultrasound system identifies all of the images comprising the selected loop by the duration of the ECG waveform associated with the selected loop. The ultrasound system also recognizes the end diastole and end systole points of the cardiac cycle in relation to the R-wave of the ECG waveform **12** and thus uses the ECG waveform R-wave to identify and display the ultrasound images at these two phases of the heart cycle. The dual display of **FIG. 2** shows the ECG waveform **12** for the selected heart cycle beneath each ultrasound image, with the marker **14** indicating the end diastole and end systole phases at which the two displayed images were acquired.

[0026] Since the Cineloop memory retains all of the images of the cardiac cycle, the user has the option to review all of the images in the loop, including those preceding and succeeding those shown in the dual display. For instance, the clinician can "click" on either of the images to select it, then can manipulate the trackball or other control to sequentially review the images which precede or succeed the one selected by the ultrasound system. Thus, the clinician can select an earlier or later end diastole or end systole image from those selected by the ultrasound system. When the clinician is satisfied with the displayed images **16** and **18**, the ABD processor is actuated to automatically delineate the LV borders on the two displayed images as well as the intervening undisplayed images between end diastole and end systole.

[0027] In this example the ABD processor begins by drawing the endocardial border of the LV in the end systole image **18**. The first step in drawing the border of the LV is to locate three key landmarks in the image, the medial mitral annulus (MMA), the lateral mitral annulus (LMA), and the endocardial apex. This process begins by defining a search area for the MMA as shown in **FIG. 3a**, in which the ultrasound image grayscale is reversed from white to black for ease of illustration. Since the ABD processor is preconditioned in this example to analyze four-chamber views of the heart with the transducer **20** viewing the heart from its apex, the processor expects the brightest vertical nearfield structure in the center of the image to be the septum which separates the left and right ventricles. This means that the column of pixels in the image with the greatest total brightness value should define the septum. With these cues the ABD processor locates the septum **22**, and then defines an area in which the MMA should be identified. This area is defined from empirical knowledge of the approximate depth of the mitral valve from the transducer in an apical view of the heart. A search area such as that enclosed by the box **24** in **FIG. 3a** is defined in this manner.

[0028] A filter template defining the anticipated shape of the MMA is then cross correlated to the pixels in the MMA search area. While this template may be created from expert knowledge of the appearance of the MMA in other four-chamber images as used by Wilson et al. in their paper "Automated analysis of echocardiographic apical 4-chamber images," Proc. of SPIE, August, 2000, the present inventors prefer to use a geometric corner template. While a right-angle corner template may be employed, in a constructed embodiment the present inventors use an octagon corner template **28** (the lower left corner of an octagon) as their search template for the MMA, as shown at the right side of **FIG. 6a**. In practice, the octagon template is represented by the binary matrix shown at the left side of **FIG. 6a**. The ABD processor performs template matching by cross correlating different sizes of this template with the pixel data in different translations and rotations until a maximum correlation coefficient above a predetermined threshold is found. To speed up the correlation process, the template matching may initially be performed on a reduced resolution form of the image, which highlights major structures and may be produced by decimating the original image resolution. When an initial match of the template is found, the resolution may be progressively restored to its original quality and the location of the MMA progressively refined by template matching at each resolution level.

[0029] Once the MMA has been located a similar search is made for the location of the LMA, as shown in **FIG. 3b**. The small box **26** marks the location established for the MMA in the image **18**, and a search area to the right of the MMA is defined as indicated by the box **34**. A right corner geometric template, preferably a right octagon corner template **38** as shown in **FIG. 6b**, is matched by cross-correlation to the pixel values in the search area of box **34**. Again, the image resolution may be decimated to speed the computational process and different template sizes may be used. The maximal correlation coefficient exceeding a predetermined threshold defines the location of the LMA.

[0030] With the MMA **26** and the LMA **36** found, the next step in the process is to determine the position of the endocardial apex, which may be determined as shown in

**FIG. 4.** The pixel values of the upper half of the septum **22** are analyzed to identify the nominal angle of the upper half of the septum, as indicated by the broken line **43**. The pixel values of the lateral wall **42** of the LV are analyzed to identify the nominal angle of the upper half of the lateral wall **42**, as shown by the broken line **45**. If the lateral wall angle cannot be found with confidence, the angle of the scanlines on the right side of the sector is used. The angle between the broken lines **43**, **45** is bisected by a line **48**, and the apex is initially assumed to be located at some point on this line. With the horizontal coordinate of the apex defined by line **48**, a search is made of the slope of pixel intensity changes along the line **48** to determine the vertical coordinate of the apex. This search is made over a portion of line **48** which is at least a minimum depth and not greater than a maximum depth from the transducer probe, approximately the upper one-quarter of the length of line **48** above the mitral valve plane between the MMA **26** and the LMA **36**. Lines of pixels along the line **48** and parallel thereto are examined to find the maximum positive brightness gradient from the LV chamber (where there are substantially no specular reflectors) to the heart wall (where many reflectors are located). A preferred technique for finding this gradient is illustrated in **FIG. 7**. **FIG. 7a** shows a portion of an ultrasound image including a section of the heart wall **50** represented by the brighter pixels in the image. Drawn normal to the heart wall **50** is a line **48** which, from right to left, extends from the chamber of the LV into and through the heart wall **50**. If the pixel values along line **48** are plotted graphically, they would appear as shown by curve **52** in **FIG. 7b**, in which brighter pixels have greater pixel values. The location of the endocardium is not the peak of the curve **52**, which is in the vicinity of the center of the heart wall, but relates to the sense of the slope of the curve. The slope of the curve **52** is therefore analyzed by computing the differential of the curve **52** as shown by the curve **58** in **FIG. 7c**. This differential curve has a peak **56** which is the maximal negative slope at the outside of the heart wall (the epicardium). The peak **54**, which is the first major peak encountered when proceeding from right to left along curve **58**, is the maximal positive slope which is the approximate location of the endocardium. The pixels along and parallel to line **48** in **FIG. 4** are analyzed in this manner to find the endocardial wall and hence the location of the endocardial apex, marked by the small box **46** in **FIG. 4**.

[0031] Once these three major landmarks of the LV have been located, one of a number of predetermined standard shapes for the LV is fitted to the three landmarks and the endocardial wall. Three such standard shapes are shown in **FIGS. 5a**, **5b**, and **5c**. The first shape, border **62**, is seen to be relatively tall and curved to the left. The second shape, border **64**, is seen to be relatively short and rounded. The third shape, border **66**, is more triangular. Each of these standard shapes is scaled appropriately to fit the three landmarks **26**, **36**, **46**. After an appropriately scaled standard shape is fit to the three landmarks, an analysis is made of the degree to which the shape fits the border in the echo data. This may be done, for example, by measuring the distances between the shape and the heart wall at points along the shape. Such measurements are made along paths orthogonal to the shape and extending from points along the shape. The heart wall may be detected using the operation discussed in **FIGS. 7a-7c**, for instance. The shape which is assessed as having the closest fit to the border to be traced, by an average

of the distance measurements, for instance, is chosen as the shape used in the continuation of the protocol.

[0032] The chosen shape is then fitted to the border to be traced by "stretching" the shape, in this example, to the endocardial wall. The stretching is done by analyzing **48** lines of pixels evenly spaced around the border and approximately normal to heart wall. The pixels along each of the **48** lines are analyzed as shown in **FIGS. 7a-7c** to find the adjacent endocardial wall and the chosen shape is stretched to fit the endocardial wall. The baseline between points **26** and **36** is not fit to the shape but is left as a straight line, as this is the nominal plane of the mitral valve. When the shape has been fit to points along the heart wall, the border tracing is smoothed and displayed over the end systole image as shown in the image **78** on the right side of the dual display of **FIG. 8**. The display includes five control points shown as X's along the border between the MMA landmark and the apex, and five control points also shown as X's along the border between the apex landmark and the LMA landmark. In this example the portion of line **48** between the apex and the mitral valve plane is also shown, as adjusted by the stretching operation.

[0033] With the end systole border drawn in this manner the ABD processor now proceeds to determine the end diastole border. It does so, not by repeating this operation on the end diastole image **16**, but by finding a border on each intervening image in sequence between end systole and end diastole. In a given image sequence this may comprise **2030** image frames. Since this is the reverse of the sequence in which the images were acquired, there will only be incremental changes in the endocardial border location from one image to the next. It is therefore to be expected that there will be a relatively high correlation between successive images. Hence, the end systole border is used as the starting location to find the border for the previous image, the border thus found for the previous image is used as the starting location to find the border for the next previous image, and so forth. In a constructed embodiment this is done by saving a small portion of the end systole image around the MMA and the LMA and using this image portion as a template to correlate and match with the immediately previous image to find the MMA and the LMA locations in the immediately previous image. The apex is located as before, by bisecting the angle between the upper portions of the septum and lateral LV wall, then locating the endocardium by the maximum slope of the brightness gradient. Since the LV is expanding when proceeding from systole to diastole, confidence measures include the displacement of the landmark points in an outward direction from frame to frame. When the three landmark points are found in a frame, the appropriately scaled standard shape is fit to the three points. Another confidence measure is distortion of the standard shapes; if a drawn LV border departs too far from a standard shape, the process is aborted.

[0034] Border delineation continues in this manner until the end diastole image is processed and its endocardial border defined. The dual display then appears as shown in **FIG. 8**, with endocardial borders drawn on both the end diastole and end systole images **76**, **78**.

[0035] As **FIG. 8** shows, the endocardial borders of both the end diastole and end systole images have small boxes denoting the three major landmarks and control points

marked by X's on the septal and lateral borders. The clinician chooses the default number of control point which will be displayed initially; on the border **80** shown in **FIG. 9** there are three control points shown on the septal wall and four control points shown on the lateral wall. The clinician can review the end diastole and systole images, as well as all of the intervening images of the loop if desired, and manually adjust the positions of the landmark boxes and control point X's if it is seen that the automated process placed a border in an incorrect position. The clinician can slide a box or X along the border to a new position, and can add more control points or delete control points from the border. The process by which the clinician relocates a box or X laterally is known as rubberbanding. Suppose that the ABD processor had initially located the control point and border at the position shown by circle **82** and dashed line **84**, which the clinician observes is incorrect. The clinician can relocate the control point laterally by dragging the X with a screen pointing device to the new location as shown by **86**. As the X is dragged, the border moves or stretches along with the X, thereby defining a new border as shown by the solid line border **88**. In this manner the clinician can manually correct and adjust the borders drawn by the ABD processor. As the clinician laterally relocates a control point X, the ABD processor responds by automatically recalculating the positions of the adjoining border and adjacent control points if necessary so that the border remains smoothly continuous. The recalculation will not adjust the position of a control point or landmark box which has been previously manually repositioned by the clinician, thereby preserving this expert input into the border drawing process. If the clinician relocates a landmark box, the ABD processor recalculates and refits the entire border to the landmarks and heart wall. Since the adjustment of one border in the image sequence can affect the borders of temporally adjacent images in the sequence, the ABD processor will also respond to a manual adjustment by correlating the adjusted border with temporally adjacent borders so that the manual adjustment is properly continuously represented in some or all of the images in the loop.

[0036] Another way to interactively adjust the drawn borders is to assemble only the border tracings in a "stack" in time sequence from ED to ES or later to form a surface defined by the borders which is viewed in three dimensions such as in a kinetic parallax display. The continuous surface formed by the borders can be assessed and adjusted as desired by a rubberbanding technique known as active surface adjustment. If the clinician sees a point on the surface formed by the borders which is out of alignment with temporally adjacent tracings or the desired border, the clinician can pull or push on the surface with a pointing device. The active surface adjustment then conforms the adjacent borders and the surface defined thereby to the adjustment made by the clinician, much as a balloon conforms when depressed at a point on its surface. The clinician can thus observe the effect of an adjustment made to one border on the temporally surrounding borders of the cardiac cycle.

[0037] In a preferred embodiment the control points are not simply distributed at uniform intervals around the drawn border, but their positions correspond to constant anatomical locations from frame to frame over the heart cycle. This may be done by referencing the control points of the image to those of a reference image through speckle tracking, feature

tracking, or any kind of vector velocity or displacement processing. Since points in anatomy shown in an ultrasound image will exhibit a substantially constant pattern of speckle from frame to frame, the control points in other images can be located at points on their respective drawn borders which correspond to their characteristic speckle locations on the reference image. When the control points are located at constant anatomical positions they will appear to move closer together and then further apart through the heart cycle as the heart wall contracts and expands. When a control point X is relocated on a border by the clinician, the corresponding control point X's on the other images are correspondingly relocated automatically to the new speckle-tracked locations on each image. Such constant anatomical locations for the control points are important when assessing local heart wall motion as discussed below.

[0038] Since each of the images shown in **FIG. 8** is one image in the cardiac loop of images, the clinician can further verify the accuracy of the borders of the end diastole and end systole images **76, 78** by playing the cardiac loop of images behind the borders drawn on the display of **FIG. 8**. This is done by selecting one of the images of **FIG. 8**, then selecting "Play" from the system menu to repetitively play the cardiac loop in real time or at a selected frame rate of display behind the border. In the end diastole image **76** the endocardium is at its maximum expansion; hence, the endocardium in the loop should appear to move inward from and then back to the endocardial border drawn on the end diastole image. In the end systole image **78** the endocardium is fully contracted; hence, the endocardium in the loop should appear to move outward and then back to the border in this image. If the endocardium does not move in this manner and, for example, is seen to pass through the border, a different image may need to be chosen for end diastole or end systole, or manual adjustment of a drawn border may be necessary. Of course, the loop and its drawn borders over the complete cardiac cycle can be replayed, enabling the clinician to view to endocardial tracing as it changes with the heart motion in real time.

[0039] As the ABD processor is identifying the key landmarks and fitting borders to the sequence of images, it is periodically making confidence measurements to gauge the likelihood that the image borders are being accurately located and traced. For instance, if the septum is not clearly contrasted from the blood pool in the LV chamber, the automated process will stop. If the various correlation coefficients do not exceed predetermined thresholds the process will stop. Both spatial and temporal confidence measurements are employed. For instance, if the computed border of an image varies too much from a standard shape in either size or shape, the process will abort. This can arise if the landmarks are located in unusual positions in relation to each other, for example. If the change in the computed border from one image in the sequence to another is too great, the process will likewise abort. When the process stops, a message is displayed notifying the clinician of the reason for stopping the process, and gives the clinician the option to continue the automated process, to continue the automated process with or after clinician input, or for the clinician to acquire a new loop of images or manually trace the current images.

[0040] In the illustrated example of **FIG. 8** the automatically drawn borders of the end diastole and end systole



images are used to compute the heart's ejection fraction. This is done by an automatic modified Simpson's rule process which divides the delineated heart chamber at each phase into a stack of virtual disks. The diameter of each disk is used with the disk height to compute an effective volume of each disk, and these volumes are summed to compute the heart chamber volume at both end diastole and end systole. The difference between the two yields the ejection fraction, the volume or percentage of the heart volume which is expelled as pumped blood during each heart cycle. The ejection fraction calculation is shown in the measurement box at the lower left hand corner of **FIG. 8** and is constantly updated. Thus, if the clinician should adjust a drawn border by the rubberbanding technique, the computed volume of the heart during that phase will change, affecting the ejection fraction calculation, and the new calculation immediately appears in the measurement box. As the clinician adjusts the drawn borders he instantaneously sees the effects of these changes on the calculation of the ejection fraction.

[0041] In the previous example the clinician began by acquiring a cardiac loop on which to automatically trace borders. **FIG. 10** shows an ultrasound image display in which a loop is acquired based upon the ability of the ABD processor to automatically draw borders on the images. In the illustrated display the real time ultrasound image **10** is continuously viewed as in **FIG. 1** as the clinician manipulates the transducer probe to acquire the desired four chamber view of the heart. As the clinician manipulates the probe the ABD processor is operative to attempt to draw borders on at least one of the images of each cardiac cycle. Using the R-wave timing of the ECG trace **12**, the ultrasound system automatically selects the image or images to be traced from each loop. The selected image could be the first image of a cardiac cycle, the end diastole image, or the end systole image, for instance. As the ABD processor attempts to draw borders on the fly on the selected images of the real time loops, the results of the ABD process for an image of each loop is shown as a small "thumbnail" image **92-98** below the real time image **10**. In the illustrated example four thumbnail images are shown for four consecutive loops. Each time a new thumbnail is processed by the ABD processor it appears at the right side of the row of thumbnail images, the oldest thumbnail image disappears, and the row slides to the left. Initially the clinician may not be acquiring the heart in an orientation which is acceptable for the ABD process, at which time the progression of thumbnail images will show no borders as the ABD processor is unable to successfully draw borders on the images. But as the clinician manipulates the probe to acquire the necessary viewing plane for successful ABD performance and the images are acquired with better clarity and definition, borders will appear on the progression of thumbnail images as shown in the drawing figure. When the clinician is holding the probe at the necessary angulation relative to the heart so that the ABD process is continuously successful, the progression of thumbnail images will continuously show successfully drawn borders. The clinician will then freeze the acquisition to capture one or more of the successfully traced loops in the Cineloop memory, and will then select one of the loops for full ABD processing and display as described above. Thus, the ABD processor is used to assist the clinician in manipulating the probe for successful image acquisition and in acquiring loops which can be successfully processed for border definition by the ABD processor.

[0042] Another way to indicate to the clinician that acceptable images for ABD processing are being acquired is by means of a graphical ABD success indicator. Such an indicator may be qualitative, quantitative, or both, as is the example shown in **FIG. 10**. At the right of the display of **FIG. 10** is a gauge **110** which is quantified from zero to 100%. When the clinician is acquiring images which are unsuitable for ABD processing, the gauge **110** is empty. But as suitable images begin to be acquired, a color bar **112** begins to rise from the bottom of the gauge. The quantization of the gauge indicates either the percentage of borders which were attempted and successfully drawn, or the changes in overall confidence measures as discussed above. In the drawing a green bar is at the 80% level, indicating that the ABD processor was able to successfully process 80% of the images attempted over a recent interval such as the last few heart cycles, or that the borders drawn achieved an 80% confidence level of accuracy.

[0043] A third way to indicate ABD success to the clinician is to present drawn borders in real time on the real time images **10**. The ABD processor can attempt to draw a border on a single image for each heart cycle, such as the end systole image, and the successfully drawn border is displayed over the real time image for the duration of that heart cycle until the time of the next end systole image. Alternatively, if sufficient processing speed is available, borders are calculated and displayed for every image in the heart cycle. In either case, the drawn border will not appear or will flicker on and off when unsuitable or marginal cardiac images are being acquired, but will constantly appear when a succession of suitable images is being acquired, at which time the clinician knows that the probe is oriented to acquire good four chamber views for ABD processing.

[0044] In addition to the LV of four chamber views, the ABD processor of the present invention can also define borders in other types of ultrasound images. Short axis views can be processed for automatic border definition, in which case the landmarks used can be the annulus or the outflow track. Alternatively, the center of the heart chamber can be found from its contrast with the surrounding heart wall, then the desired border located by radial extension and fitting of a circular standard shape. The walls of blood vessels such as the carotid artery can similarly be traced by identifying the center line of the vessel, then extending straight line shapes out from opposite sides of the center line to fit small line segments to the endothelial wall. Fetal anatomy such as the fetal cranium can also be automatically traced by use of an elliptical shape.

[0045] With the ability to automatically draw borders of structures of the heart such as the endocardium on a complete loop of images, a number of diagnostic techniques become practical. For instance, **FIG. 11** illustrates a technique for assessing regional wall motion using automated border detection. The drawing of **FIG. 11** represents an ultrasound display in which the continuous motion of the endocardium or myocardium is shown over several complete heart cycles. The ABD processor is operated as described above to draw a trace along the endocardial border or continuously through the myocardium of the images of one or more loops. The latter is performed by tracing the endocardial border as described above, then drawing a curve parallel to and slightly larger than the endocardial border curve. Such a curve will reliably pass continuously through

the heart muscle. The border **100** for one such image is shown at the left side of the drawing, with the landmark points and control points numbered from one to eight in sequence around the border. For analysis of wall motion the image points beneath the border are Doppler processed to determine the velocity, Doppler power or variance along the defined border. Thus, a tissue Doppler image line is computed along the endocardium or myocardium at locations defined by the automatically drawn border. This Doppler processing is performed for the defined border of each image in the loop or loops. The Doppler processed information from the moving tissue may be fundamental frequency signals or harmonic frequency signals which can be processed as described in U.S. Pat. No. 6,036,643. The lines of Doppler values for all of the images are displayed in straight vertical lines as shown at the right side of **FIG. 11** as indicated by the vertical sequence of numbers **1-8**. The lines are arrayed sequentially adjacent to each other in the time sequence of the images. The Doppler values are preferably displayed in color, thus forming a color M-mode display area **102**. The display in area **102** may be referred to as an ABD-TDI (ABD with tissue Doppler imaging) display. In the illustrated display the color Doppler lines for the first loop are arrayed across the area indicated by bracket **L1**, the color Doppler lines for the next loop are arrayed across the area indicated by bracket **L2**, and the color Doppler lines for the third loop are arrayed across the area indicated by bracket **L3**, and so on. As the arrow at the bottom of the display area **102** indicates, the Doppler lines progress in time in the horizontal direction. This display **102** thus shows in a continuum over the heart cycle the motion of the LV myocardium. This display enables the clinician to follow the motion of one point or region of the heart wall over a full cardiac cycle by observing a horizontal row of the display. For instance, the heart wall at the apex of the heart is marked by **5** at the left of the area **102**, corresponding to the apex landmark **5** on the border **100**. By viewing the Doppler data (colors) to the right of **5** in area **102** the clinician is able to see the velocity or change in velocity or intensity of motion of the heart wall at the apex of the heart as it varies over the complete heart cycle or cycles. If a region of the wall is not moving due to infarction or some other defect, it can be spotted by a change or difference in color at a particular horizontal elevation in the ABD-TDI display.

[0046] It will be appreciated that, since the LV heart wall is constantly expanding and contracting as the heart beats, the length of the line **100** from the MMA, around the apex, and back to the LMA is constantly changing in correspondence. If the control points are simply delineated in even spacings around the line **100**, they may not continuously correspond to the same points of the heart wall through the full heart cycle. This is overcome by tracking the anatomy from a baseline of control points over the heart cycle, as by speckle tracking each local point of the heart wall along the ABD trace from frame to frame, as described above. The different length lines are rescaled or normalized to a common length so that a horizontal line extended to the right from each number at the left of the display **102** will relate to the same point or region of the heart wall over the continuum of tissue Doppler lines.

[0047] An ABD-TDI display may also be formed from short axis images of the heart. In short axis views the heart wall exhibits a ring shape. As described previously, the endocardium can be traced automatically for each frame of

the cardiac cycle and a parallel, slightly larger circle than the tracing can be drawn through the myocardial muscle in the images. Doppler values are acquired around each of these circles, which are displayed in a continuum of lines in the format shown in area **102** of **FIG. 11**. Thus, the display format **102** may be used for either short or long axis views of the heart.

[0048] Another application for automatically drawn cardiac borders is shown in **FIG. 12**. In this illustration the border **300** represents the endocardial border defined by automated border detection as described above, with a line **306** for the mitral valve plane at the bottom. A second, slightly larger border **302** is drawn around the first border **300**. This second border may be an ABD-produced border of the epicardium, or it may be a trace spaced by a predetermined lateral distance  $d$  normal to the endocardial border **300**. In this latter case, the trace **302** can pass continuously through the myocardium. Thus, Doppler values along the trace **302** would yield motional measures taken in a central portion of the heart muscle. The space between the two traces can be divided into small areas **304** and the Doppler values within each area integrated to produce a measure of regional wall motion at a particular location on the LV wall. These measures are made using ABD processing of many or all of the images of the cardiac loop to quickly and accurately provide quantified measures of cardiac performance over most or all of the cardiac cycle.

[0049] The measurements made from the areas **304** can be used to automatically fill out an anatomically corresponding scorecard for cardiac performance. For example, **FIG. 13a** shows a graphical representation **310** of the LV in a 4-chamber view, with the myocardium divided into numbered areas. The region numbered **6** on the anatomical scorecard **310** corresponds to the small areas **304a-304d** which were defined by automatically drawn borders. The measurements taken in these areas **304a-304d** can be aggregated and used to automatically place a score on the scorecard **310** for region **6**, which may be numerical or qualitative, for example, a coded color. The score can be a peak or average value measured for one phase of the heart cycle or taken over all the frames of the full heart cycle. **FIG. 13b** illustrates a similar anatomical scorecard **312** for a short axis view of the heart, which may be used to score images with automatically drawn borders acquired from that view. A scorecard may be filled in for just a single image frame, for a group of image frames taken together, or a scorecard may be completed for each frame of a cardiac sequence. In the latter case, color coded scorecards can be played in rapid succession in a real time (or slower or faster) loop of images of the scorecards, enabling the clinician to view the time variation of a region of the heart in a segment of the scorecard which is stationary on the display screen from frame to frame.

[0050] Automatically drawn cardiac borders may also be used to define the myocardial area in contrast-enhanced images or loops. The addition of a contrast agent to the cardiac imaging exam allows the physician to assess how well the heart muscle is being perfused with blood. Automatically computed borders may be used as input into a variety of perfusion quantification algorithms. Automatically drawn cardiac borders and perfusion information presented simultaneously in an image or loop is a powerful combination since the clinician can assess wall motion,

thickening, and perfusion simultaneously. Given that the borders are known, the thickness of the myocardial walls between the endocardial and epicardial edges can be determined on a segment-by-segment basis as shown in **FIG. 12**. Perfusion information quantified by an independent algorithm may also be displayed side-by-side with the quantitative wall thickening information. Quantitative perfusion information and wall thickening may also be parametrically combined and presented on a segment-by-segment basis in a color coded display for Doppler and wall motion integration.

[0051] Another diagnostic technique made practical by automatic border detection is strain rate analysis of cardiac performance. The strain rate is a measurement computed as the axial derivative of the velocity of the tissue, and can lead to a representation of the relative deformation of the tissue during contraction or expansion. The conventional way to compute strain rate in an ultrasound image is to find Doppler velocity values along the ultrasound beams, then to compute the spatial gradient as a derivative using successive velocity values along the beam. This spatial gradient of velocity is thus strongly dependent upon the variable relationship between the beam directions and the anatomy in the image, which means that the strain rate values can change as the probe is moved. The present inventors prefer to use a strain rate calculation which is dependent upon the direction of tissue motion rather than an arbitrary beam direction. Accordingly the present inventors calculate strain rate in the direction of the velocity vector of tissue motion. In order to do this it is necessary to have not only velocity values for the tissue pixels in an image but also the direction or vectorial component of the motion, which can be obtained by known vector Doppler techniques. The differential between adjacent pixels in the direction of motion is then computed as the strain rate. The strain rate can be computed from fundamental frequency echo information, or from harmonic frequency signals which can be more clutter-free than the fundamental frequency signals.

[0052] **FIG. 14a** shows two traces which have been automatically drawn over the borders of a 4-chamber view of the LV. The border **250** is drawn to define the endocardium and the border **252** has been drawn to define the epicardium of the LV. A third trace **260** is automatically drawn between the endocardial and epicardial borders. This third trace **260** will reliably pass continuously through the myocardium. These traces enable the strain rate to be computed for the two major components of motion of the LV. One of these components is the contraction and expansion of adjoining cells in the heart muscle. This motion is generally along the direction of the trace **260**. A strain rate representation of this cellular motion can be found by differentiating the velocity values of successive points A-A' along trace **260** as shown in the drawing. The overall motion of the heart chamber as the muscle cells contract and expand is **248** toward and away from the center of the heart chamber. A strain rate representation of this second motional component is computed by differentiating velocities in a direction normal to the drawn borders such as at points B-B' across the heart muscle. The strain rate so calculated along the myocardium is preferably displayed in a color-coded representation. A similar set of strain rate measurements can be made using borders **270** (endocardium) **272** (epicardium) and trace **280** (myocardium) drawn on short axis views of the heart such as that shown in **FIG. 14b**. In that drawing muscle cell contraction

and expansion is used to compute strain rate in the circumferential direction such as would be computed from the velocities at points A-A' in the image. Radial components of expansion and contraction are represented in a strain rate display by differentiating in the radial direction such as by using the velocities at points B-B', C-C', and D-D'. The strain rate over the full cardiac cycle can be displayed by computing the strain rate around the entire border for each frame in the cardiac cycle, then displaying the strain for each frame as a vertical line in a time sequence of lines as shown by display **102** in **FIG. 11**.

[0053] **FIGS. 15a** and **15b** illustrate the use of automated border detection in three dimensional imaging. The previous examples have shown how borders can be automatically drawn on two dimensional cardiac images. The technique described above is effective for defining the borders of three dimensional cardiac images also. If a three dimensional cardiac image is produced by acquiring a series of spatially adjacent 2D image planes of the heart, the ABD process described above can be performed on each component frame to define a series of boundaries which together define a surface of the heart such as the endocardial surface. If the three dimensional cardiac image is produced from ultrasonic beams steered in three dimensions to scan the heart three dimensionally in real time as described in U.S. patent application Ser. No. 09/645,872 entitled "ULTRASONIC DIAGNOSTIC IMAGING OF THE CORONARY ARTERIES," the resulting three dimensional data set can be divided into a series of parallel planes which are processed as described above to define a series of planar borders which can be assembled to provide a boundary such as the heart wall. Preferably the three dimensional data set is processed three dimensionally, in which case advantage is taken of the contiguous nature of the heart wall in three dimensions in the data set to more reliably define the three dimensional border. In either case, the resultant three dimensional border of the LV endocardium may appear as shown in **FIG. 15a**, a somewhat elongated pouch-like surface which is closed at the apex end A and open at the mitral valve plane A'. **FIG. 15a** represents the three dimensional endocardial surface traced at one phase of the heart cycle. In each 3D image of a 3D cardiac loop the endocardial surface will be slightly different as the LV continuously contracts and expands during the heart cycle. Thus a different border surface **200** can be computed for each three dimensional image in the loop. Since the speed of sound may not enable the ultrasonic data for a full 3D image to be acquired at the desired 3D frame rate, the 3D images may be built up over time by using a heart gate triggered from the ECG waveform to acquire the data for a portion of a 3D image at specific phases of the heart over numerous cardiac cycles until the full data set necessary to produce 3D images of the desired temporal spacing over the entire heart cycle is acquired.

[0054] The 3D image of the endocardium in **FIG. 15a** can be produced by Doppler processing, thereby revealing the velocity, variance, or Doppler power at each point on the LV wall by rotating and examining the endocardial tissue Doppler surface **200**. Another way to view the Doppler information for the entire endocardium is to "unwrap" the tissue Doppler surface **200** to a two dimensional form as shown in **FIG. 15b**. In this illustration the apex is located at A and the mitral valve plane extends along the bottom edge between A' and A'. In this display the clinician can examine the motion of the entire endocardium in one view. Such a display shows

motion at only one phase of the heart cycle, the phase indicated by cursor **14** below the ECG waveform **12** of the display, and thus it is desirable to unwrap all of the endocardial surfaces from all of the 3D images of the heart cycle and arrange them in a "stack" so that the clinician can view them sequentially in any order. If the clinician spots a motional abnormality on one of the unwrapped images, such as in the area denoted by box **202**, she can focus in on this cardiac wall location where the abnormality is seen. She can then scan through the stack of images in the box **202** in either temporal order to examine the abnormality in greater detail over the full heart cycle. Alternately, the clinician can draw a line through the abnormality in box **202**, then display the tissue Doppler values along that line from all the images in the sequence in an ABD-TDI display **102** as described above.

[0055] If real time 3D imaging capability is not available, a 3D diagnosis can still be performed by acquiring multiple image planes of a chamber of the heart at different orientations, which are then processed by automatic border detection. An ultrasound system which acquires ultrasound information from only selected planes of an organ of the body is described in U.S. patent [application Ser. No. 9/641,306], entitled "METHOD OF CREATING MULTIPLANAR ULTRASONIC IMAGES OF A THREE DIMENSIONAL OBJECT." FIG. 15c is an illustration of the endocardial border **200** viewed from the apex A in the center of the drawing, which is how the heart may be viewed by a transducer probe placed for an apical view as described above. With the probe so located, ultrasound information is acquired from three planes which pass through the heart chamber, labeled **204**, **206** and **208** in the drawing. In this drawing the planes are viewed edge-on, and in this example the three planes intersect in the vicinity of the apex of the LV. The ultrasound information from the three planes may be acquired at a particular phase of the heart cycle chosen by and ECG heart gate, or over the full cardiac cycle which may also be assisted by ECG gated acquisition over a number of cardiac cycles. The LV endocardial borders in the images of the three planes are automatically drawn as described above and analyzed.

[0056] A quick method for identifying a region of the heart where more detailed study is required is to score cardiac performance on a symbolic representation of the heart. One such symbolic representation is the bullet scorecard **210** shown in FIG. 15d. The scorecard **210** represents the heart muscle of a chamber of the heart as if the myocardium were spread out in a single plane with the apex at the center of the scorecard and the juncture of the myocardium and the mitral valve plane located around the perimeter of the scorecard. Each sector of the scorecard **210** extending from the center to the perimeter represents a different section of the heart muscle extending from the apex to the mitral valve plane. The areas in the scorecard are numbered to refer to specific areas of the heart wall. For instance the image plane **204** of FIG. 15c would intersect areas **1**, **7**, the center of the scorecard, and areas **10** and **4**. The image plane **206** of FIG. 15c would intersect areas **6**, **12**, **16**, **14**, **9** and **3** of the scorecard, and the image plane **208** of FIG. 15c would intersect areas **5**, **11**, **15**, **13**, **8** and **2** of the scorecard. The Doppler-detected motion on an automatically drawn border in one or more image frames in the image planes is used to enter data in the scorecard **210**. The scorecard is filled in automatically using the motion information from the auto-

matically drawn borders to indicate areas of the heart where detailed diagnosis is warranted. For instance, if cardiac behavior in the plane **204** of the LV is normal, areas **1**, **7**, **10**, and **4** can be displayed in green on the ultrasound system display. If an unusual characteristic such as abnormal motion is sensed in the vicinity of the juncture of the myocardium and the mitral valve plane, area **1** may be displayed in yellow (for mild irregularity) or red (for a serious irregularity), to caution the clinician to look more closely at this area. Numerical scores may be used in addition to or alternatively to color-coding. A preferred four-tiered scoring system for cardiac performance is to score regions of the heart muscle as being either normal, hypokinetic, dyskinetic, or akinetic. Thus the displayed bullet scorecard with its color-coded or numerically scored areas will point the clinician to regions of the heart where more detailed diagnosis should be performed.

[0057] It is preferable, of course, to use a complete 3D data set to fill in the scorecard **210**. For instance, the defined heart wall **200** of FIG. 15a can be "flattened," and spread in a circle about the apex so that each area of the myocardium in the data set corresponds to an area of the scorecard. The motional data over a section of the flattened heart wall **200** can be averaged to fill in a corresponding section of the bullet scorecard **210**. For example, the motional data over section **212** of the endocardial data **200** can be averaged to automatically compute a score (either quantitative or qualitative) for corresponding area **5** of the scorecard **210**. The scores for section **212** from a plurality of endocardial data sets taken over the full heart cycle can also be averaged or outlying values detected to produce a scorecard of averages of cardiac performance or greatest degrees of abnormal performance.

[0058] FIG. 16 illustrates an ultrasound system constructed in accordance with the present invention. A probe or scanhead **410** which includes a 1D or 2D array transducer **412** transmits ultrasonic waves and received ultrasonic echo signals. This transmission and reception is performed under control of a beamformer **420** which processes in received echo signals to form coherent beams of echo signals from the anatomy being scanned. The echo information is Doppler processed by a Doppler processor **430** when ABD-TDI information or strain rate information is to be presented, and the processed Doppler information is coupled to an image processor **440** which forms 2D or 3D grayscale or Doppler images. The images pass through a Cineloop memory **460** from which they may be coupled directly to a video processor **470** for display on an image display **480**. The images may also be applied to an ABD processor which operates on the 2D or 3D images as described above to define the anatomical borders and boundaries in the images. The defined borders are overlaid on the images which are coupled to the video processor **470** for display. The system may operate to define and display borders on loops of images saved in the Cineloop memory **460**, or to display borders drawn on real time images produced during live scanning of a patient.

What is claimed is:

1. A method for displaying information derived by automatic border detection in cardiac ultrasound images comprising:

- acquiring a sequence of cardiac ultrasound images;
- automatically tracing a border of moving tissue in each of the images;

computing motion along each of the traced borders; and displaying the computed motion along the traced borders as a function of time and location.

2. The method of claim 1, wherein the border tracings are nonlinear, and wherein the computed motion along each traced border is displayed linearly.

3. The method of claim 1, wherein the computed motion is displayed in colors corresponding to velocity.

4. The method of claim 1, wherein the border traced is the endocardium.

5. The method of claim 1, wherein the border traced is the epicardium.

6. The method of claim 1, wherein the tracing is offset from the endocardium in the direction of the epicardium.

7. The method of claim 1, further comprising:

automatically tracking corresponding anatomical points on each of the borders from image to image; and

displaying the motion of the corresponding anatomical points in spatial correspondence on a display.

8. The method of claim 7, wherein automatically tracking comprises tracking the speckle patterns of anatomical points along borders of the images.

9. The method of claim 7, wherein automatically tracking comprises tracking the tissue patterns of anatomical points along borders of the images.

10. The method of claim 1, further comprising manually adjusting one or more of the automatically traced borders.

11. The method of claim 1, wherein time is shown along one axis and location on the border is shown along the other axis.

12. A method for analyzing cardiac performance by automatic border detection in cardiac ultrasound images comprising:

acquiring a sequence of cardiac ultrasound images;

automatically tracing a border of the heart in one or more images;

segmenting the myocardium along each of the traced borders; and

analyzing the ultrasound information of one or more myocardial segments.

13. The method of claim 12, wherein analyzing comprises quantifying wall motion for the myocardial segments,

wherein quantified wall motion is displayed in the myocardial segments by colors indicating regional wall motion.

14. The method of claim 12, wherein analyzing comprises computing scores for the myocardial segments; and further comprising:

automatically entering the scores on a scorecard having entries relating to the myocardial segments.

15. The method of claim 14, wherein the scorecard comprises an electronic scorecard.

16. The method of claim 15, wherein the scorecard comprises a bullet scorecard having entries corresponding to segments of the heart wall.

17. The method of claim 15, wherein the scorecard comprises an anatomical representation of the myocardium.

18. The method of claim 15, wherein the entries comprise alphanumeric entries.

19. The method of claim 15, wherein the entries comprise colored or shaded entries.

20. The method of claim 12, wherein acquiring comprises acquiring a three dimensional image of the heart; and

wherein automatically tracing comprises automatically delineating the heart wall in a three dimensional image.

21. The method of claim 20, wherein analyzing comprises quantifying wall motion for myocardial segments of the three dimensional image,

wherein quantified wall motion is displayed in the three dimensional image by colors indicating wall motion.

22. The method of claim 20, wherein analyzing comprises computing scores for myocardial segments of the three dimensional image; and further comprising:

automatically entering scores on a scorecard having entries relating to the myocardial segments.

23. The method of claim 22, wherein the scorecard comprises an electronic scorecard having areas corresponding to areas of the heart wall delineated in the three dimensional image.

24. A method for analyzing cardiac performance by automatic border detection in cardiac ultrasound images comprising:

acquiring two or more images in different image planes which intersect a chamber of the heart;

automatically tracing a border of the heart in each of the images; and

analyzing cardiac performance in regions of the heart delineated by the automatically traced borders.

25. The method of claim 24, wherein acquiring further comprises acquiring ultrasonic signals by gated acquisition.

26. The method of claim 25, wherein acquiring further comprises acquiring ultrasonic signals by electronic beam steering.

27. The method of claim 25, wherein acquiring further comprises acquiring ultrasonic signals by mechanical beam steering.

28. The method of claim 24, wherein analyzing comprises computing and displaying regional wall motion along each of the automatically traced borders.

29. The method of claim 24, wherein analyzing comprises computing scores for delineated regions of the heart wall; and further comprising:

automatically entering scores on a scorecard having entries relating to the heart wall regions.

30. The method of claim 29, wherein the scorecard comprises an electronic scorecard having entries corresponding to regions of the heart wall.

31. A method for displaying measures of cardiac performance by automatic border detection in cardiac ultrasound images comprising:

acquiring three dimensional ultrasonic image data of a chamber of the heart;

automatically tracing a border of the heart in the three dimensional ultrasonic data; and

displaying in three dimensions a region of the heart delineated by the border.

**32.** The method of claim 31, wherein acquiring further comprises acquiring three dimensional motion data of the heart chamber; and

wherein displaying comprises displaying motional data of a region of the heart delineated by the border.

**33.** The method of claim 32, wherein the region of the heart comprises the heart wall.

**34.** The method of claim 31, wherein displaying further comprises displaying in two dimensions the region of the heart delineated by the border.

**35.** The method of claim 34, wherein displaying further comprises displaying in two dimensions motional ultrasonic information of the region of the heart delineated by the border.

**36.** The method of claim 31, further comprising delineating a region of interest on the displayed region of the heart.

**37.** A method for displaying information derived by automatic border detection in cardiac ultrasound images comprising:

acquiring a sequence of cardiac ultrasound images;

automatically tracing a border of moving tissue in each of the images;

computing motion along each of the traced borders utilizing harmonic signal information corresponding to the traced borders; and

displaying the computed motion along the traced borders as a function of time and location.

**38.** The method of claim 37, wherein computing comprises computing motion along the traced borders by Doppler processing harmonic signal information from moving tissue.

**39.** A method for analyzing cardiac performance by automatic border detection in cardiac ultrasound images comprising:

acquiring a sequence of cardiac ultrasound images;

automatically tracing a border of the heart in the cardiac images;

segmenting the myocardium along each of the traced borders;

computing scores for the myocardial segments; and

automatically entering the scores on scorecards having entries relating to the myocardial segments.

**40.** The method of claim 39, further comprising displaying the scorecards on a display in rapid time succession.

**41.** The method of claim 40, wherein rapid time succession is one of faster than, slower than, or equal to the real time display rate of the cardiac ultrasound images.

\* \* \* \* \*

专利名称(译)	超声诊断图像分析心脏功能		
公开(公告)号	<a href="#">US20020072672A1</a>	公开(公告)日	2002-06-13
申请号	US09/732614	申请日	2000-12-07
[标]申请(专利权)人(译)	ROUNDHILL DAVIDñ 查纳尔CEDRIC CRITON ALINE LAURE		
申请(专利权)人(译)	ROUNDHILL DAVID N. 查纳尔CEDRIC CRITON ALINE LAURE		
当前申请(专利权)人(译)	ROUNDHILL DAVID N. 查纳尔CEDRIC CRITON ALINE LAURE		
[标]发明人	ROUNDHILL DAVID N CHENAL CEDRIC CRITON ALINE LAURE		
发明人	ROUNDHILL, DAVID N. CHENAL, CEDRIC CRITON, ALINE LAURE		
IPC分类号	A61B8/08 A61B8/02 A61B8/12		
CPC分类号	A61B8/0858 A61B8/0883 A61B8/483 A61B8/485 A61B8/0891		
其他公开文献	US6447453		
外部链接	<a href="#">Espacenet</a> <a href="#">USPTO</a>		

#### 摘要(译)

通过自动边界检测获取并分割超声心脏图像信息。分段超声信息用于随时间显示区域壁运动。分段信息可以以颜色编码表示来呈现，或者作为定性或定量测量自动输入到心脏性能的记分卡上。本发明的技术适用于二维和三维超声图像信息。

