



(12) **Patent Application Publication**
Wang et al.

(10) **Pub. No.: US 2009/0312640 A1**
(43) **Pub. Date: Dec. 17, 2009**

(75) Inventors: **Shih-Ping Wang**, Los Altos, CA (US); **Donald Chin**, Palo Alto, CA (US); **Fangyi Rao**, San Jose, CA (US); **Nico Karssemeijer**, Beek (NL)

Correspondence Address:
COOPER & DUNHAM, LLP
30 Rockefeller Plaza, 20th Floor
NEW YORK, NY 10112 (US)

(73) Assignee: **U-SYSTEMS, INC., SAN JOSE,
CA (US)**

(21) Appl. No.: **12/546,339**

(22) Filed: **Aug. 24, 2009**

Related U.S. Application Data

(63) Continuation of application No. 10/305,936, filed on Nov. 27, 2002, now Pat. No. 7,597,663, which is a continuation-in-part of application No. 10/160,836, filed on May 31, 2002, now Pat. No. 7,556,602, which is a continuation-in-part of application No. PCT/US01/43237, filed on Nov. 19, 2001.

(60) Provisional application No. 60/252,946, filed on Nov. 24, 2000, provisional application No. 60/326,715, filed on Oct. 3, 2001, provisional application No. 60/415,385, filed on Oct. 1, 2002.

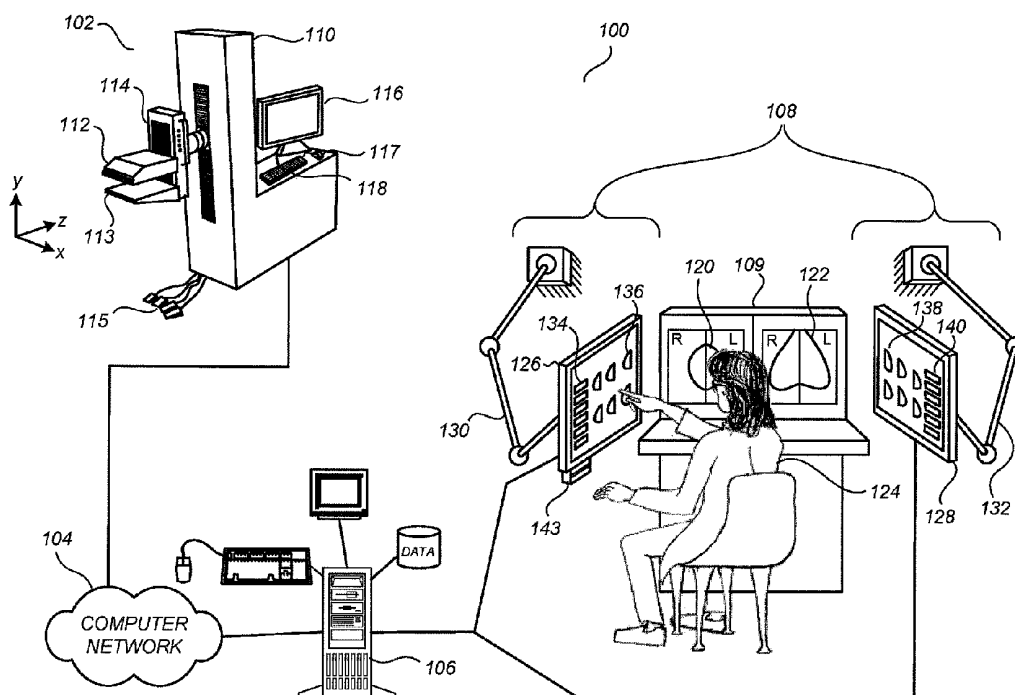
Publication Classification

(51) **Int. Cl.**
A61B 8/14 (2006.01)
G06K 9/00 (2006.01)
A61B 6/04 (2006.01)

(52) **U.S. Cl.** **600/443**; 382/131; 378/37

(57) **ABSTRACT**

An adjunctive ultrasound mammography system and associated methods are described comprising an adjunctive ultrasound display configured for quick, intuitive, interactive viewing of data derived from volumetric ultrasound scans, the data being displayed near a conventional x-ray mammogram display. Preferred embodiments for navigating among a thick-slice image array, a selected enlarged thick-slice image, and planar ultrasound views are described, including a preferred embodiment in which the planar ultrasound views are updated in real time as a cursor is moved across an active thick-slice image. In one preferred embodiment the thick-slice images are inverted prior to display, with non-breast areas of the image preferably segmented out and reset to dark. The inverted thick-slice images are of more familiar significance to radiologists having years of expertise in analyzing conventional x-ray mammograms. For example, the inverted thick-slice images allow benign features to be more easily dismissed as compared to non-inverted thick-slice images. Preferred embodiments for computing thick-slice image values from the volumetric scan data are also described that emphasize larger mass lesions in the resulting thick-slice images, and that compensate for mass lesions that straddle thick-slice region borders.



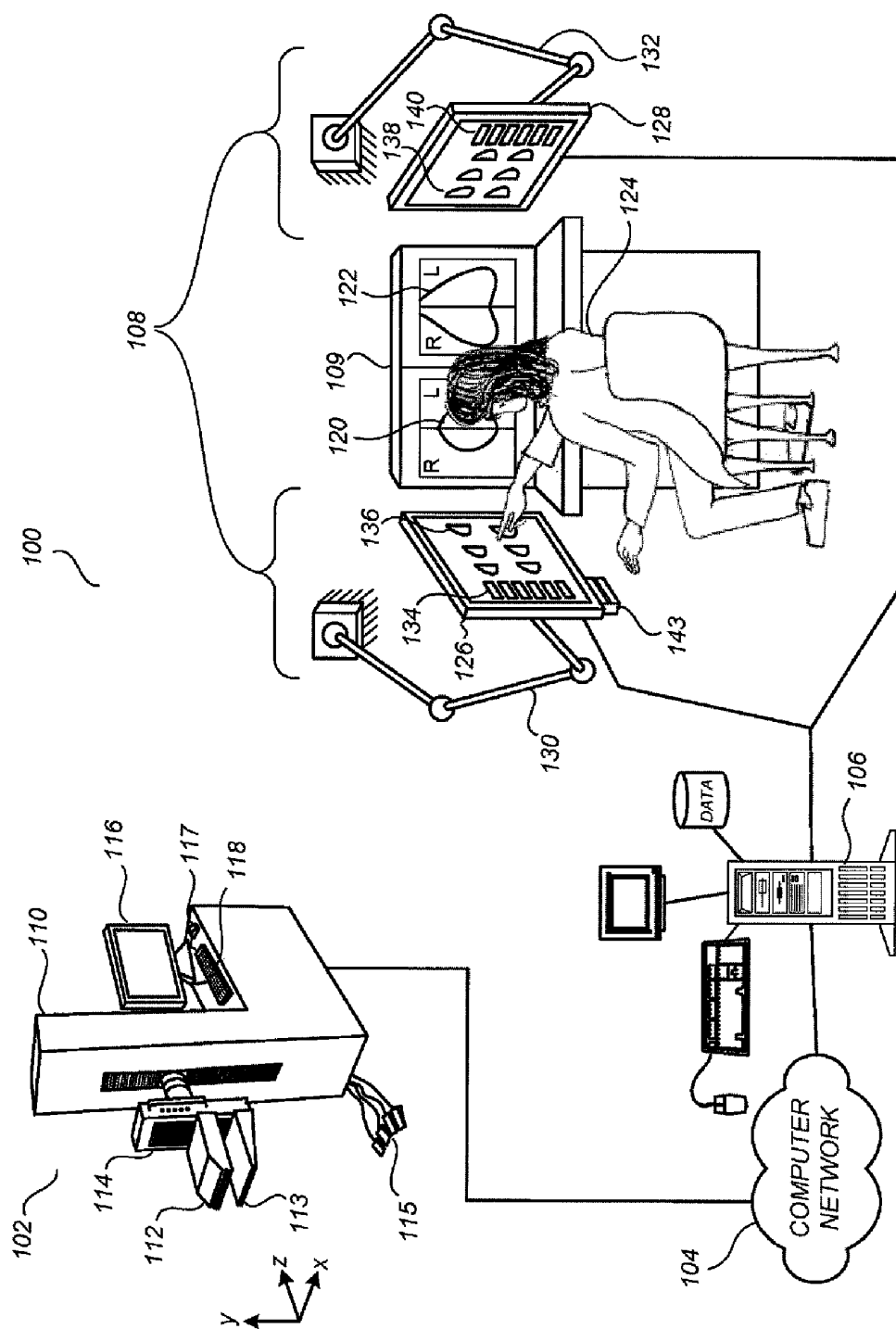


FIG. 1

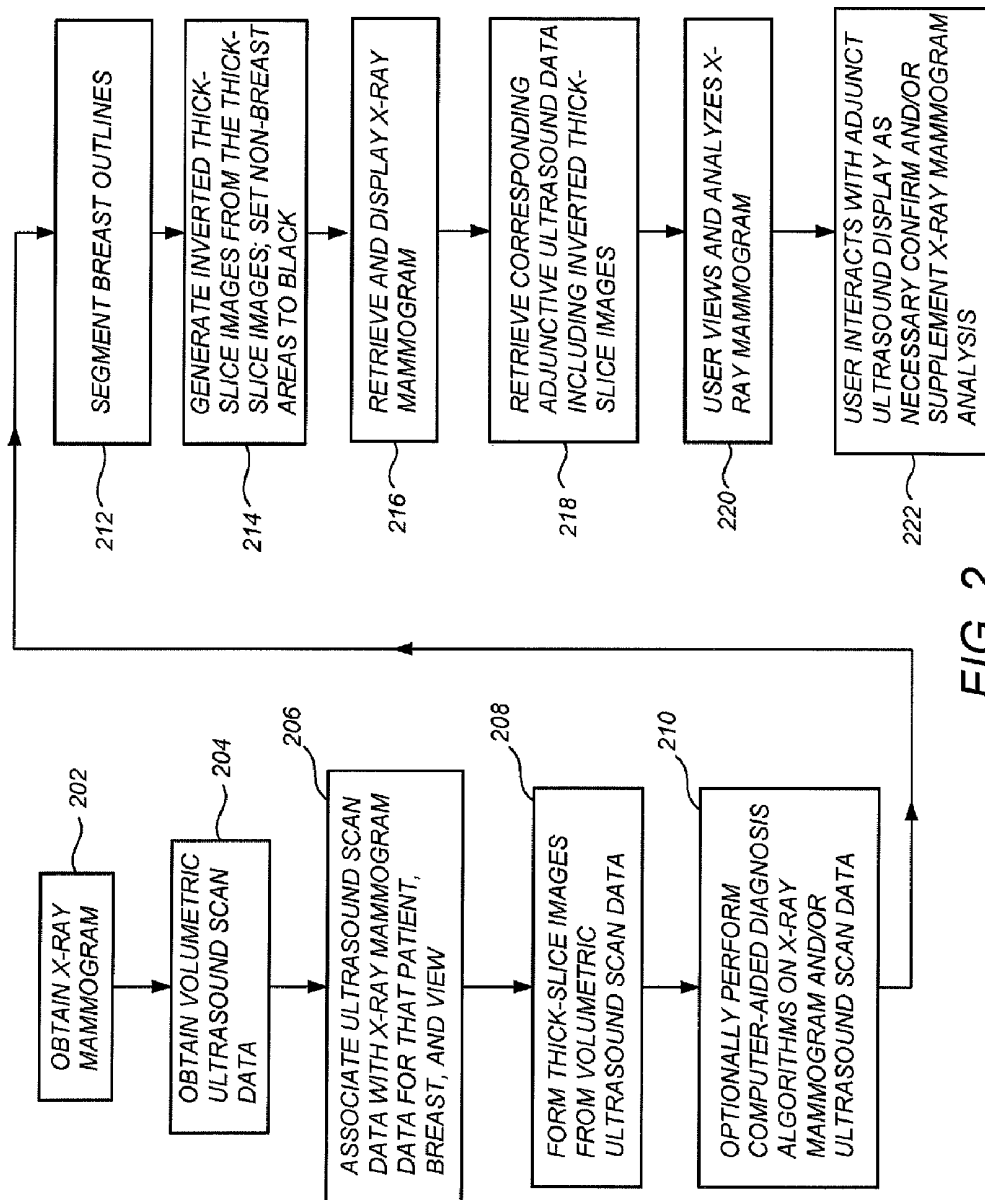


FIG. 2

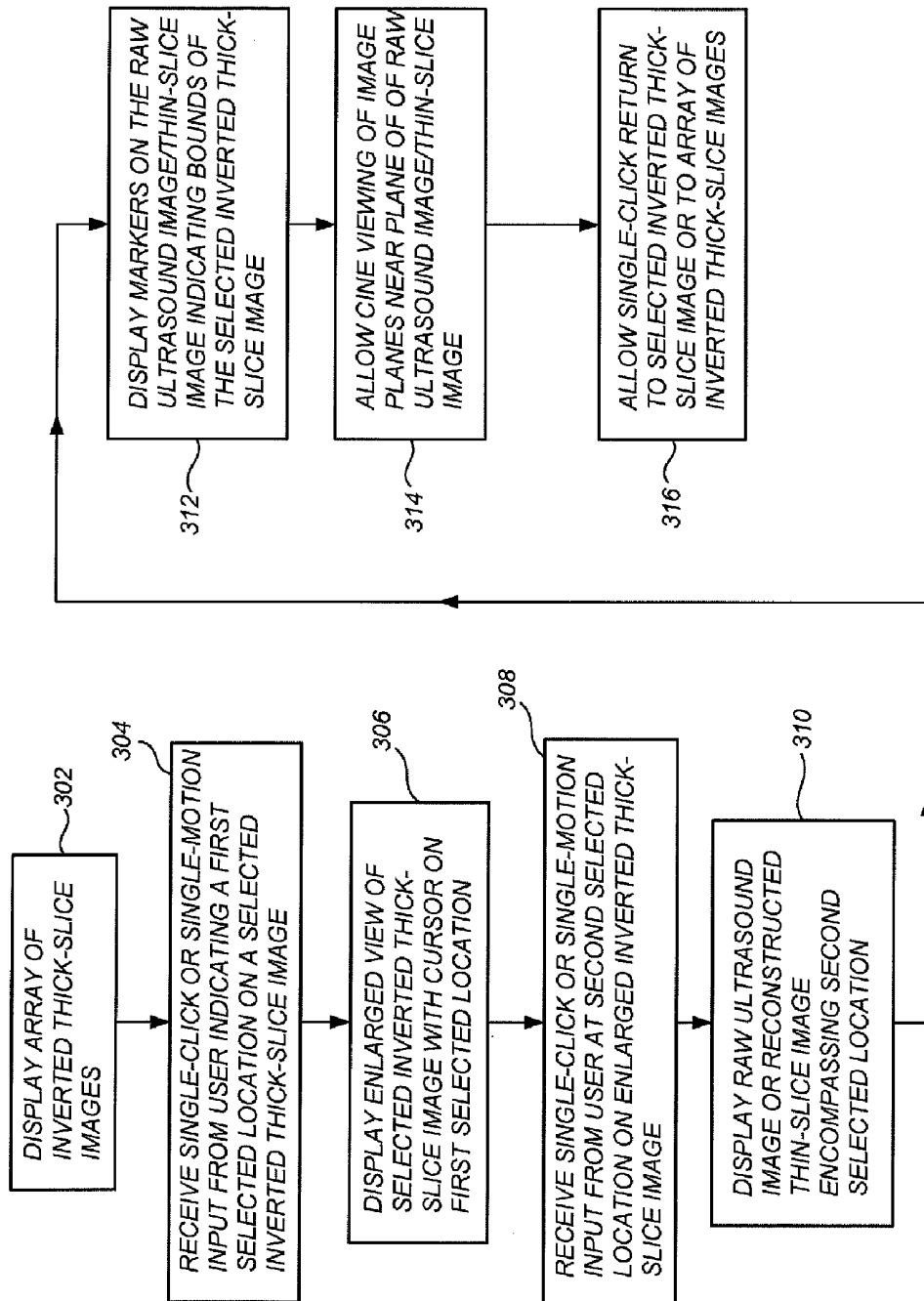


FIG. 3

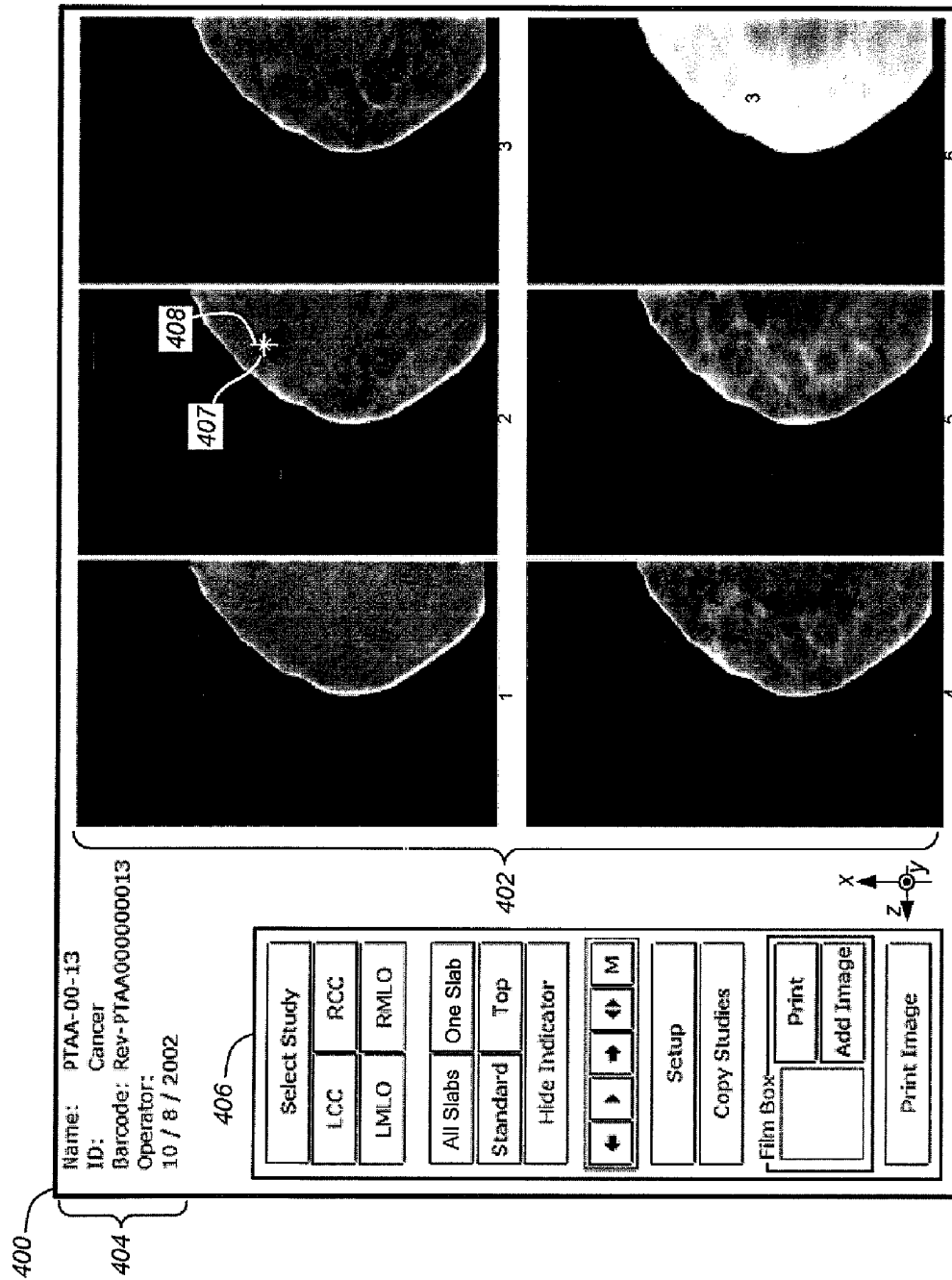
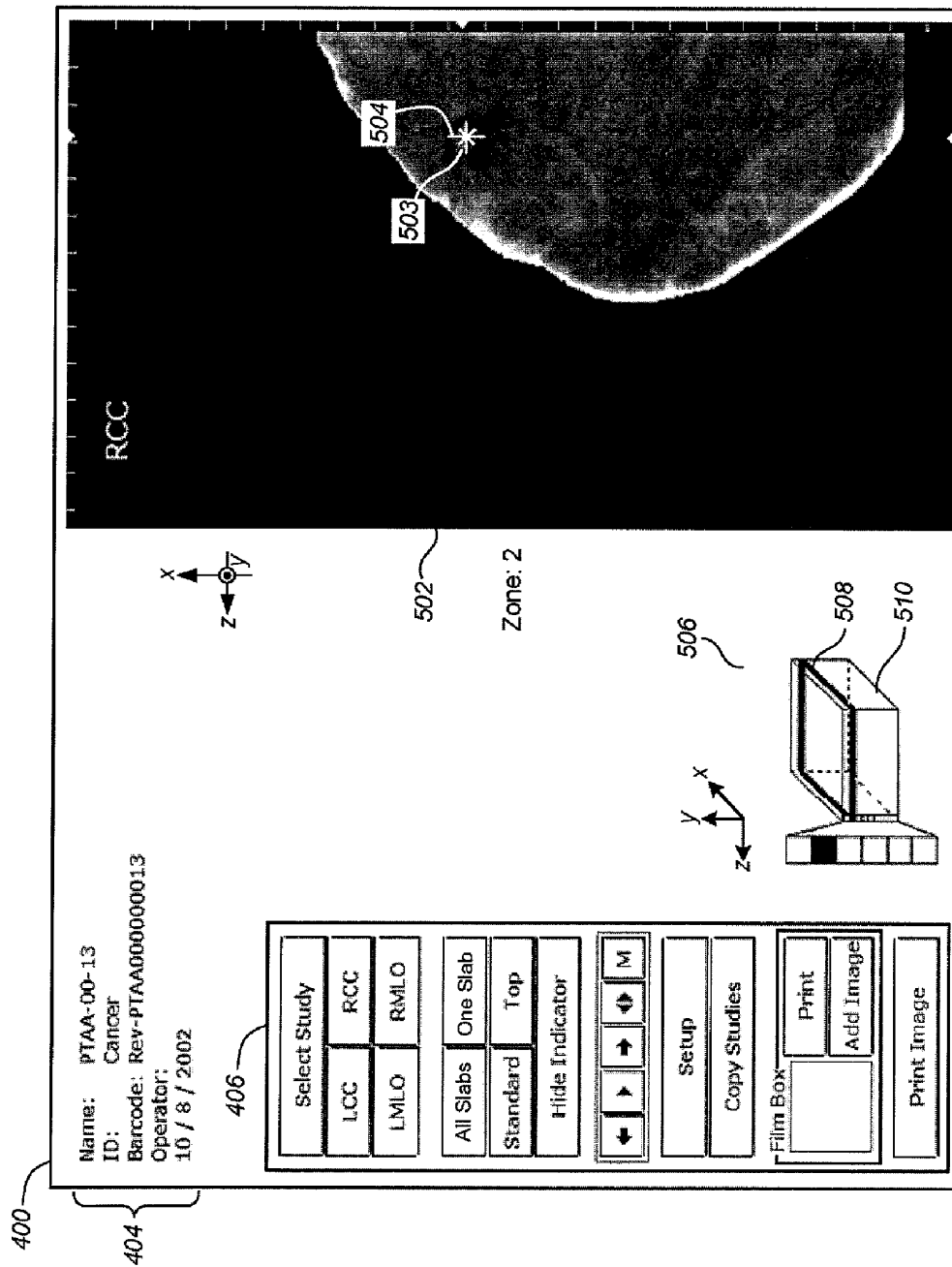


FIG. 4



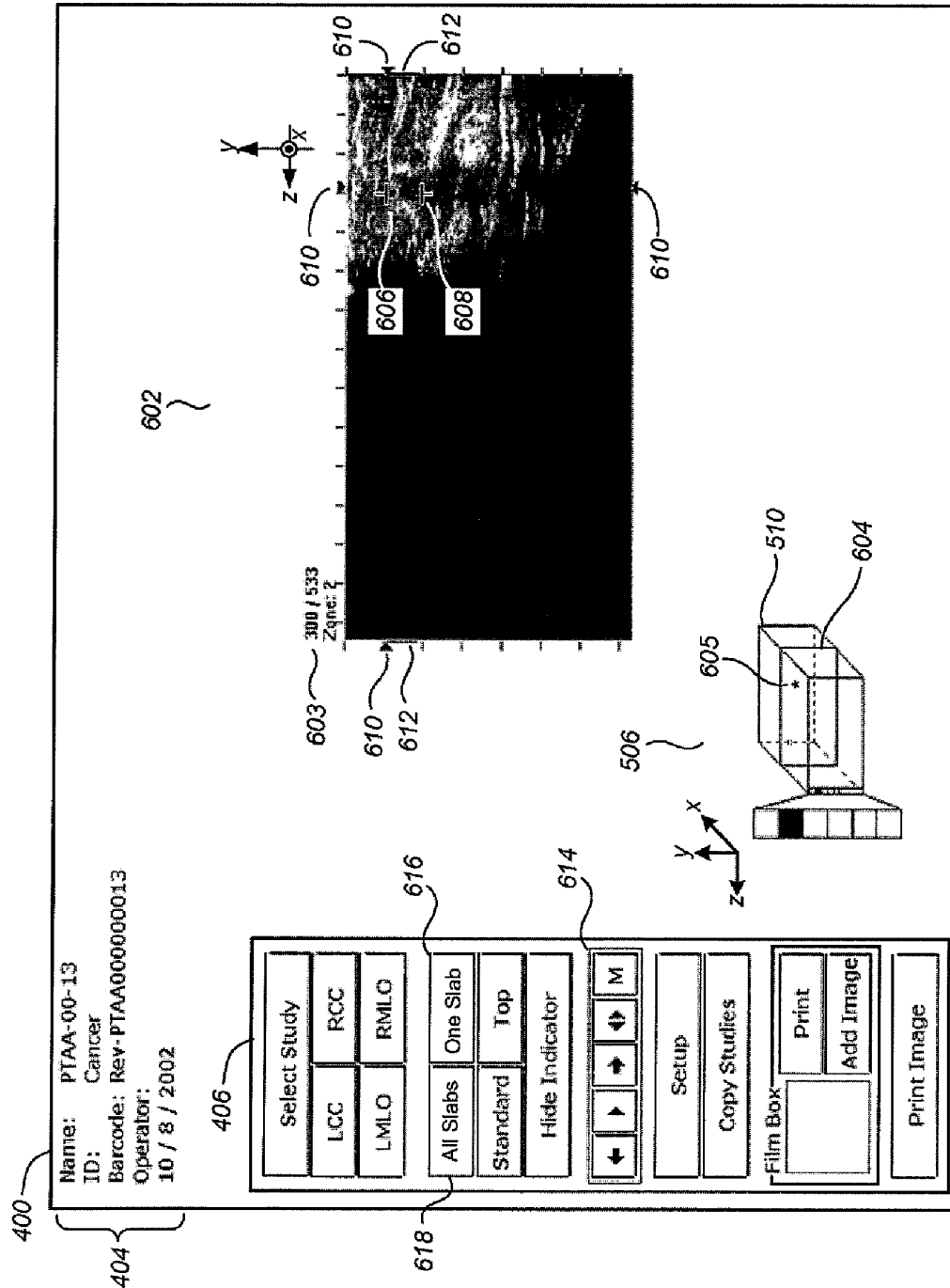


FIG. 6

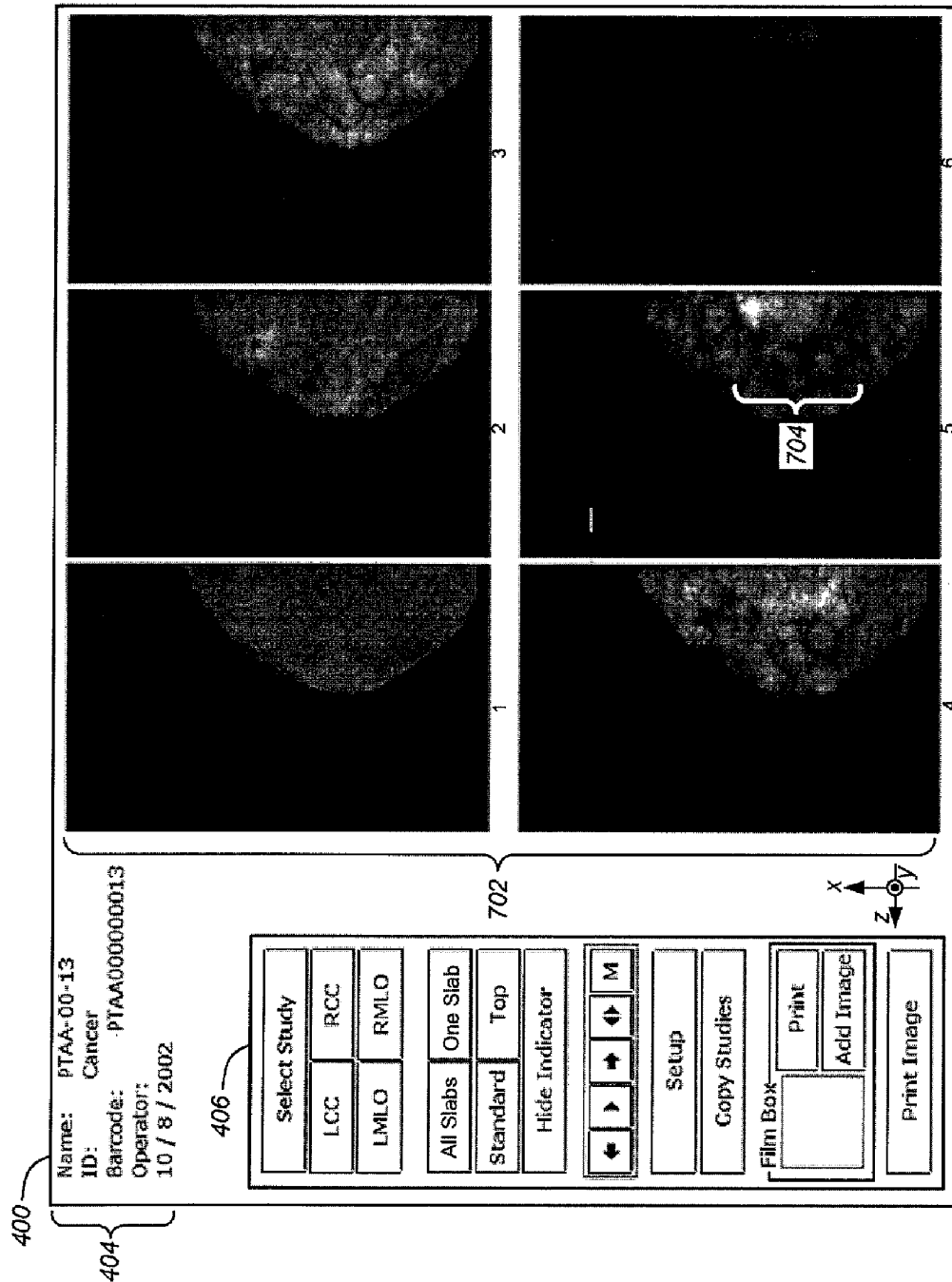


FIG. 7

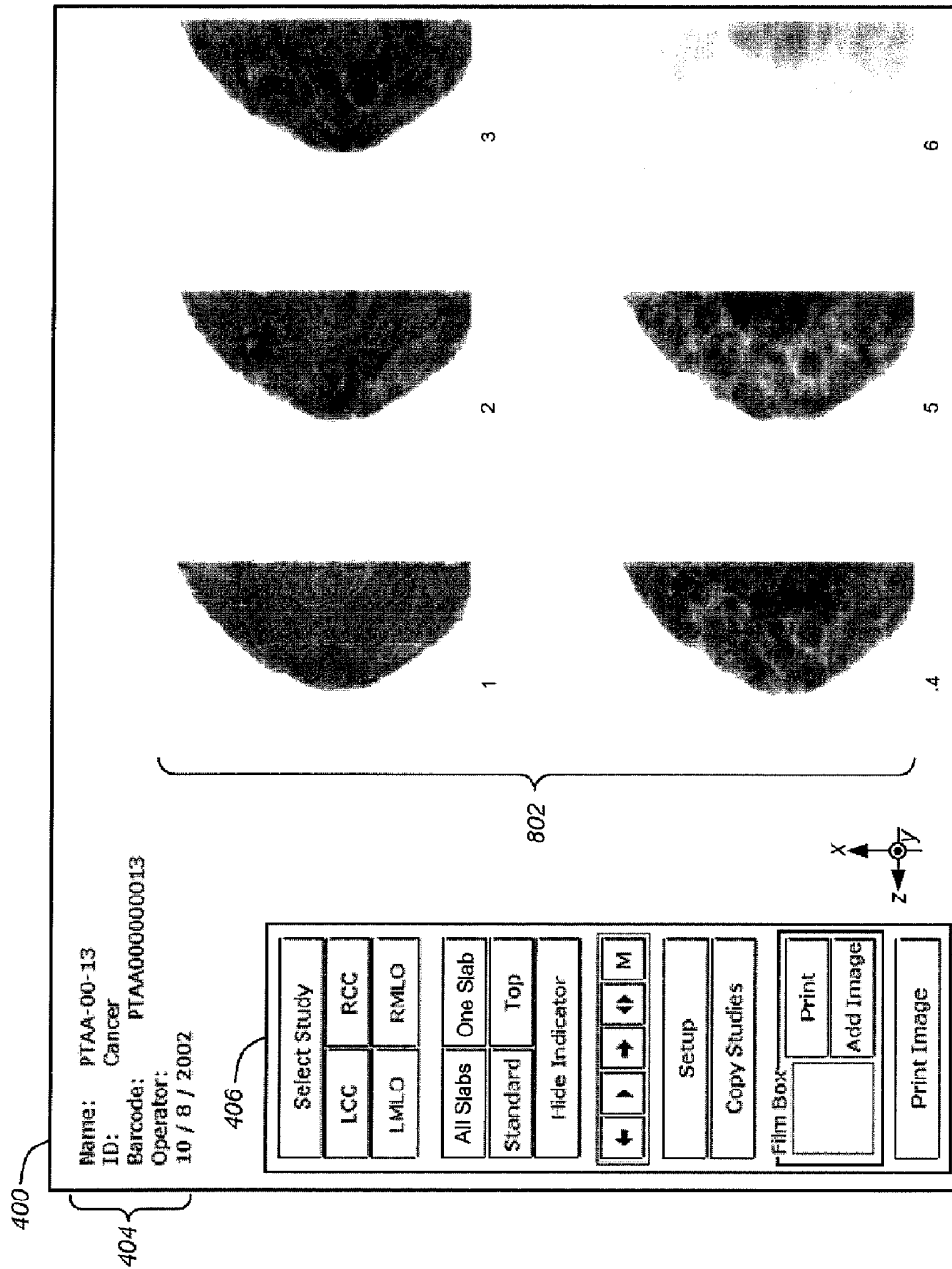
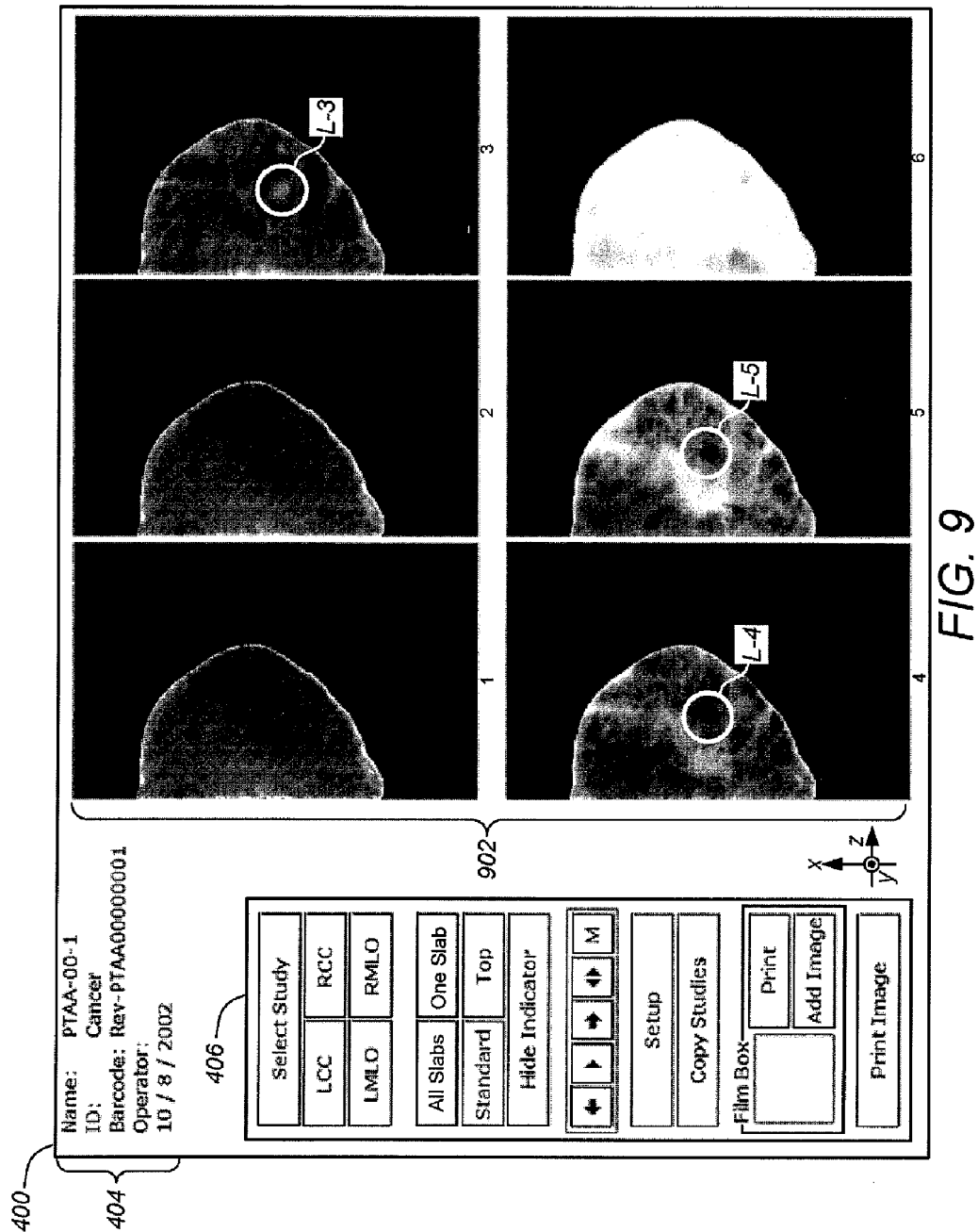


FIG. 8



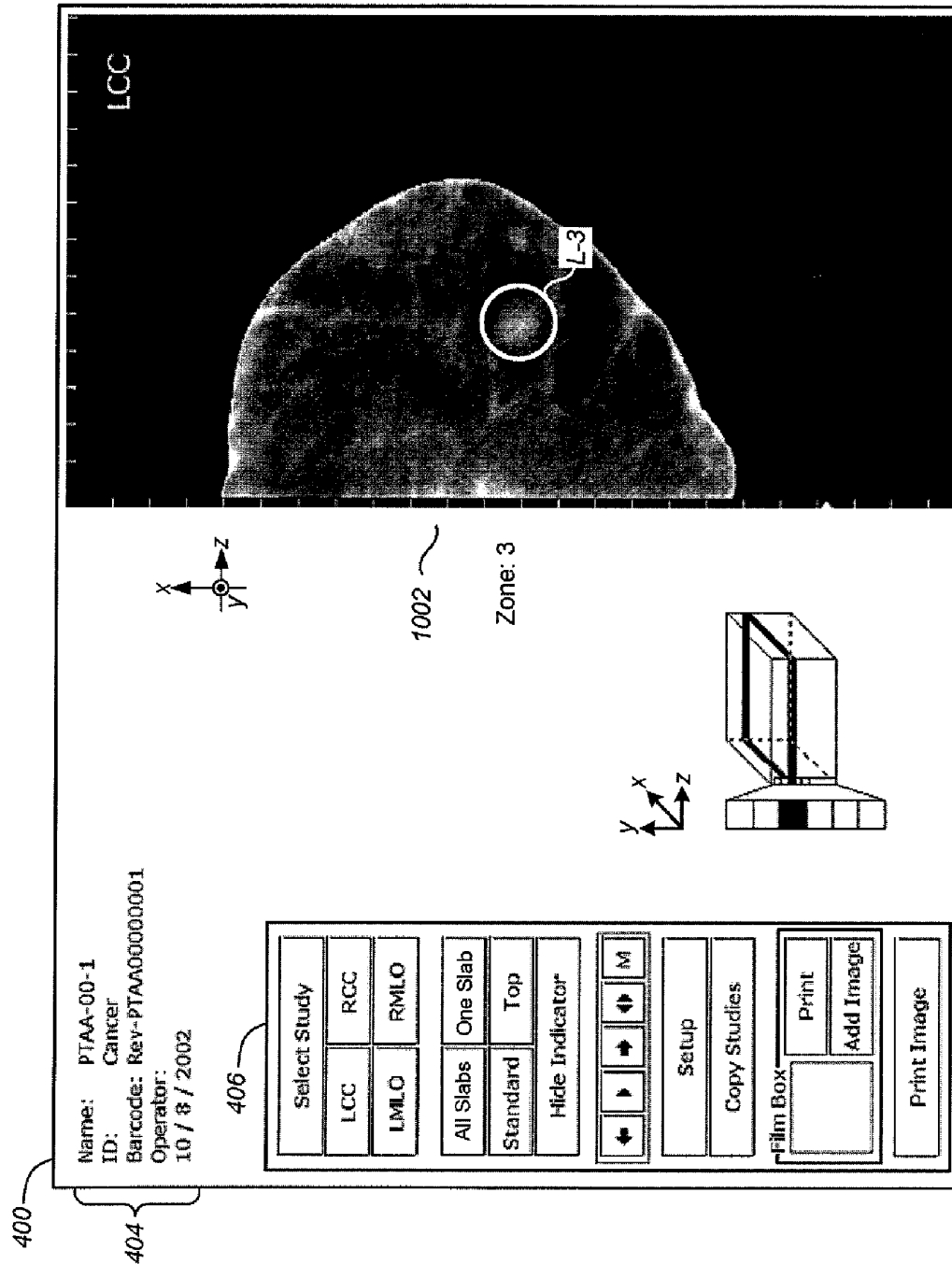


FIG. 10

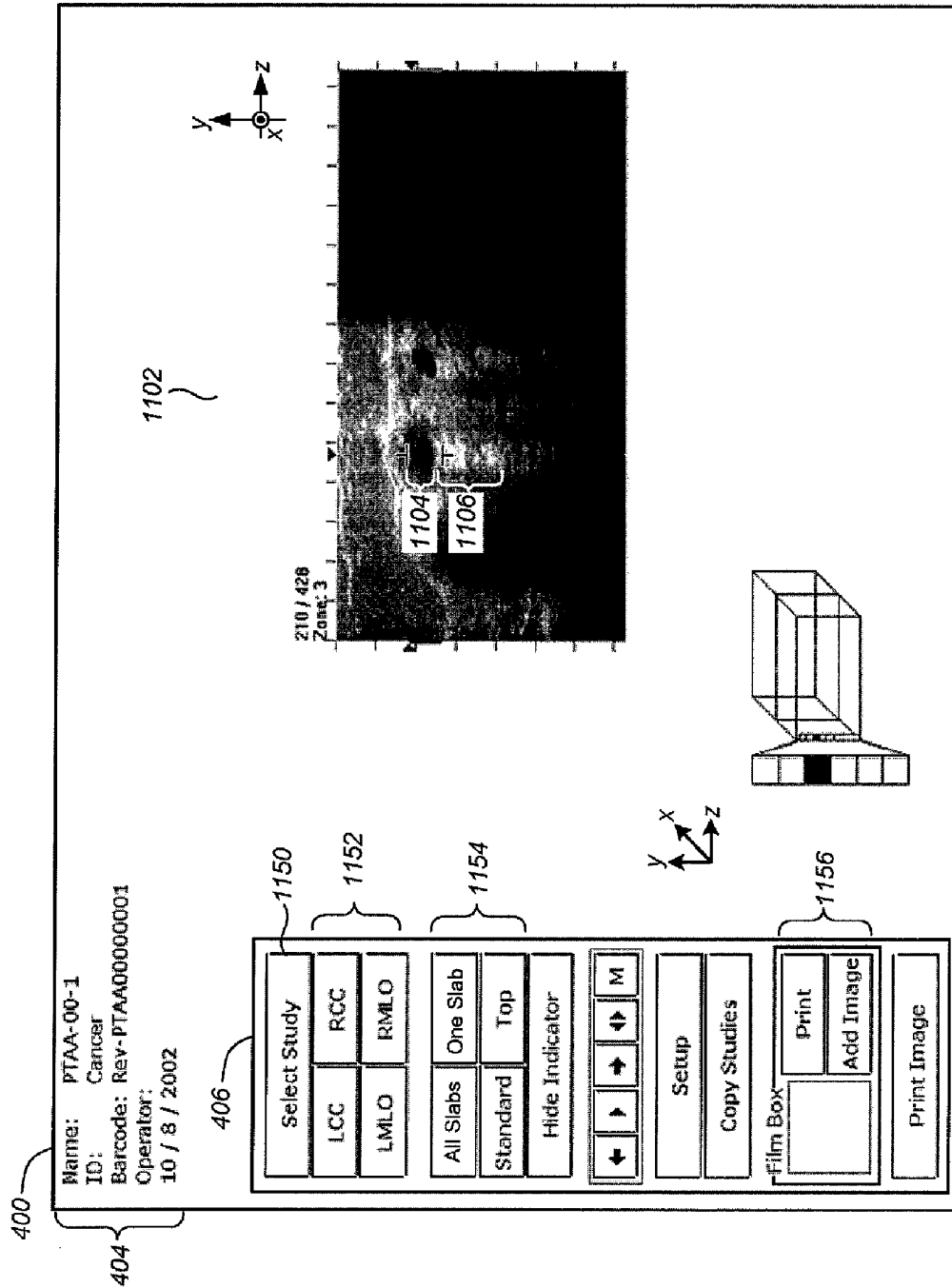


FIG. 11

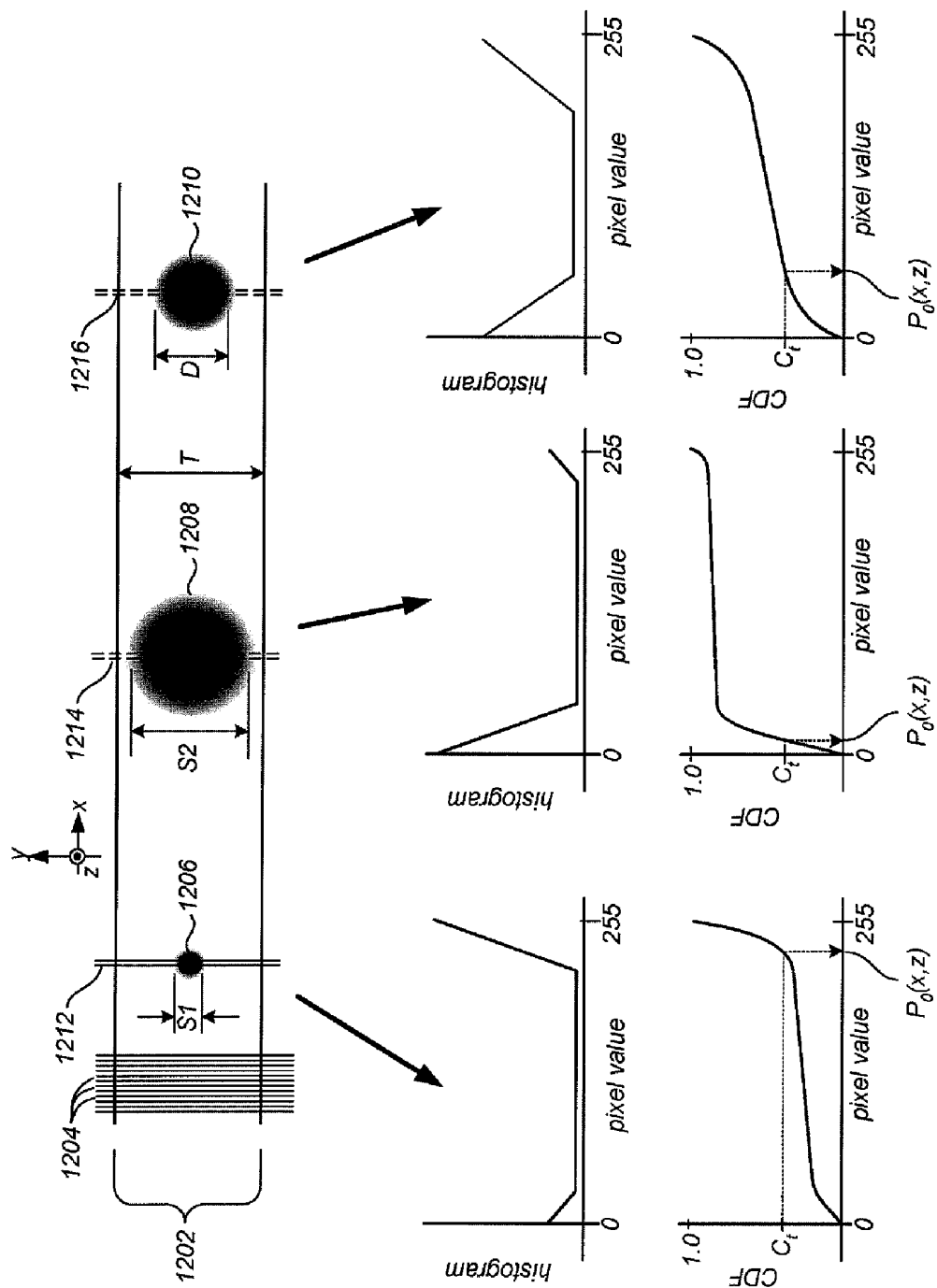


FIG. 12A

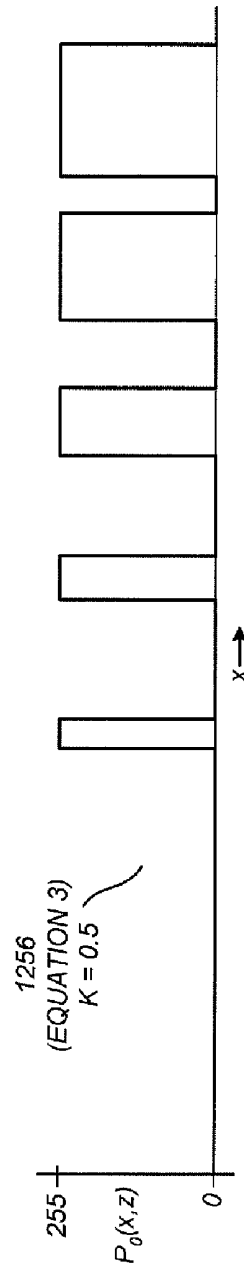
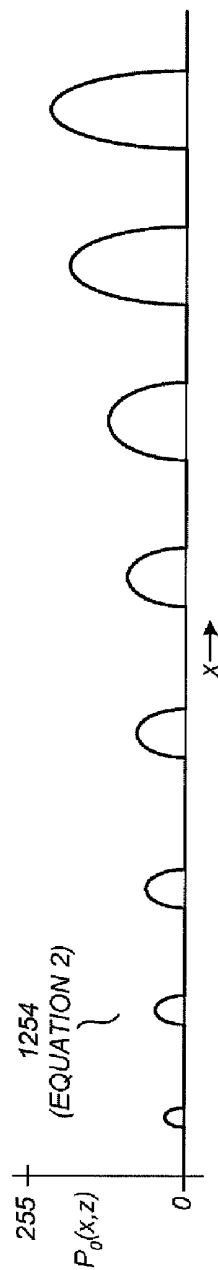
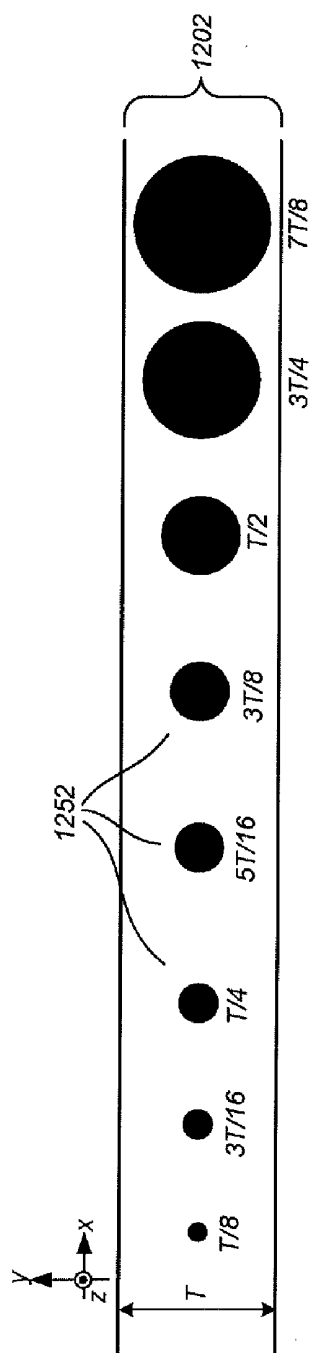


FIG. 12B

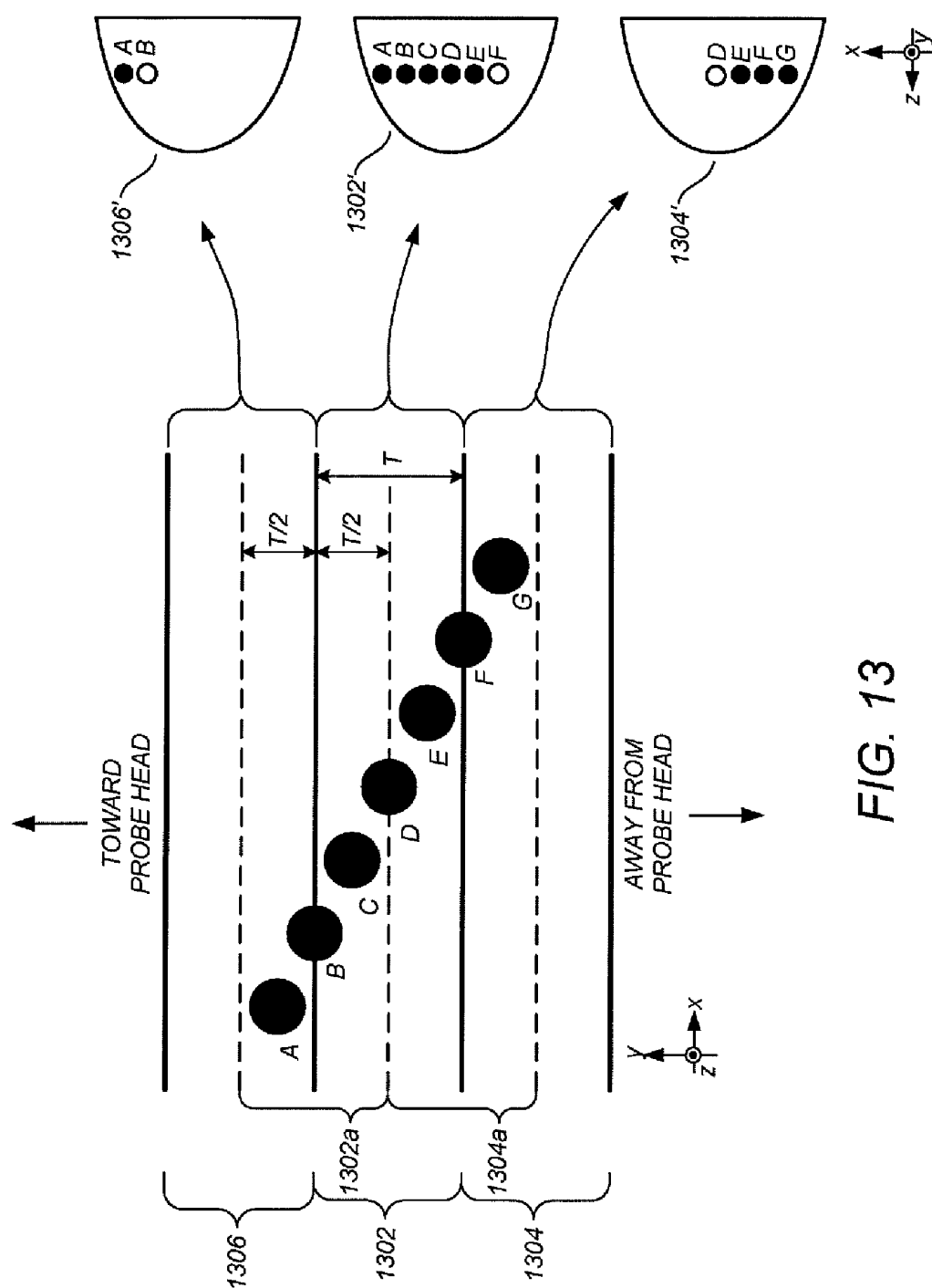


FIG. 13

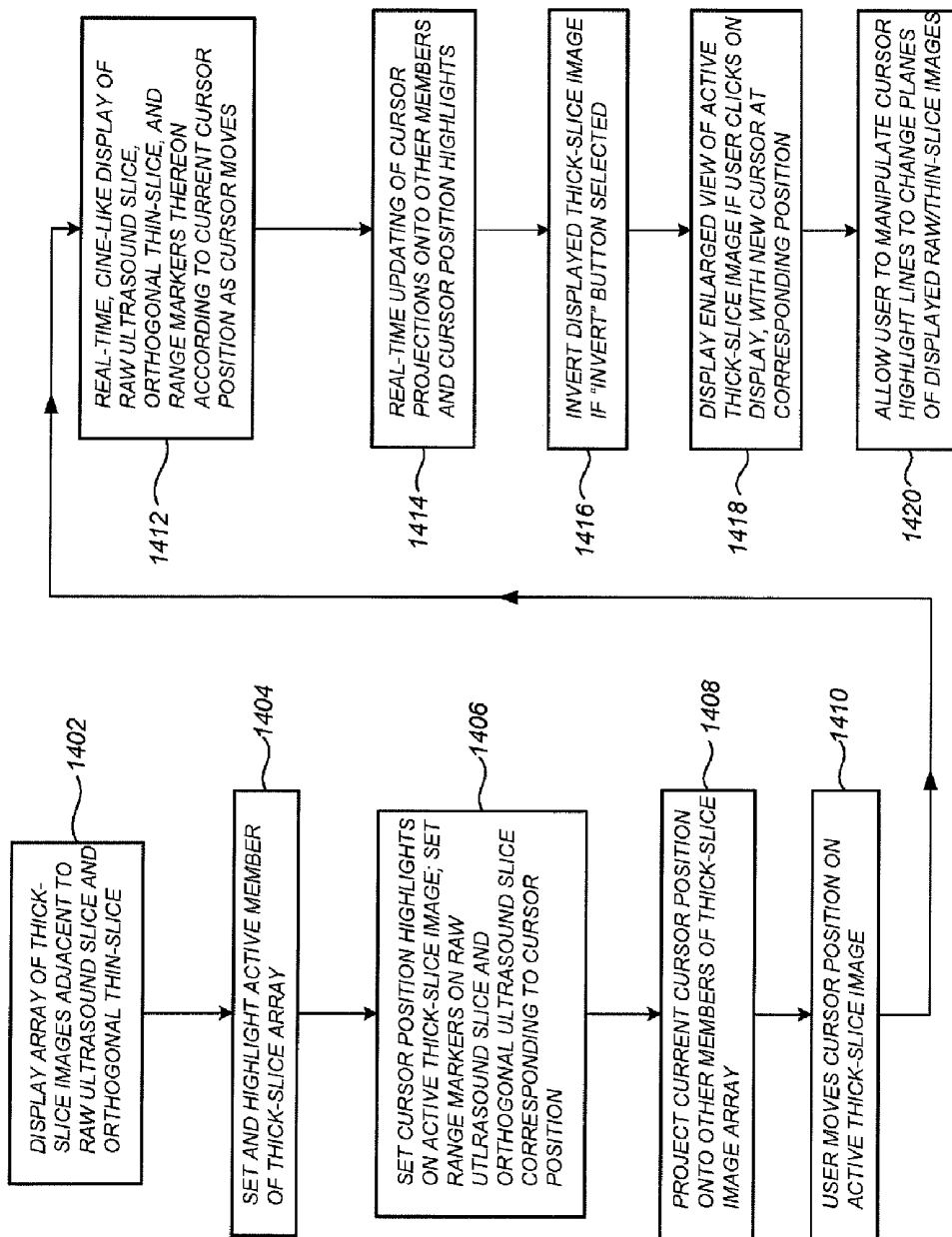
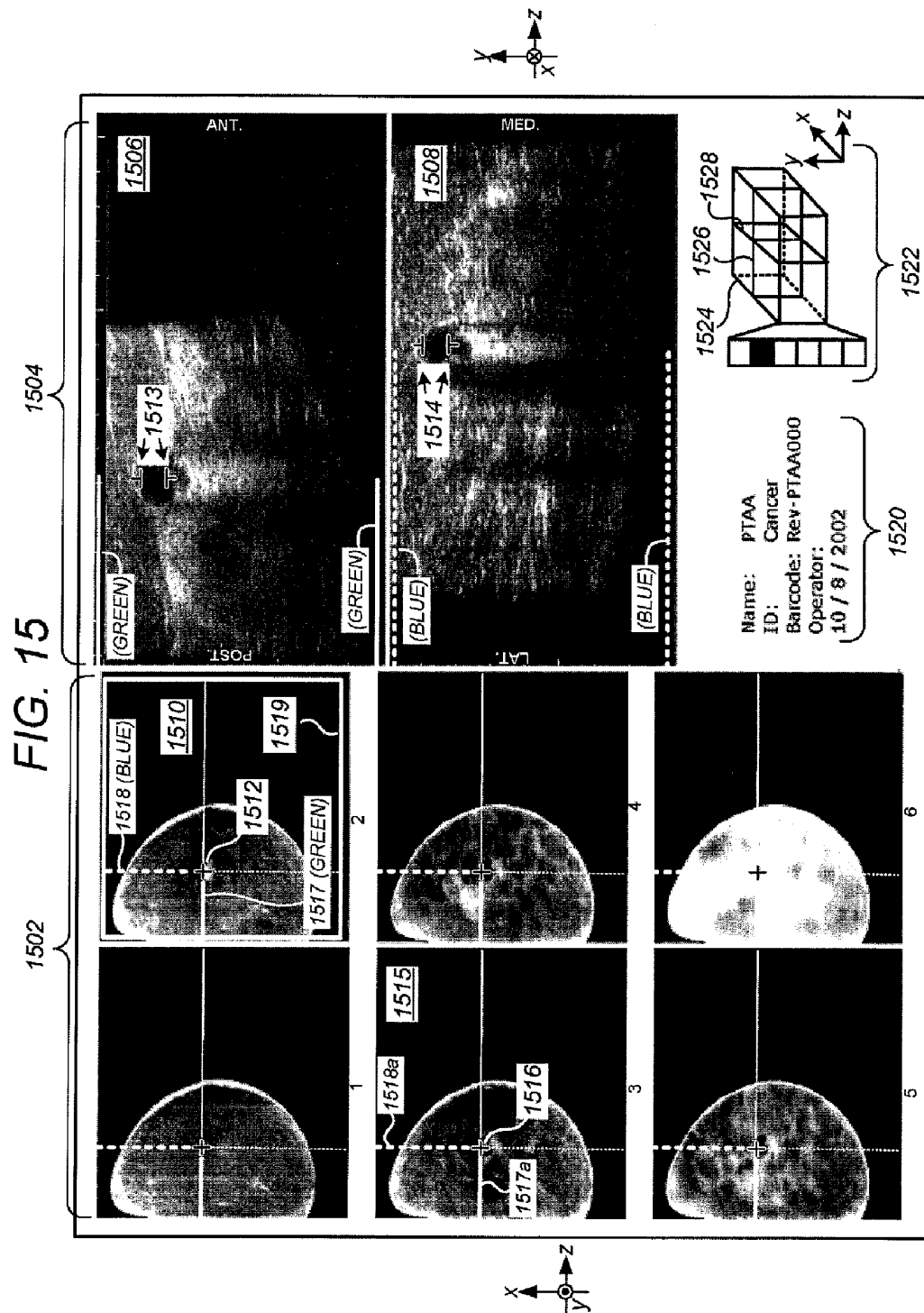
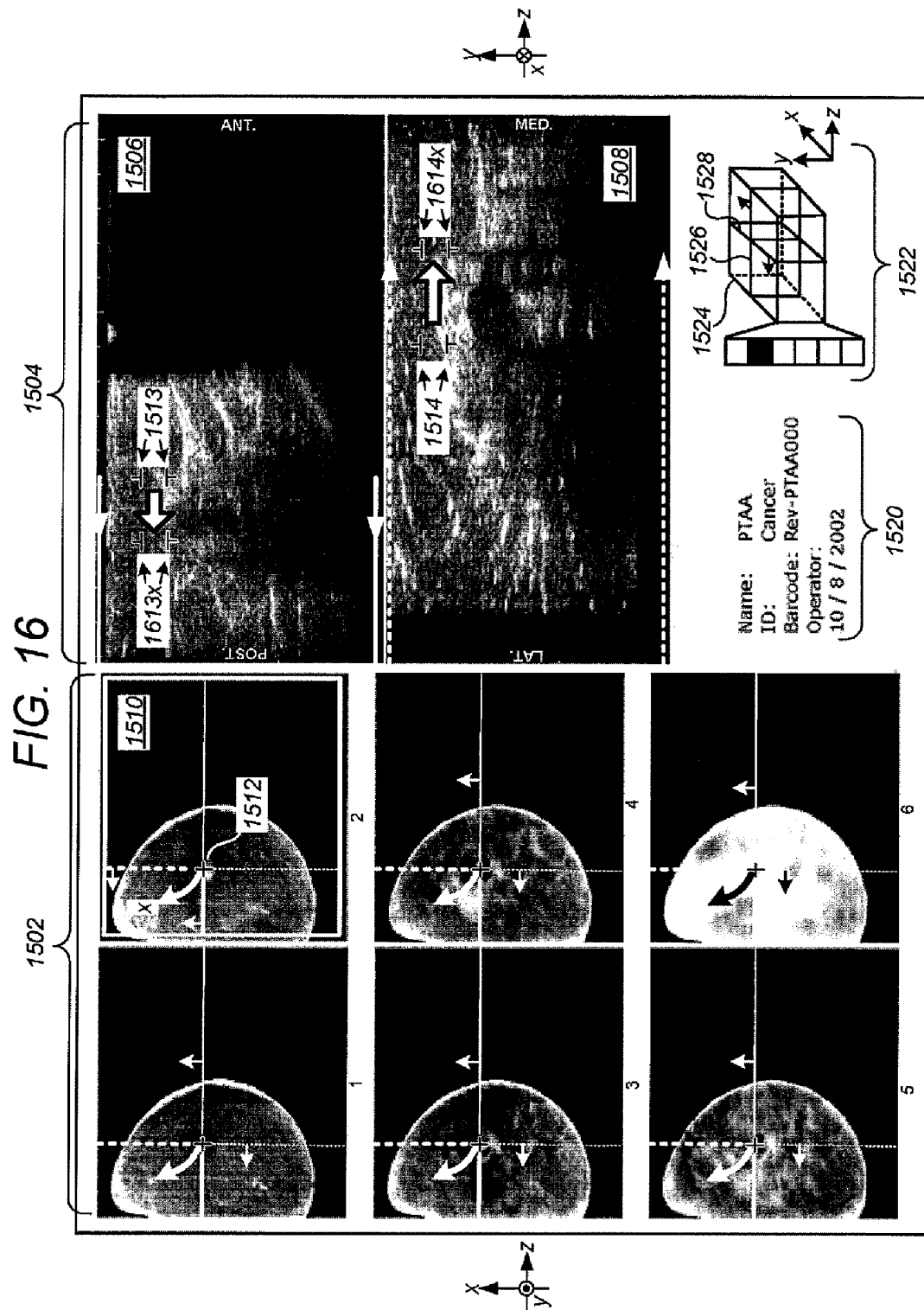
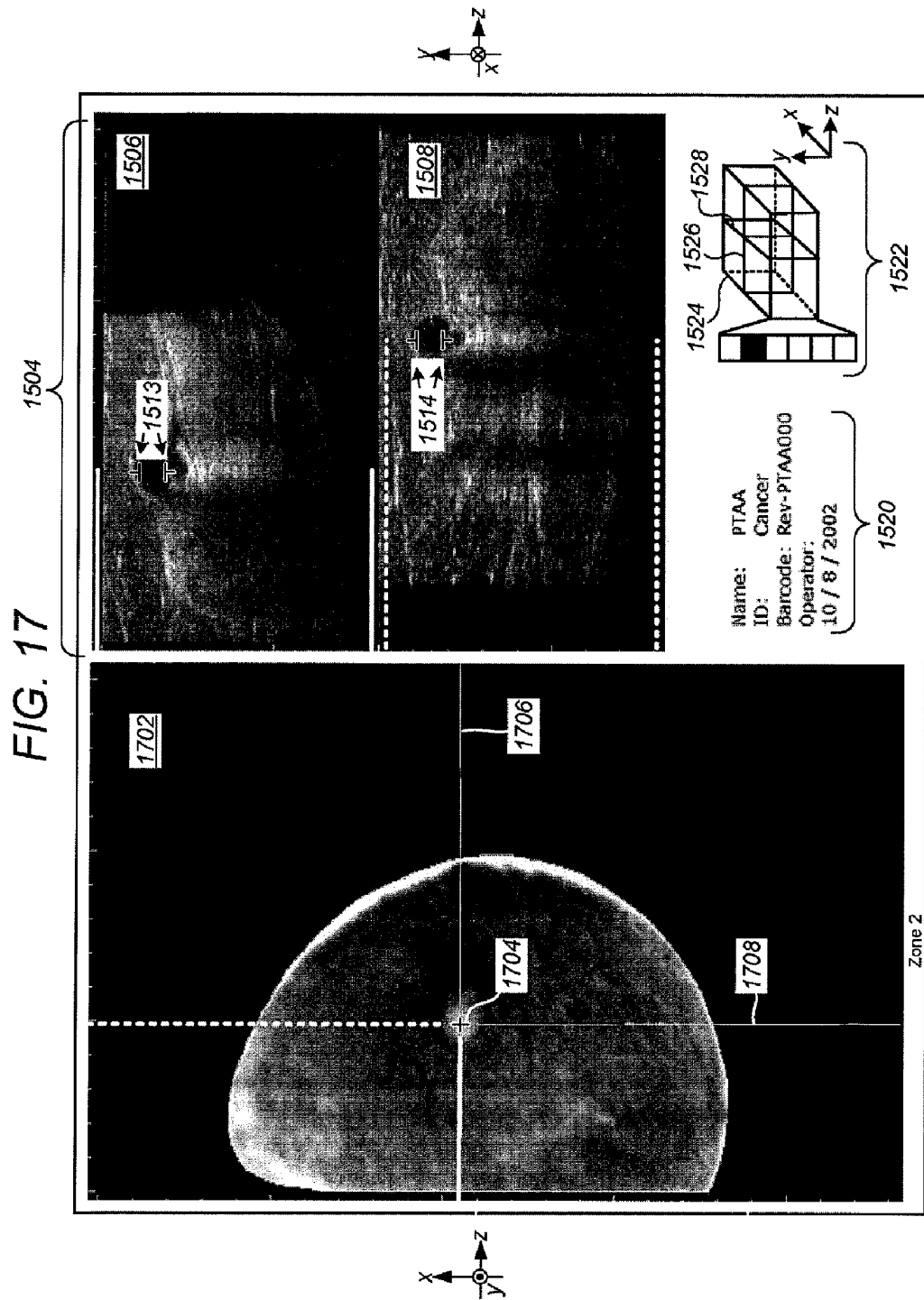


FIG. 14







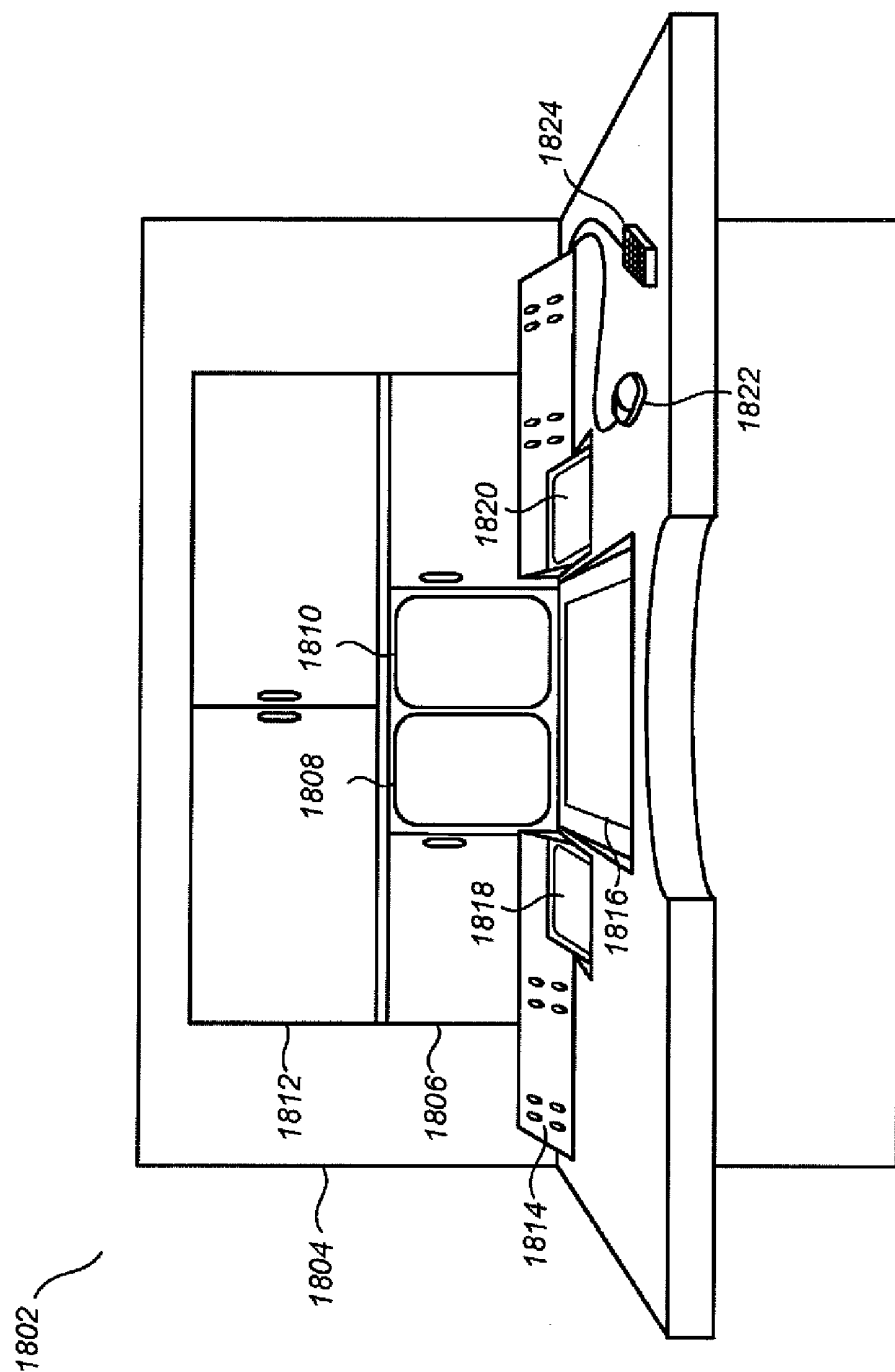


FIG. 18

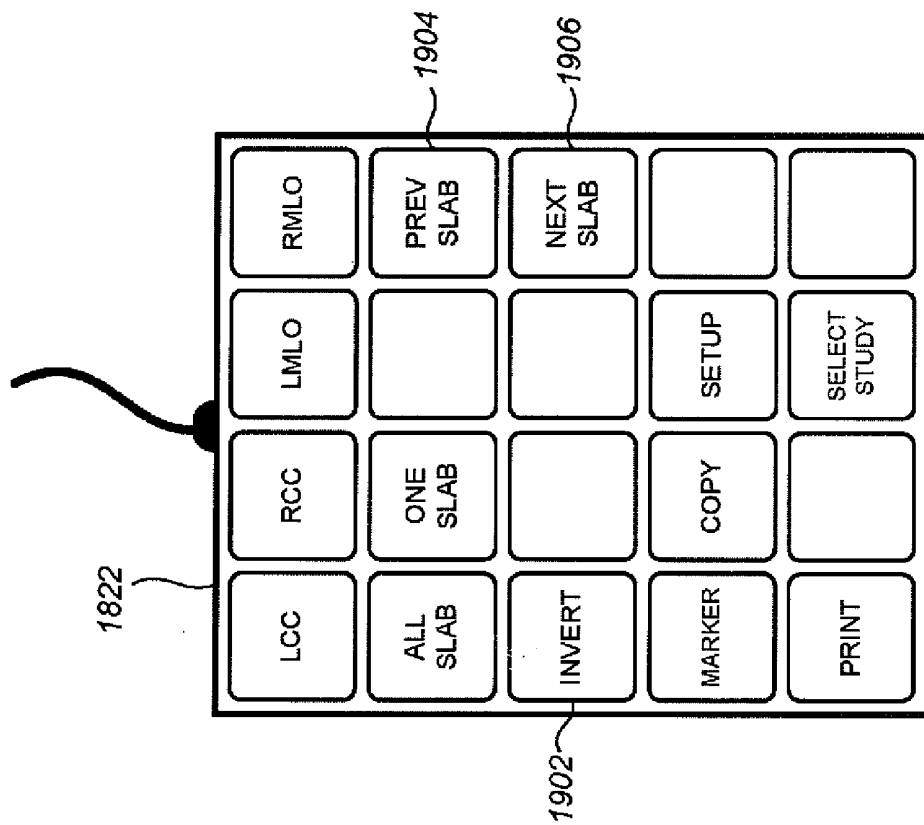


FIG. 19

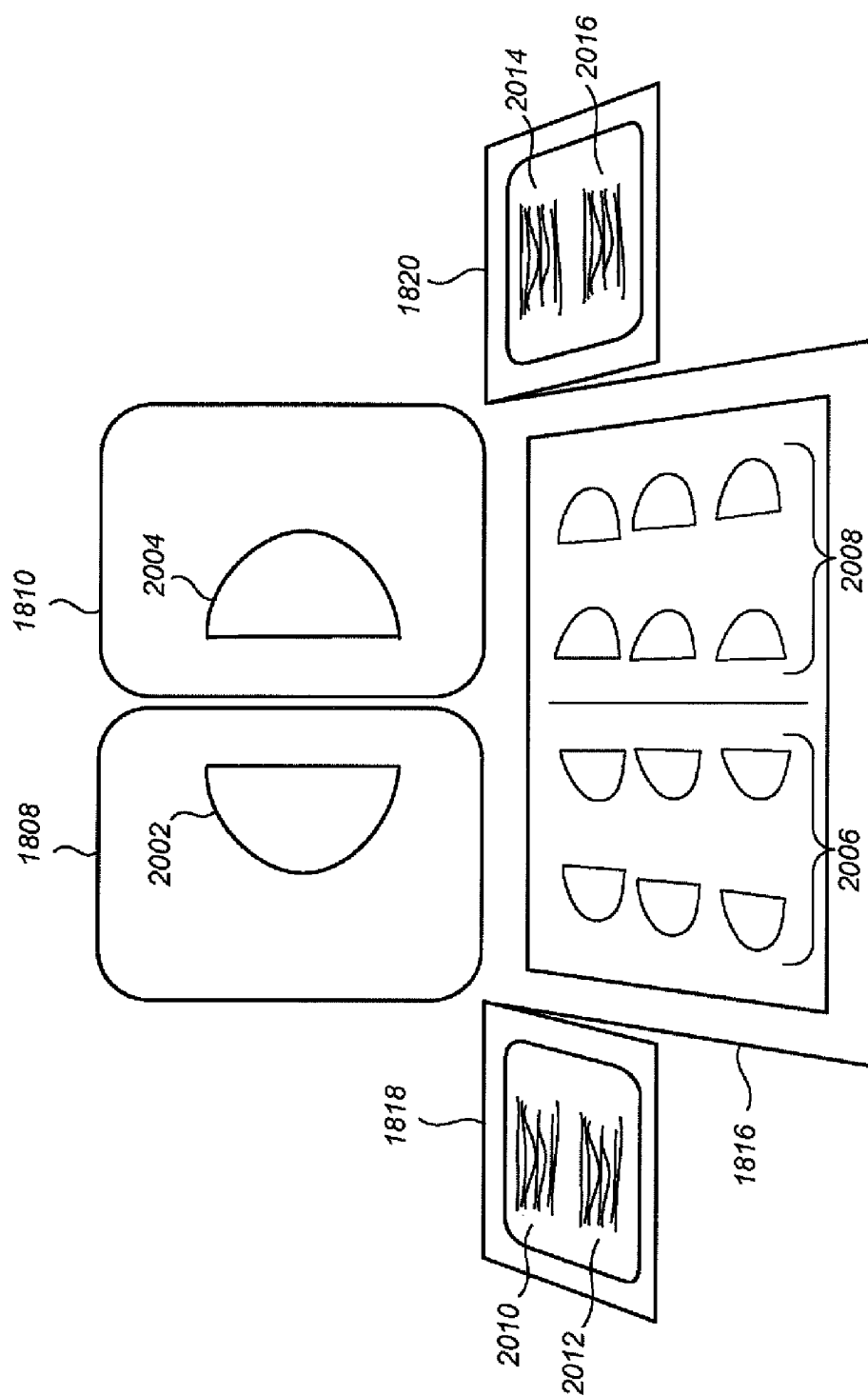


FIG. 20

ADJUNCTIVE ULTRASOUND PROCESSING AND DISPLAY FOR BREAST CANCER SCREENING

CROSS-REFERENCE TO RELATED APPLICATIONS

[0001] This application is a continuation-in-part of U.S. Ser. No. 10/160,836, filed May 31, 2002, which is a continuation-in-part of International Application Ser. No. PCT/US01/43237, filed Nov. 19, 2001, which claims the benefit of U.S. Provisional Application No. 60/252,946, filed Nov. 24, 2000, each of these applications being incorporated by reference herein. The above-mentioned Ser. No. 10/160,836 also claims the benefit of Provisional Application No. 60/326,715, filed Oct. 3, 2001, which is incorporated by reference herein. This application also claims the benefit of Provisional Application No. 60/415,385, filed Oct. 1, 2002. The subject matter of the present application is related to the subject matter of Ser. No. ____ [Atty. Dkt. No. 2692163685-PCT-B] filed the same day as the present application, which is incorporated by reference herein.

FIELD

[0002] This patent specification relates to medical imaging systems and processes. In particular, the present invention relates to the processing and display of breast ultrasound information in a manner that efficiently and intuitively complements traditional x-ray mammogram-based breast cancer screening methods.

BACKGROUND

[0003] Breast cancer is the most common cancer among women other than skin cancer, and is the second leading cause of cancer death in women after lung cancer. The American Cancer Society currently estimates that there are about 203,500 new invasive cases of breast cancer per year among women in the United States and 39,600 deaths per year from the disease. Prevention and early diagnosis of breast cancer are of foremost importance. Because early breast cancer does not produce symptoms, the American Cancer Society recommends a screening mammogram and a clinical breast examination every year for women over the age of 40.

[0004] X-ray mammography is currently the only imaging method for mass screening of breast cancer. In health maintenance organizations (HMOs) and other medical organizations, specialized x-ray mammography clinics designed for high patient throughput are being increasingly used to screen as many women as possible in a time and cost efficient manner. Numerous studies have shown that early detection saves lives and increases treatment options. Recent declines in breast cancer mortality rates (e.g., 39,600 deaths in 2002 versus 41,200 in 2000) have been attributed, in large part, to the regular use of screening x-ray mammography.

[0005] It has been found that the use of ultrasound mammography (sonomammography) in conjunction with conventional x-ray mammography can drastically increase the early breast cancer detection rate. Whereas x-ray mammograms only detect a summation of the x-ray opacity of individual slices over the entire breast, ultrasound can separately detect the acoustic impedance of individual slices of breast tissue, and therefore may allow detection of breast lesions where x-ray mammography alone fails.

[0006] However, as discussed in Ser. No. 10/160,836, supra, despite strong evidence that use of independent ultrasound examination would improve early breast cancer detection and therefore save lives, substantial resistance against such use currently exists in the medical industry, including the radiologists themselves, and among policymakers. As used herein, the term "radiologist" generically refers to a medical professional that analyzes medical images and makes clinical determinations therefrom, it being understood that such person might be titled differently, or might have differing qualifications, depending on the country or locality of their particular medical environment. Several interrelated factors are often cited, including: (i) the false negative (missing) rate of independent ultrasound examination is unknown, (ii) the false positive rate of independent ultrasound examination is known to be very high, leading to an increase in unneeded patient callbacks and biopsies, (iii) lack of image acquisition standardization, leading to variability among different operators and radiologists, (iv) the additional time and equipment required to conduct the ultrasound examination, leading to an increase in cost, (v) most if not all radiologists are not trained to read screening ultrasound images, which contain features not found in current breast imaging textbooks or taught in current medical school courses, leading to a potential increase in false negative (missing) rate and in the additional radiologist time required to analyze the ultrasound images, and (vi) the additional training and clinical experience that would be required for the radiologist to properly analyze the ultrasound images.

[0007] Various schemes have been proposed for processing and presenting breast ultrasound information in conjunction with x-ray mammogram information for use in breast cancer detection environments. In U.S. Pat. No. 5,938,613, which is incorporated by reference herein, a method and apparatus for performing sonomammography and enhanced x-ray imaging is discussed in which ultrasound equipment is integrated with mammography equipment to generate ultrasonic images of the breast that are in geometric registration with an x-ray mammogram. An x-ray mammogram image of an immobilized breast is acquired and, while the breast is still immobilized, an ultrasound scan is acquired using an automated ultrasound probe translation mechanism. Cross-sectional ultrasonic slices are summed across the entire breast to form a two-dimensional ultrasound image, which is then overlaid onto the digitized x-ray image for viewing by the radiologist. Precise geometric registration between the ultrasound image and the x-ray mammogram is automatically provided because the breast is immobilized between imaging procedures and because the coordinates of the ultrasound probe are known during each scan. The radiologist is permitted to instantiate certain algorithms such as digital subtraction between the registered medical images.

[0008] However, the '613 patent is deficient in several respects with respect to the practical, real-world factors associated with the current resistance against the use of ultrasound in mass breast cancer screening environments. For example, the large base of currently installed x-ray imaging systems would require substantial retooling to accommodate the mechanical apparatus of the '613 patent that keeps the breast immobilized between imaging procedures and that performs the automated ultrasound scans. As another example, by displaying a summation ultrasound image of all breast slices together, the '613 method deprives the radiologist of the ability to view individual planes inside the breast. More gen-

erally, the computer-registered, static overlay of the summation ultrasound image onto the x-ray image affords only a limited amount of ultrasonic information to the radiologist as compared to the actual amount of ultrasonic data actually acquired, and affords only limited perception by the radiologist of structures within the breast.

[0009] In U.S. Pat. No. 5,662,109, a method and system for multi-dimensional imaging and analysis for early detection of diseased tissue is discussed. Ultrasound scans of a breast are processed into multiple layers of two-dimensional images, thus yielding a three-dimensional data set. This data set and a two-dimensional x-ray mammogram are input to an enhancer that performs one or more "data fusion" algorithms to generate a three-dimensional representation of the breast for viewing. The enhancer includes a registration module that expands and/or reduces dimensions of the data to register and align the ultrasound and mammographic images.

[0010] However, it is not believed that the various three-dimensional views of the "fused" data discussed in the '109 patent, such as the perspective view shown in FIG. 1 thereof, would be useful to a typical radiologist trained in conventional x-ray mammography methods. As described supra, radiologists typically spend many years developing expertise in analyzing a very particular set of two-dimensional x-ray mammographic data taken from standardized views, most commonly the craniocaudal (CC) and mediolateral oblique (MLO) views. It is believed that most radiologists would be reluctant to "start over again" with an entirely new, different way of viewing the complex structures of a breast, and that the medical industry would likewise be reluctant to force radiologists to accept these viewing methods.

[0011] In view of the above discussions, it would be desirable to provide an adjunctive ultrasound mammography system that integrates ultrasound mammography into current breast cancer screening methodologies.

[0012] It would be further desirable to provide an adjunctive ultrasound mammography system that displays breast ultrasound information in a manner that facilitates the radiologist's perception of internal breast structures that may not be readily apparent in an x-ray mammogram, while also being able to confirm the radiologist's perception of internal breast structures that are apparent in the x-ray mammogram.

[0013] It would be even further desirable to provide an adjunctive ultrasound mammography system that displays breast ultrasound information in a manner that supplements, rather than replaces, conventional x-ray mammogram viewing methods, thereby increasing the likelihood of adoption by both individual radiologists and the medical industry.

[0014] It would be even further desirable to provide an adjunctive ultrasound mammography system that takes little or no special familiarization or training from the radiologist in order to effectively view breast ultrasound information.

[0015] It would be still further desirable to provide an interactive user interface for an adjunctive ultrasound mammography system that allows the radiologist to quickly and intuitively navigate among different representations of the breast ultrasound information.

[0016] It would be even further desirable to display such breast ultrasound information in a manner that allows benign features to be more easily dismissed by the viewing radiologist.

SUMMARY

[0017] An adjunctive ultrasound mammography system and associated methods are provided including an intuitive,

interactive user interface for displaying breast ultrasound information to a user. According to a preferred embodiment, an array of thick-slice images derived from volumetric ultrasound scans of a breast is displayed, each thick-slice image representing a thick-slice or slab-like region of the breast volume substantially parallel to a standard x-ray mammogram view of the breast. Responsive to a first single-click or single-movement user selection of a first point on one of the thick-slice images, an enlarged view of that thick-slice image is displayed with a cursor positioned at a corresponding point. Responsive to a second single-movement user selection of a second point on the enlarged view, a first planar ultrasound image encompassing the second point is displayed, the first planar ultrasound image representing the volumetric ultrasound scans along a first plane substantially nonparallel to, and preferably perpendicular to, the orientation of the slab-like region for that thick-slice image.

[0018] According to another preferred embodiment, a second planar ultrasound image is shown concurrently with the first planar ultrasound image representing the volumetric scans along a second plane substantially orthogonal to both the first plane and to the orientation of the slab-like region. According to another preferred embodiment the first and second planar ultrasound images are displayed concurrently with the enlarged thick-slice image or the array of thick-slice images. The first and second planes correspond to the current cursor position on an active one of the thick-slice images and are updated in real time as the cursor is moved. Range markers are provided on the planar ultrasound images corresponding to the current cursor position and to the borders of the slab-like region for the active thick-slice image.

[0019] According to another preferred embodiment, first and second plane indicators are displayed on the active thick-slice image, the plane indicators corresponding to the first and second planes and appearing as straight lines for a default configuration in which the first and second planes are orthogonal to each other and to the orientation of the slab-like region for the active thick-slice image. In the default configuration, the first and second plane indicators intersect the cursor on the active thick-slice image. The user is permitted to depart from the default configuration if desired by moving the first and second plane indicators in a manner analogous to the way lines are moved in a computer-aided drawing system, while the first and second planes and the first and second planar ultrasound images are updated in real time to correspond to the orientations and locations of the first and second plane indicators.

[0020] A user interface according to the preferred embodiments is preferably provided in conjunction with an x-ray mammogram viewer such that the array of thick-slice ultrasound images is displayed in coordination with a corresponding x-ray mammogram image taken from the same standard x-ray mammogram view. The x-ray mammogram image, which is preferably provided on a backlighted film display but which can alternatively be provided on an electronic display, is displayed in close proximity to the array of thick-slice ultrasound images to allow easy back-and-forth viewing. Preferably, the thick-slice images are displayed at full scale on an LCD monitor positioned directly below the x-ray mammogram images, while the first and second planar ultrasound images are displayed on smaller CRT displays positioned to the sides of the LCD monitor. However, a variety of different

configurations having differing advantages are within the scope of the preferred embodiments as described further infra.

[0021] According to one preferred embodiment, the displayed thick-slice images are inverted to represent high acoustic reflections as “dark” and low acoustic reflections as “bright,” in distinction to a standard ultrasound display convention in which low acoustic reflections are displayed as “dark” and high acoustic reflections are displayed as “bright.” Preferably, the breast area is digitally segmented from the surrounding area, and the surrounding area is reset to “dark” prior to display of the inverted thick-slice image. The inverted thick-slice images are of more familiar significance to radiologists having years of expertise in analyzing conventional x-ray mammograms. For example, the inverted thick-slice images allow benign features to be more easily dismissed as compared to non-inverted thick-slice images.

[0022] According to another preferred embodiment, a method for computing the thick-slice images from the volumetric ultrasound representation of the breast is provided, each thick-slice image pixel being computed based on the statistics of a voxel column passing through that location from a lower border to an upper border of the relevant slab-like region. In particular, the statistical properties of interest are ones that incur changes across different pixel locations in mass localities that are more significant for masses greater than a preselected size of interest and that are less significant for smaller masses. Accordingly, mass lesions greater than the preselected size of interest are emphasized while smaller mass lesions are de-emphasized in the resulting thick-slice image. In one preferred embodiment, the thick-slice pixel value is selected as that value for which a cumulative distribution function (CDF) of the voxel column becomes equal to a threshold value, the threshold value being a predetermined fraction of a ratio of the preselected size of interest to the distance between the first and second border planes. A method for ensuring the visibility of lesions straddling the borders between adjacent thick-slice regions is also provided in which (i) an actual result for the actual thick-slice region is computed, (ii) a hypothetical result is computed for a hypothetical thick-slice region that is partially elevated into the adjacent thick-slice region, and (iii) resetting the actual result to the hypothetical result if the hypothetical result is more indicative of lesser ultrasound reflections.

BRIEF DESCRIPTION OF THE DRAWINGS

[0023] FIG. 1 illustrates a conceptual diagram of a system and method for breast cancer screening using adjunctive ultrasound mammography according to a preferred embodiment;

[0024] FIG. 2 illustrates steps for breast cancer screening using adjunctive ultrasound mammography according to a preferred embodiment;

[0025] FIG. 3 illustrates steps for interactively displaying adjunctive ultrasound mammography information to a user according to a preferred embodiment;

[0026] FIG. 4 illustrates an adjunct ultrasound display according to a preferred embodiment presenting an array of inverted thick-slice images;

[0027] FIG. 5 illustrates an adjunct ultrasound display according to a preferred embodiment presenting an enlarged inverted thick-slice image;

[0028] FIG. 6 illustrates an adjunct ultrasound display according to a preferred embodiment presenting a planar ultrasound image;

[0029] FIG. 7 illustrates an adjunct ultrasound display according to a preferred embodiment presenting an array of non-inverted thick-slice images for the same breast illustrated in FIG. 4;

[0030] FIG. 8 illustrates an adjunct ultrasound display according to a preferred embodiment presenting an array of inverted but non-segmented thick-slice images for the same breast as FIGS. 4 and 7;

[0031] FIG. 9 illustrates an adjunct ultrasound display according to a preferred embodiment presenting an array of inverted thick-slice images;

[0032] FIG. 10 illustrates an adjunct ultrasound display according to a preferred embodiment presenting an enlarged inverted thick-slice image;

[0033] FIG. 11 illustrates an adjunct ultrasound display according to a preferred embodiment presenting a raw ultrasound image;

[0034] FIG. 12A illustrates a conceptual view of a thick-slice region and lesions contained therein, along with related histograms and cumulative distribution functions;

[0035] FIG. 12 B illustrates a conceptual view of a thick-slice region and lesions contained therein, along with plots of thick-slice image values along a single line in the thick-slice image resulting from thick-slice image computation algorithms according to preferred embodiments;

[0036] FIG. 13 illustrates a conceptual frontal view of a set of neighboring thick-slice region and lesions contained therein, along with conceptual thick-slice images;

[0037] FIG. 14 illustrates steps for interactively displaying adjunctive ultrasound mammography information to a user according to a preferred embodiment;

[0038] FIG. 15 illustrates an adjunct ultrasound display according to a preferred embodiment presenting an array of inverted thick-slice images and two planar ultrasound images;

[0039] FIG. 16 illustrates the adjunct ultrasound display of FIG. 15 when a user moves the cursor on a selected thick-slice image;

[0040] FIG. 17 illustrates an adjunct ultrasound display according to a preferred embodiment comprising an enlarged inverted thick-slice image and two planar ultrasound images;

[0041] FIG. 18 illustrates an exterior view of an adjunctive ultrasound mammography display unit according to a preferred embodiment;

[0042] FIG. 19 illustrates a keypad for the adjunctive ultrasound mammography display unit of FIG. 18; and

[0043] FIG. 20 illustrates a closer view of display portions of the adjunctive ultrasound mammography display unit of FIG. 18.

DETAILED DESCRIPTION

[0044] FIG. 1 illustrates a conceptual diagram of a system **100** and associated methods for breast cancer screening using adjunctive ultrasound mammography according to a preferred embodiment. Adjunctive ultrasound mammography refers to the acquisition and display of breast ultrasound information during the breast cancer screening process in a manner that supplements x-ray mammogram information. System **100** comprises an ultrasound scanning station **102**, a computer network **104**, an adjunctive ultrasound server **106**, and an adjunctive ultrasound screening station **108**.

[0045] Ultrasound scanning station **102** comprises an apparatus designed to flatten and immobilize a breast while volumetric ultrasound scans are acquired. The breast is flattened along a plane substantially parallel to a standard x-ray mammogram view plane such as the CC and MLO view planes, although the ultrasound scanning station **102** is capable of flattening the breast along a variety of other planes as well. Ultrasound scanning station **102** comprises a housing **110** movably supporting a gantry **114**, the gantry **114** in turn supporting an upper compression/scanning assembly **112** and a lower compression plate **113** in a vertically movable manner.

[0046] For clarity of description herein, the y direction represents the head-to-toe direction with respect to the patient, the x-axis represents the left-to-right direction, and the z direction extends outward from the chest wall. The x-y, y-z, and x-z planes thus correspond to the coronal, sagittal, and axial planes, respectively. The patient may stand or sit in front of the ultrasound scanning station **102**, facing the +z direction in FIG. 1, with one breast placed between the upper compression/scanning assembly **112** and lower compression plate **113**. Responsive to control by an operator using foot pedals **115**, a keyboard **118**, a mouse **117**, buttons on the gantry **114**, and/or other input methods, the breast is compressed and an ultrasound probe head (not shown) contained inside upper compression/scanning assembly **112** is linearly translated over the top of the breast while two-dimensional ultrasound slices are acquired. Ultrasound scanning station **102** further comprises an ultrasound processor (not shown) coupled to the ultrasound probe head that receives the acoustic echo signals and forms the two-dimensional ultrasound slices therefrom. The ultrasound slices may be viewed in real-time on a monitor **116** as they are generated, the monitor **116** also serving as an interface display for controlling of the overall operation of the ultrasound scanning station **102**.

[0047] Preferably, the upper compression/scanning assembly **112** is similar to that described in Ser. No. 60/415,385, supra. The breast skin surface contacts one side of a taut sheet of acoustically transparent material such as Mylar® while the other side of the taut sheet is in actual or imminent contact with the probe head. Acoustic coupling between the taut sheet and the probe head is facilitated by a stream, drip, or bath of water or other low-viscosity, acoustically conductive fluid. The gantry **114** is rotatable in a plane parallel to the coronal plane of the patient, i.e., around the z-axis in FIG. 1, such that scans of the breast flattened along the MLO plane or other view planes can be achieved. The gantry **114** can also be tilted forward or backward relative to the patient, i.e., around the x-axis in FIG. 1, between a range of roughly plus 30 degrees to minus 30 degrees.

[0048] According to one preferred embodiment, a breast scan for a given view is acquired by a single sweep of the probe contained within upper compression/scanning assembly **112**. In this case, it is required that the scan penetration depth extend as far as possible toward the lower compression plate. For larger breasts, this can be 6 cm or greater, in which case a lower probe frequency is required and a correspondingly lesser resolution is obtained than for high-frequency scans. According to another preferred embodiment, dual sweeps can be taken for a given view, with the gantry being rotated 180 degrees around the y-axis in FIG. 1 between sweeps. In this case, the scans only need to penetrate through half the breast thickness and so a higher scan frequency can be used. The resulting ultrasound “half-slices” from the first and

second sweeps can then be stitched together to form complete slices. In still another preferred embodiment, the lower compression plate **113** is replaced with a second compression/scanning assembly including a second probe head. In this case the separate upper and lower probe sweeps can be achieved without requiring the intermediate 180 degree rotation of the gantry, and issues relating to registration between the half-slices are avoided.

[0049] During or after the ultrasound scanning process, the raw ultrasound data is provided across the computer network **104** to the adjunctive ultrasound server **106**, where the raw ultrasound data is processed into adjunctive ultrasound data that will be made available to the screening radiologist, the adjunctive ultrasound data including ultrasound slices, thick-slice images, CAD outputs, and other useful information. It is to be appreciated that the processing of the raw ultrasound data into the adjunctive ultrasound data may be performed by any of a variety of different computing devices coupled to the computer network **104** and then transferred to the adjunctive ultrasound server **106**.

[0050] In current mass breast cancer screening environments based on x-ray mammography, a screening radiologist **124** examines x-ray mammograms for many patients en masse in a single session using an x-ray viewing station **109**. The x-ray viewing station **109** may range from a simple light box, as in FIG. 1, to more complex x-ray CAD workstations that automatically move the x-ray mammograms past the radiologist **124** on a conveyor belt as a nearby CAD display highlights suspicious areas of the mammogram. Almost universally, left and right CC x-ray views **120** are positioned on one side of the x-ray viewing station **109**, and left and right MLO x-ray views **122** are positioned on the other side. The radiologist **124** quickly examines the x-ray mammograms. For some x-ray mammograms the radiologist needs only a few seconds, while for other x-ray mammograms the radiologist needs up to five minutes, with an average being about two minutes per mammogram.

[0051] According to a preferred embodiment, this existing arrangement remains substantially undisturbed, but is augmented with equipment and data that facilitates fast and thorough x-ray mammogram screening by giving the radiologist a quick ultrasonic “second look” at the internal breast structure. Adjunctive ultrasound screening station **108** comprises first and second adjunct displays **126** and **128** conveniently positioned near the x-ray viewing station **109** such that the radiologist **124** can (i) easily look back and forth between the first adjunct display **126** and the CC x-ray views **120**, and (ii) easily look back and forth between the second adjunct display **128** and the MLO x-ray views **122**. Preferably, adjunct displays **126** and **128** display thick-slice images **136** and **138**, respectively, corresponding to thick-slice regions of the breast volume substantially parallel to the CC and MLO view planes, respectively, acquired while the breast was flattened along the CC view plane and the MLO view plane, respectively. This allows the spatial content of the thick-slice images to roughly correspond to the spatial content of the corresponding x-ray mammograms, facilitating ready comparisons therebetween. However, the scope of the preferred embodiments is not necessarily so limited. According to an alternative preferred embodiment, the benefits of meaningful “second look” information inside the breast structure is still provided even where (i) the breast is compressed along a non-standard plane during the volumetric scans, or (ii) the breast is not compressed at all during the volumetric scans, or

(iii) the thick-slice images correspond to planes not parallel to a standard x-ray mammogram view plane. In view of the thick-slice segmentation and inversion process described herein and other features and advantages according to the preferred embodiments, such non-standard compressions or non-standard thick-slice planes can still result useful thick-slice adjunctive ultrasound images for viewing, especially where a spatial guide similar to the iconic representations *infra* are displayed to properly “orient” the reader to the position and orientation of the non-standard thick-slice image.

[0052] According to a preferred embodiment, adjunct displays **126** and **128** are designed to facilitate quick, intuitive, and interactive navigation among different views of the thick-slice images and other adjunctive ultrasound data. Adjunct displays **126** and **128** are preferably touch-screen displays but other input devices just as a PC keyboard and mouse (not shown) can be used. FIG. 1 also shows control buttons **134** and **140** on adjunct displays **126** and **128**, respectively, that have layouts and functionalities described further *infra*. A bar code reader **143** reads a bar code of the x-ray mammogram, wherein the associated adjunctive ultrasound data for that breast is automatically retrieved from the ultrasound server **106**. In the event that the x-ray mammograms are loaded onto a motorized viewer, the bar codes from the x-ray mammograms are read as the images are loaded into the apparatus by a technician. Alternatively, the user can scan the bar code directly from the x-ray mammogram when it appears in front of them using a hand-held bar code scanner, wherein the corresponding adjunctive ultrasound data is retrieved from the adjunctive ultrasound server **106**. For clarity of presentation, the user interface description herein is presented relative to the CC adjunct display **126**, it being understood that analogous descriptions apply to the MLO adjunct display **128** or to non-standard-plane adjunct displays in general. Additionally, although most of the exemplary displays herein show the CC data for a single breast (left or right), it is to be appreciated that concurrent viewing of the CC data for the other breast on the same display, or combinations of CC/MLO/non-standard views for both left and right breasts, are clearly within the scope of the preferred embodiments.

[0053] The adjunct display **126** of FIG. 1 contains an array of smaller, or thumbnail, thick-slices images **136**, with the terms small and thumbnail simply indicating that the images are small enough to fit on the same monitor while communicating structures of more than one thick-slice region of the breast, and are smaller in size than the enlarged versions. Due to practical display size limitations, it is expected that the small or thumbnail images will be less than full-scale images and the enlarged versions will be greater than full-scale, although the scope of the preferred embodiments is not so limited. In one alternative preferred embodiment both the thumbnail and enlarged versions are less than full-scale, while in another preferred embodiment the thumbnail images are at full-scale and the enlarged versions are greater than full-scale, while in still another alternative preferred embodiment the thumbnail and enlarged versions are both greater than full-scale.

[0054] As described in Ser. No. 10/160,836, *supra*, the thickness of the slab-like or thick-slice volume corresponding to each thick-slice image may lie, for example, in the range of 2 mm to 20 mm, although the scope of the preferred embodiments is not so limited, and thicknesses in the range of 7 mm to 12 mm are likely to be suitable for most breast cancer

screening purposes. Techniques for integrating the component ultrasound slices into thick-slice images according to the preferred embodiments include arithmetic averaging, geometric averaging, reciprocal averaging, exponential averaging, and other averaging methods, in each case including both weighted and unweighted averaging techniques. Other suitable integration methods may be based on statistical properties of the population of component ultrasound slices at common locations, such as maximum value, minimum value, mean, variance, or other statistical algorithms. One particularly suitable algorithm for generating thick-slice images from a volumetric representation of a breast is described *infra* with respect to FIGS. **12-13**.

[0055] FIG. 2 illustrates steps for breast cancer screening using adjunctive ultrasound mammography according to a preferred embodiment. At step **202** an x-ray mammogram is obtained and at step **204** volumetric ultrasound scan data is obtained. At step **206** the ultrasound scan data is associated with the x-ray mammogram data for the patient, breast, view, date, etc., as generally described in parent application Ser. No. 10/160,836, *supra*. At step **208** thick-slice images are formed from the volumetric ultrasound scan data according to the method described *infra* with respect to FIGS. **12-13**. For CC thick-slice images, i.e., thick-slice images representing thick-slice volumes substantially parallel to the CC plane, each thick-slice image is a scalar function of coordinates (x,z). At step **210** an optional step is performed wherein computer-aided diagnosis (CAD) algorithms are applied to the ultrasound scan data and/or x-ray mammogram data. In accordance with a preferred embodiment, the resulting CAD markers may be superimposed upon one or more of the thick-slice images described throughout this application, on any of planar ultrasound views, on any of the x-ray mammogram views, or any combination of them to achieve a CAD-enabled display.

[0056] At step **212** the breast tissue is segmented from outlying areas using any of a variety of known segmentation algorithms. Preferably, a three-dimensional segmentation algorithm is performed directly on the three-dimensional volumetric scan data, although in other preferred embodiments a two-dimensional segmentation algorithm is separately applied to each thick-slice image. The segmentation step **212** results in a mask for each thick-slice image identifying the breast tissue boundary.

[0057] At step **214** inverted thick-slice images are computed from the ordinary or non-inverted thick-slice images. As used herein, a non-inverted or ordinary thick-slice image generally conforms to a standard medical ultrasound display convention in which readings of lesser acoustic reflections are displayed as “darker” (black, dimmer, darker gray, lower-intensity, etc.) and in which readings of higher acoustic reflections are displayed as “brighter” (whiter, lighter, higher-intensity, etc.). An inversion algorithm converts each non-inverted thick-slice image pixel $P_o(x,z)$ into a complementary or inverted value $P_{INV}(x,z)$ that is then “brighter” in regions of lesser acoustic reflection and “darker” in regions of higher acoustic reflection.

[0058] It has been found that displaying inverted thick-slice images can substantially enhance the viewing and screening process, and can facilitate the dismissal of benign lesions better than a display of non-inverted thick-slice images. This is at least because, for inverted thick-slice images, differential viewing of breast lesions versus surrounding tissue structures is provided on a similar basis as that for x-ray mammograms.

For example, most radiologists have developed years of expertise in differentiating “bright” lesions from surrounding ligaments on x-ray mammograms, the surrounding ligaments also being “bright” but having different visual cues. The use of inverted thick-slice images allows their years of expertise to be extended over to the thick-slice ultrasound data, in contradistinction to the conventional ultrasound display method that would require the difficult task of differentiating “dark” lesions based on different visual cues than “dark” surrounding ligaments.

[0059] Although any of a variety of inversion algorithms could be used in accordance with the preferred embodiments at step 214, it has been found beneficial to use an inversion algorithm that also performs some degree of contrast-enhancement when mapping the darker values of $P_0(x, z)$ into the brighter values of $P_{INV}(x, z)$. For an exemplary situation in which the display monitor pixels are brightest at value 255 and lowest at value 0, one particularly suitable algorithm is given in Eq. (1) below, with γ (“gamma”) being set to 0.5:

$$P_{INV}(x, z) = 255 \left(\frac{255 - P_0(x, z)}{255} \right)^{1/\gamma} \quad \{1\}$$

[0060] During image inversion, non-breast areas of the thick-slice images, which are initially dark, are converted to bright as displayed in the example of FIG. 8, *infra*. According to a preferred embodiment, the non-breast areas of the thick-slice images, as identified by the masks previously computed at step 212, are reset to dark. This step is performed so that the displayed thick-slice images are more reminiscent of an x-ray mammogram, which is dark in the unexposed regions lying outside the breast. It is to be appreciated, however, that this step can be skipped without departing from the scope of the preferred embodiments, as some users may end up preferring the white background.

[0061] Generally speaking, the ultrasound processing steps 208-214 are usually not performed in real-time, but rather are performed during an interval between the scanning process and viewing process, which can be a period of several hours or more. However, the scope of the preferred embodiments is not so limited, and the steps 202-214 may also be performed in real-time if practicable in a given clinical setting.

[0062] At step 216 the x-ray mammogram information is retrieved and displayed to the user. At step 218 the corresponding adjunctive ultrasound data is retrieved, including the inverted thick-slice images. At step 220 the user views and analyzes the x-ray mammogram image. In a manner analogous to FDA-approved practices for “second-look” x-ray mammogram CAD results, the user should first examine the x-ray mammogram without reference to the thick-slice images, first arriving at an independent conclusion based on the x-ray mammograms alone. Only after the independent x-ray mammogram analysis should the user view the thick-slice images (step 222), wherein the user interacts with the adjunct ultrasound display as necessary to confirm and/or supplement the x-ray mammogram analysis. Optionally, to ensure the proper order of viewing, the thick-slice images are withheld from view until the user verifies that an independent x-ray mammogram analysis is completed by pressing, for example, a confirmation toggle button or entering an appropriate user command.

[0063] FIG. 3 illustrates steps for interactively displaying adjunctive ultrasound mammography information to a user

according to a preferred embodiment. FIGS. 4-6 illustrate an adjunct display screen 400 at particular stages during the steps of FIG. 3. At step 302 an array of inverted thick-slice images is displayed. FIG. 4 illustrates an example of a thick-slice image array 402 on the adjunct display screen 400. Adjunct display screen 400 further comprises a patient ID section 404 comprising patient identification and other relevant information. Adjunct display screen 400 further comprises a control button array 406 comprising buttons that can be actuated by a touchscreen press or a mouse/trackball inputs. Also shown in FIG. 4 is a selection marker 407 appearing at a location 408 superimposed on a thick-slice image 410. If a mouse/trackball input is used, the default mouse pointer changes to the selection marker 407 when guided over any one of the thick-slice images 402.

[0064] At step 304 a single-click or single-motion input from the user is received indicating a first selected location on a selected inverted thick-slice image. With reference to FIG. 4 this is achieved by making a mouse click with the selection marker 407 at the current position (408) or by pressing the touchscreen at position 408. In the case of a touchscreen, it is recommended that a pointing device finer than a human finger be used, such as the stylus of a personal digital assistant (PDA), to touch the screen at the location 408. Responsive to the single-click or single-motion input, at step 306 an enlarged view 502 of the selected inverted thick-slice image 410 is displayed. A selection marker 503 is displayed at a location 504 that corresponds to the same relative position on the breast as the location 408 on the thick-slice image 410.

[0065] Also shown in FIG. 5 is a three-dimensional icon 506 that roughly illustrates the thickness, location, and orientation of the thick-slice volume corresponding to the thick-slice image 502. In particular, the iconic thick-slice volume 508 is shown relative to an iconic rectangular solid 510 that roughly corresponds to the compressed breast. Although not illustrated as such in FIG. 5, it is preferable to display an iconic frame that more closely resembles a perspective view of the breast rather than the iconic rectangular solid 510. The iconic frame can comprise a three-dimensional rendering of a semi-transparent breast, and the iconic thick-slice volume 508 can be suspended at the appropriate location and orientation therein. Because the three-dimensional icon 506 does not provide any specific diagnostic information to be relied upon, it is not necessary for the iconic frame to be a perfect replica of the actual scanned breast. However, to increase the intuitiveness of the display, especially to new users, it is preferable that the semi-transparent rendering be of at least sufficient quality to be recognizable as a breast volume.

[0066] At step 308 a second single-click or single-motion input is received from the user indicating a second selected location on the enlarged inverted thick-slice image. By default, the second selected location is at the same point relative to the enlarged inverted thick-slice breast as the first selected location was to the thumbnail or smaller thick-slice image, unless the user affirmatively moves the selection marker 503 prior to clicking. In the example of FIGS. 4-6, the second selected location is at location 504 of FIG. 5. At step 310 a raw ultrasound image or reconstructed thin-slice image encompassing the second selected location is displayed.

[0067] FIG. 6 illustrates a raw ultrasound slice 602 displayed responsive to the second single-click or single-motion input. The raw ultrasound slice 602 is preferably shown in a standard, non-inverted format because this direct form of ultrasound viewing is already familiar to most users. How-

ever, it is within the scope of the preferred embodiments for the raw ultrasound slice **602** to be inverted prior to display. The raw ultrasound slice **602** represents one example of a planar ultrasound image representing sonographic properties of the breast along a plane cutting through the breast. In particular, the raw ultrasound slice **602** represents a first planar ultrasound image representing values along a first plane perpendicular to the orientation of the thick-slice region corresponding to the thick-slice image being displayed, wherein the first plane is also parallel to an ultrasound scan plane of the ultrasound probe that is swept across the breast during the volumetric scanning process. Most examples of planar ultrasound images described herein are raw ultrasound slices or orthogonal thin-slice images, the orthogonal thin-slice images being planar ultrasound images representing values along a second plane perpendicular to both (i) the raw ultrasound image, and (ii) the orientation of the thick-slice region corresponding to the thick-slice image being displayed. The orthogonal thin-slice images need to be reconstructed from the three-dimensional volumetric representation, as opposed to the raw ultrasound slices which can be taken directly from the raw data used to construct the three-dimensional volumetric representation. It is to be appreciated that while most examples of planar ultrasound images described herein are raw ultrasound slices or orthogonal thin-slice images, the scope of the preferred embodiments is not limited as such and extends to general cases of first and second planar ultrasound images having differing orientations.

[0068] Several features are provided on the adjunct display of FIG. 6 to assist the user in visualizing the location and orientation of the raw ultrasound slice **602** relative to the breast volume. First, an alphanumeric representation **603** of the actual raw slice number (in this example, slice number 300) out of the total number of raw slices (in this example, 533 slices) taken during the scanning process is shown. The three-dimensional icon **506** including the iconic rectangular solid **510** that roughly represents the breast volume outline is maintained in this view, with the position and orientation of the raw ultrasound slice **602** being shown therein by an iconic plane **604**. In accordance with step **312** of FIG. 3, upper and lower range markers **606** and **608**, respectively, indicate the upper and lower “y” for the thick-slice image **502** previously being viewed at a horizontal “z” position corresponding to the selected location **504** from FIG. 5. Depth range markers **612** indicate the vertical “y” extent for the thick-slice image **502** as well. Hash markers **610** also assist in locating the range markers **606** and **608**. Finally, the location of range markers **606** and **608** relative to the raw ultrasound plane is also indicated by an iconic marker **605** on the three-dimensional icon **506**.

[0069] In the example of FIG. 6, it is a raw ultrasound slice that is displayed because the ultrasound scans were taken directly in the y-z plane by the ultrasound scanning device **102** of FIG. 1. In a more general case, the raw ultrasound scans may not have been taken in planes perpendicular to the thick-slice region of the thick-slice image of FIG. 5. In those circumstances, a planar or thin-slice ultrasound image is reconstructed from the volumetric ultrasound data, the planar ultrasound image representing values along a plane perpendicular to the orientation of the relevant thick-slice region and passing through the second selected location of FIG. 5. The planar or thin-slice ultrasound image is preferably computed to represent as thin a slice as possible while remaining accurate, or to represent a slice having a thickness corresponding

to the elevation beamwidth of the linear probe used to scan the breast if such type of probe was used.

[0070] At step **314** cine viewing of raw ultrasound or thin-slice image frames is accommodated, beginning at the frame of raw ultrasound slice **602**. In the case of a mouse input, the cine can be controlled by a mouse wheel or mouse-mounted trackball. In the case of a touchscreen display, cine control can be achieved by a separate trackball provided near the display. A foot pedal can also be used for cine control to free up the hands of the user. Onscreen cine control buttons **614** can also be used.

[0071] At step **316** single-click or single-motion return to the selected enlarged inverted thick-slice image or to the array of inverted thick-slice images is accommodated. For example, a left-click of a mouse (or single-tap of a stylus on a touchscreen display) at a third selected location on the raw ultrasound slice **602** can bring up the enlarged thick-slice image corresponding to “y” depth of the third selected location, with a marker thereon indicating the (x,z) location of the third selected point. Alternatively, an onscreen “one slab” onscreen button **616** can be pressed to bring up the previous enlarged thick-slice image **502**. A right click of a mouse (or double tap of a stylus on the touchscreen display) at the third selected point can bring up the array **402** of thick-slice images, with markers indicating the (x,z) position of the third selected location superimposed on the appropriate one of the thick-slice images for the “y” depth of the third selected location. Alternatively, an “all slab” onscreen button can be pressed to bring up the array **402** of thick-slice images.

[0072] FIG. 7 illustrates the adjunct ultrasound display screen **400** according to an alternative preferred embodiment in which an array **702** of non-inverted thick-slice images are displayed. The non-inverted thick-slice image array **702** corresponds to the same breast and ultrasound scanning session as for the inverted thick-slice image array of FIG. 4. With reference to a particular region **704** circled in FIG. 7, it has been found that the non-inverted thick-slice images **702** have a tendency to contain substantial areas of darkness in the breast tissue, wherein it is more difficult to detect subtle texture differences in breast tissue because it requires the differentiation of “dark” lesions from “less dark” or “differently dark” surrounding ligaments. This can lead to a larger number of false positives and also to user fatigue and frustration. In distinction, the inverted thick-slice images of FIG. 4 are easier to analyze, at least because of (i) the many years of training that most radiologists have in differentiating “bright” lesions from “bright” surrounding ligaments in x-ray mammograms, and (ii) the contrast enhancement performed at brighter output levels during the inversion step **214** supra.

[0073] FIG. 8 illustrates the adjunct ultrasound display **400** according to another preferred embodiment presenting an array **802** of thick-slice images that were inverted but for which the background segmentation and darkening steps were omitted. The thick-slice image array **802** corresponds to the same breast and ultrasound scanning session as for the thick-slice image arrays of FIG. 4 and FIG. 7. As indicated in FIG. 8, the outlying non-breast areas are bright instead of dark. In addition to being less familiar to most radiologists trained on x-ray mammograms, it is believed that this preferred embodiment might also lead to greater eyestrain. However, this preferred embodiment might nevertheless represent a desirable display format for some nonzero population of users.

[0074] FIGS. 9-11 illustrate a thick-slice image array 902, an enlarged thick-slice image 1002, and a raw ultrasound slice 1102, respectively, in a manner analogous to the images 402, 502, and 602 of FIGS. 4-6, but for a different patient. FIGS. 9-11 illustrate one of the many features and advantages of the preferred embodiments wherein in which lesion shadows among successive thick-slice images, or the lack thereof, can rapidly assist in a diagnosis. Circled in FIG. 9 are locations L-3, L-4, and L-5 to indicate a particular (x,z) location L at thick-slice zones 3, 4, and 5, respectively. Notably, there is a white spot in the third zone at L-3, as illustrated on both FIG. 9 and FIG. 10, but there are dark spots in corresponding areas L-4 and L-5 of the fourth and fifth zones lying underneath the third zone. This indicates that there were low acoustic reflection readings for the third zone at L-3, while there were high acoustic reflection readings for two zones directly therebelow at L-4 and L-5. Accordingly, it is highly likely that this is a benign liquid-filled cyst that can be readily ignored. This can be quickly verified by viewing the raw ultrasound slice 1102 of FIG. 11, which shows a dark area 1104 of low reflections over an area 1106 of accentuated reflections.

[0075] Thus, according to a preferred embodiment, a method for quickly diagnosing the presence of a benign, liquid-filled cyst is provided, comprising the step of viewing an array of inverted thick-slice ultrasound images including a first inverted thick-slice image and a plurality of neighboring inverted thick-slice images, the neighboring inverted thick-slice images corresponding to thick-slice regions directly below the thick-slice region of the first inverted thick-slice image relative to an ultrasound detector. The method further comprises the steps of observing a bright spot in the first thick-slice image and searching for dark spots in the plurality of neighboring inverted thick-slice images at locations corresponding to the bright spot. If such dark spots are present, the bright spot of the first inverted thick-slice image is diagnosed to be a benign, liquid-filled cyst. The method further comprises the step of verifying such diagnosis by viewing a raw ultrasound slice or reconstructed thin-slice image having a plane that passes through the breast location indicated by the bright.

[0076] With reference to FIG. 11, selected onscreen control buttons 406 are now described. An onscreen "select study" onscreen button 1150 activates a file selection dialog box in which the user can select adjunctive ultrasound data for a particular patient and scan session. Onscreen "view selection" buttons 1152 select the desired view of LCC, RCC, LMLO, and RMLO. Onscreen display selection buttons 1154 allow the user to select the "all slab" view of FIG. 4, the "one slab" view of FIG. 5, the "standard" view of FIG. 6, or a "top" view representing an integration of all thick-slice regions for that view. Onscreen "film box" buttons 1156 allow for easy collection and/or printing of interesting images for subsequent review.

[0077] FIG. 12A illustrates a conceptual view of a thick-slice or slab-like region 1202 substantially parallel to the CC plane, along with hypothetical mass lesions 1206, 1208, and 1210, presented for describing thick-slice image computation according to a preferred embodiment. As indicated by the provided reference axes, the thick-slice region 1202 is being viewed from the +z direction, i.e., from the front of the woman. The thick-slice region 1202 has a thickness T which can be about 1 cm for this example. The described thick-slice image computation algorithms operate on standard, non-inverted ultrasound voxel values for which zero is "dark" and

255 is "bright," although it is to be appreciated that it could be readily adapted by a person skilled in the art in view of the instant disclosure to operate on inverted ultrasound voxel values or otherwise-remapped voxel values.

[0078] Shown in FIG. 12A are side views of pixel columns 1204, including pixel columns 1212, 1214, and 1216 passing through the hypothetical mass lesions 1206, 1208, and 1210, respectively. A given pixel column extending downward in the y direction passing through the thick-slice region at pixel location (x,z) could comprise, for example, 40-60 voxels, each having an 8-bit value $V_{xz}(y_n)$. For each pixel column passing through the thick-slice region 1202, a scalar output value $P_0(x,z)$ is computed that constitutes the thick-slice image at that pixel location. In a simplest preferred embodiment, the thick-slice computation algorithm simply computes an average pixel value, as described by Eq. (2) below, where N is the number of voxels in the pixel column at (x,z):

$$P_0(x, z) = \frac{\sum_{n=1}^N V_{xz}(y_n)}{N} \quad \{2\}$$

[0079] However, it has been found that thick-slice images more useful in breast cancer screening can be achieved by using a thick-slice computation algorithm that detects particular statistical variations of $V_{xz}(y_n)$ in the neighborhood of masses in a manner that emphasizes masses larger than a predetermined target size and de-emphasizes smaller masses in the resulting thick-slice image.

[0080] Shown in FIG. 12A for each of the pixel columns 1206, 1208, and 1210 passing through the respective hypothetical mass lesions is a histogram of the number of pixel elements at each respective gray value. Under the non-inverted convention of FIG. 12, the mass lesions of interest for breast cancer screening purposes tend to show up as "dark" regions against "whiter" backgrounds. It is to be observed that pixel columns passing through smaller masses, such as pixel column 1212 passing through mass 1206 having size S1, have substantially more high pixel values than low pixel values, as revealed by the associated histogram curve. As such, the area under the histogram from zero to a pixel value, termed herein the CDF or cumulative distribution function of $V_{xz}(y_n)$, remains low for most pixel values and only increases as higher pixel values are reached. Conversely, pixel columns passing through larger masses, such as pixel column 1214 passing through mass 1208 of size S2, have substantially more low pixel values than high pixel values, as revealed by the associated histogram curve and CDF.

[0081] According to a preferred embodiment, a target size D is established representing a mass size expected to be interesting from a breast cancer screening point of view. For purposes of this example, and not by way of limitation, a suitable target size D can be about 0.5 cm, which yields a target size to slab thickness ratio (D/T) equal to 0.5. The output pixel value $P_0(x,z)$ is set equal to that pixel value for which the cumulative distribution function of $V_{xz}(y_n)$ is equal to a preselected value K times the target size to slab thickness ratio. This is graphically illustrated in FIG. 12 and expressed in Eq. (3) below:

$$CDF_{V_{xz}}[P_0(x, z)] = K \left(\frac{D}{T} \right) \quad \{3\}$$

[0082] FIG. 12B illustrates a conceptual view of the thick-slice region 1202 and lesions 1252 contained therein for a single fixed value of $z=z_{fixed}$, along with plots 1254 and 1256 of thick-slice image values $P0(x, z_{fixed})$ along a single line, the thick-slice images being computed according to Eqs. (2) and (3), respectively. For ease of computation and presentation, the lesions and surrounding breast tissue are assigned the extreme brightness values of 0 and 255, respectively. Although this conceptualizes the example somewhat by using an “extremely” bimodal voxel value distribution, it is to be appreciated that regions near mass lesions often have histogram distributions with a roughly bimodal characteristics, and so the results of FIG. 12B are roughly representative of the actual results obtained. A preselected value of $K=0.5$ was used in the application of Eq. (3). As indicated by a comparison of plot 1254 versus the plot 1256, the use of the CDF-based method of Eq. (3) yields a resulting thick-slice image that enhances the visibility of lesions as they approach and exceed the target size D , while de-emphasizing smaller lesions. Different values of K may be used in Eq. (3), e.g., in the range of 0.25 to 0.75, and the value may be optimized for a given configuration based on empirical results. Generally speaking, as K is increased there is decreased “sensitivity” with more of the smaller lesions being ignored. In an alternative preferred embodiment, the value of K may be dynamically assigned based on local volume characteristics, for example, as a function of the local statistical variance of the voxel values.

[0083] FIG. 13 illustrates a border compensation method for thick-slice generation according to the preferred embodiments that compensates for the possibility that lesions may straddle thick-slice borders. Shown in FIG. 13 is an exemplary thick-slice region 1302 vertically adjacent to an upper thick-slice region 1306 and a lower thick-slice region 1304. Also shown in FIG. 13 are exemplary mass lesions A-G, some of which are entirely contained in one of the thick-slice regions and some of which straddle the thick-slice region borders. As indicated in FIG. 13, the terms upper and lower are indicative of a distance from an ultrasound probe used to scan the breast volume. According to a preferred embodiment, when computing a thick-slice image, two alternative thick-slice values for each location (x, y) are computed, including a first value corresponding to the actual borders of the thick-slice region and a hypothetical value corresponding to the borders of a hypothetical thick-slice region having a similar thickness but extending into the next upper thick-slice region. In the example of FIG. 13, a hypothetical thick-slice regions 1302a and 1304a correspond to thick-slice regions 1302 and 1304, respectively. For each location (x, z) in the thick-slice image, the lesser (i.e., “darker”) of the first value and the hypothetical value is used.

[0084] Also shown in FIG. 13 are conceptual thick-slice images 1302', 1304', and 1306' corresponding to thick-slice regions 1302, 1304, and 1306, respectively. In this example, it is presumed that there are no lesions in the breast other than the mass lesions A-G. For purposes of presentation, a filled-in circle is shown when the “entire effect” of a mass lesion is present in the thick-slice image, whereas an empty circle is shown when only a “half effect” is present. Notably, whereas the lesion B would only be “half-present” in both of the thick-slice images 1306' and 1302' in an uncompensated scenario (not shown), it is “fully-present” in the thick-slice image 1302' as well as “half present” in thick-slice image 1306' in the compensated scenario shown in FIG. 13. Lesion

A, which would be fully-present in thick-slice image 1306' and not present in thick-slice image 1302' in an uncompensated scenario, is fully-present in both of the thick-slice images 1306' and 1302' in the compensated scenario. It has been found that this border-straddling compensation strategy, for which other examples are presented in FIG. 13, represents a desirable result even though it tends to “redundantly” show the same lesion twice. It has been found that it is more desirable to provide “redundant” showings of the same mass lesion in two adjacent thick-slice images than to fail to display the “full effect” of a mass lesion straddling the borders of those slices. Also, because the display of the ultrasound thick-slices is only used in an adjunctive diagnostic sense, and not in an absolute diagnostic sense, there are few if any practical implications for overall system specificity.

[0085] FIG. 14 illustrates steps for interactive display of adjunctive ultrasound mammography information according to a preferred embodiment. The steps of FIG. 14 are further illustrated in the adjunct displays of FIGS. 15-17. At step 1402, an array of thick-slice images is displayed adjacent to a raw ultrasound slice and an orthogonal thin-slice image. With respect to FIG. 15, the array of thick-slice images 1502 is displayed next to planar ultrasound images 1504 including a raw ultrasound image 1506 and an orthogonal thin-slice image 1508. At step 1404, an active member of the thick-slice array is selected, such as by receiving a simple mouse point-and-click from the user, and is then highlighted. With respect to FIG. 15, thick-slice array 1502 comprises an active member 1510 having a highlighted marking 1519 shown thereon. First and second range markers 1513 and 1514, respectively, are provided on the raw ultrasound image 1506 and the orthogonal thin-slice image 1508, respectively, marking the upper and lower border of the thick-slice region of the active slice 1510 at a horizontal position corresponding to a cursor marker 1512 thereon.

[0086] Superimposed on active member 1510 are first and second plane indicators 1517 and 1518, respectively. The first plane indicator 1517 corresponds to a first plane through the breast volume as displayed by the raw ultrasound image 1506, and is visually related thereto by means of a color such as green that matches colored lines at the edges of the raw ultrasound image 1506. Preferably, the colored lines at the edges of raw ultrasound image 1506 extend from the posterior edge thereof across to the current position of the range marker 1513, which makes it easier to keep track of the first range marker 1513 as the cursor 1512 is moved by the user. The plane indicator 1517 is likewise heavily drawn from the posterior edge to the cursor position and then lightly drawn over to the anterior edge to assist tracking. According to an alternative preferred embodiment, the first range marker 1513 can remain fixed at the center of the frame, while the rest of the raw ultrasound slice dynamically shifts around it according to user cursor movements. Similar descriptions apply to second plane indicator 1518, orthogonal thin-slice image 1508, and second range marker 1514.

[0087] At step 1408 the position of cursor 1512 on active member 1510 is projected onto other members of the thick-slice image array. Shown in FIG. 15 with respect to a representative second member image 1515 is a projected cursor 1516. Also shown in the second member image 1515 are projected first and second plane indicators 1517a and 1518a.

[0088] At step 1410 the user moves the cursor position on the active thick-slice image. At step 1412 in a real-time “cine-

like" display is provided wherein the planar images **1504** are refreshed in real-time to keep up with the current position of plane indicators **1517** and **1518**, which follow the cursor position. At step **1414**, real-time updating of the cursor projections and the plane indicator projections is provided. According to a preferred embodiment, shifts in the position of cursor **1512** and corresponding shifts in the plane indicators **1517** and **1518** are mirrored in the other members of the thick-slice array, as illustrated in FIG. **16**. FIG. **16** also shows how range markers **1513** and **1514** are shifted to new positions **1613x** and **1614x**, respectively, during the cursor shift, as well as the manner in which the colored edges of the planar images shift with cursor position.

[**0089**] Also shown in FIGS. **15** and **16** is a patient ID **1520** and a three-dimensional icon **1522**. The three-dimensional icon **1522** comprises a frame structure **1524** similar to the frame structure **510** of FIG. **5**, and two iconic plane indicators **1526** and **1528** thereon corresponding to plane indicators **1517** and **1518**, respectively. As indicated in FIG. **16**, the iconic plane indicators **1526** and **1528** also move dynamically with the cursor position. In one preferred embodiment, the look and feel of the cursor movement is analogous to a computer-aided drawing display (e.g., Microsoft Visio) in which the cursor can, at the user's option, "stick" to horizontal and vertical "grid lines". This allows for one of the planar ultrasound images **1506** or **1508** to remain perfectly static if the cursor is moved along the horizontal or the vertical directions. As described supra, in an alternative preferred embodiment the range markers **1513** and **1514** can remain fixed at the center of the planar ultrasound frame, while the images move around them, it being found that many users can focus better on the tissue near the cursor position using this method.

[**0090**] In the display of FIGS. **15-16**, soft buttons analogous to those of FIGS. **4-11** are omitted in favor of a mechanical keypad described infra, although the scope of the preferred embodiments is by no means so limited. At step **1416**, the displayed thick-slice images are inverted (see FIG. **8**, supra) when the user presses an "invert" button on the keypad. Preferably, when an inverted convention is used, the background is segmented out and returned to dark. At step **1418** an enlarged view of the active thick-slice image is displayed if the user clicks or taps on a selected cursor position or enters a "one slab" keypad entry.

[**0091**] FIG. **17** illustrates an enlarged view **1702** of the active thick-slice image member **1510** of FIGS. **15-16** that appears at step **1418**. The cursor position **1704** corresponds to the same breast location as the selected cursor position **1512** of FIG. **15**. At step **1420**, the user is permitted (on either the one-slab or all-slab displays) to manipulate the orientation and positions of plane indicators **1706/1708** or **1517/1518** in a manner similar to the way a computer draftsman manipulates lines in a graphical illustration, while in real-time the planar ultrasound images **1504** remain updated to reflect corresponding planes through the breast volume.

[**0092**] FIG. **18** illustrates an exterior view of an adjunctive ultrasound mammography display unit **1802** in accordance with a preferred embodiment. Adjunctive ultrasound mammography display unit **1802** comprises an x-ray film conveyor and display unit **1804** with modifications made to accommodate adjunctive ultrasound display. X-ray film conveyor and display unit **1804** comprises a lower film conveyor **1806** and an upper film conveyor **1812**, the lower conveyor **1812** being turned off in this example and the lower conveyor **1806** displaying two x-ray mammogram images **1808** and

1810. Conventional control buttons **1814** provided with most commercially available x-ray film conveyor and display units are provided to control the x-ray mammogram film conveyors.

[**0093**] According to a preferred embodiment, adjunctive ultrasound mammography display unit **1802** comprises a full-sized LCD display **1816** integrated into a front table portion thereof as shown in FIG. **18**. Preferably, LCD display **1816** is large enough to display two full-scale thick-slice ultrasound images simultaneously, including a left image corresponding to the x-ray mammogram image **1808** and a right image corresponding to x-ray mammogram image **1810**. A 17-inch diagonal LCD display has been found suitable to achieve this objective. In contrast to the preferred embodiment of FIG. **1**, supra, LCD display **1816** is conveniently located to allow back-and-forth viewing between the thick-slice images and the x-ray images in an up-and-down manner, with minimal head motion. As discussed previously, even subtle ergonomic issues can be of crucial importance in the breast cancer screening process, because if the image viewing apparatus leads to tired or physically fatigue radiologists, such fatigue can unfortunately transform into a potentially fatal missed diagnosis or, alternatively, the inefficient process of an unnecessary patient callback.

[**0094**] In distinction contrast to cathode ray tube (CRT) monitors of equivalent viewable size, the LCD display **1816** can be advantageously placed in the middle of the table portion without interfering with the knees of the user. Adjunctive ultrasound mammography display unit **1802** further comprises CRT monitors **1818** and **1820** directly to the left and right of the LCD display **1816**, respectively. Preferably, the CRTs have a 7-inch diagonal screen. It has been found more desirable to present the above planar ultrasound images (e.g., raw ultrasound slices and orthogonal thin-slice views) on smaller CRT displays on the side of a larger LCD thick-slice display. The smaller CRT display allows for a substantially increased brightness range and also represents a more familiar optical characteristic to users familiar with traditional ultrasound displays. Among these characteristics is a slight low-pass filtering effect due to the finite width of the cathode-ray beam, in distinction to a pixellating effect that can be observed on LCD monitors. Because the CRT monitors **1818** and **1820** are set back and to the side of the LCD monitor **1816**, they do not interfere with the knees of the user. Adjunctive ultrasound mammography display unit **1802** further comprises a mouse **1822** and a keypad **1824** for controlling the adjunctive ultrasound mammography displays.

[**0095**] FIG. **19** illustrates the keypad **1822** of FIG. **18** in more detail. The keypad **1822** provides functionality similar to the soft buttons described supra with respect to FIG. **11**, with some additional capabilities relevant to the preferred embodiments of FIGS. **15-17**. An "invert" key **1902** causes the display of all thick-slice images to be inverted, as described supra with respect to FIG. **14**. Also, a "prev slab" key **1904** and "next slab" key **1906** are provided as an additional method for allowing the user to change the active member of the thick-slice array being displayed.

[**0096**] FIG. **20** illustrates an x-ray/adjunctive ultrasound mammography display according to a preferred embodiment as implemented on the apparatus of FIG. **18**. An example is shown for the CC view, it being understood that an equivalent display is also provided for the MLO view. The MLO x-ray views may be shown, for example, on the upper conveyor **1812** of FIG. **18**, while a toggle button allows the correspond-

ing adjunctive ultrasound images for the MLO view to be displayed on monitors **1816**, **1818**, and **1820**. Shown in FIG. **20** is an RCC x-ray mammogram film **2002** and an LCC x-ray mammogram film **2004**. On the left hand side of LCD display **1816** is a thick-slice array **2006** for the CC view of the right breast, and on the right hand side of LCD display **1816** a thick-slice array **2008** for the CC view of the left breast. CRT monitor **1818** displays a raw ultrasound image **2010** and orthogonal thin-slice view **2012** corresponding to a current active cursor position on the RCC thick-slice display **2006**. CRT monitor **1820** shows equivalent planar ultrasound images **2014** and **2016** for the LCC thick-slice display **2008**.

[**0097**] According to an alternative preferred embodiment, only a single CRT display is provided to one side of the central LCD display, the central LCD display showing thick-slice images for only a single breast, and the CRT display showing the corresponding planar ultrasound images. This alternative preferred embodiment can be advantageous for cost and space considerations, as well as in recognition of the fact that the user will generally only be closely analyzing a single breast of a time.

[**0098**] According to another alternative preferred embodiment, one side of FIG. **20** displays CC views (CC x-ray, CC thick-slice images, and CC planar ultrasound images) for a single breast, while the other side of FIG. **20** displays MLO views (MLO x-ray, MLO thick-slice images, and MLO planar ultrasound images) for that breast. This preferred embodiment can be advantageous insofar as all standard information for the breast is now provided in a single set of images being concurrently displayed, rather than requiring the user to physically instantiate switches between CC and MLO views of the same breast during analysis.

[**0099**] A variety of other configurations, each having its particular advantages, is also within the scope of the preferred embodiments. By way of example, the thick-slice images may instead be provided on paper or on film, while the electronic display of thin-slice images are an optional addition to the unit. Where the thick-slice images are provided on film, a technician can simply load the thick-slice image films into the conveyor unit adjacent to or above the standard x-ray films.

[**0100**] According to another preferred embodiment relating generally to the method of FIG. **14**, the user may instantiate a cine display for the raw ultrasound image **1506**, the orthogonal thin-slice image **1508**, or a combination of both along a predetermined cursor trajectory. By way of example, responsive the user pressing an additional button "lat-med cine" (not shown) on keypad **1822**, a cine display of the raw ultrasound slice **1506** is displayed with the cursor **1512/1704** moving automatically in a vertical direction on thick-slice image **1510/1702** at its current horizontal position. The orthogonal thin-slice image **1508** will remain static. The user can control the cine display using additional cine control buttons (not shown) on keypad **1822**. Likewise, responsive the user pressing an additional button "post-ant cine" (not shown) on keypad **1822**, a cine display of the orthogonal thin-slice image **1508** is displayed with the cursor **1512/1704** moving automatically in a horizontal direction on thick-slice image **1510/1702** at its current vertical position, the raw ultrasound image **1506** remaining static. It is preferable that this preferred embodiment be used in conjunction with the particular above-described preferred embodiment in which the range markers **1513** and **1514** are fixed at the center of the frame.

[**0101**] In a slightly more complicated preferred embodiment, controls are provided for which the user can select a custom cine trajectory, wherein both of the planar ultrasound images **1506** and **1508** will change as the cursor **1512/1704** automatically follows that trajectory. The user can select the custom cine trajectory, for example, by manipulating the plane indicators **1517/1518** in a Visio-like manner as described previously. The user can then activate the cine action by pressing the "lat-med" cine button to make the cursor **1512/1704** move along the plane indicator **1518**, or by pressing the "lat-med" cine button to make the cursor **1512/1704** move along the plane indicator **1517**.

[**0102**] According to another preferred embodiment, CAD markers identifying suspicious lesions are superimposed on the thick-slice images **1502** to direct the attention of the user to those particular locations. Preferably, the CAD markers are generated from the volumetric ultrasound scan data used to generate the displayed thick-slice images **1502**, although the scope of the preferred embodiments is not so limited. According to a preferred embodiment, the CAD markers are displayed responsive to the user pressing a "show CAD marker" button (not shown) on keypad **1822**, and are superimposed on the currently-showing thick-slice display, i.e. the thick-slice array **1502** or the enlarged thick-slice image **1702**. The CAD markers may be color-coded, size-coded, shape-coded, mode-coded (blinking, flashing, etc.), etc., and/or accompanied by nearby alphanumeric tags or text messages to conveniently portray higher-suspiciousness lesions versus lower-suspiciousness lesions. Preferably, where the user presses the "show CAD marker" button as the thick-slice array **1502** is displayed, the active thick-slice image is automatically selected to be that member containing the most-suspicious lesion, the cursor **1512** is automatically relocated to the location of that lesion, and the planar ultrasound images **1506** and **1508** thereby automatically show the location of that lesion in the center of the planar image displays and mark that location with the range markers **1513-1514** and an optional additional indicator.

[**0103**] According to another preferred embodiment for use in conjunction with each of the above embodiments is a reverse-locating capability from a first location of interest on a planar ultrasound image to a corresponding location on the proper corresponding thick-slice image. During review of the planar ultrasound images **1506** and **1508** as the user is moving the cursor **1512/1704** around the active thick-slice member image **1510**, the user may see an interesting location appear somewhere on one of the planar ultrasound images **1506** or **1508**. When this occurs, the user can right-click the mouse or press a "reverse locator" button (not shown) on keypad **1822**. Responsive thereto, the cursor **1512/1704** transforms into a reverse locator pointer, such as by turning into a bright-yellow arrow. The user then moves this arrow over to the first location of interest in the planar ultrasound image **1506** or **1508** and then left-clicks or presses the "reverse locator" button again. Responsive to the selection of the first location of interest, (i) the yellow arrow disappears, (ii) the thick-slice image corresponding to the first location of interest becomes the active thick-slice member image, and (iii) the cursor **1512/1704** re-appears at a location corresponding to that first location of interest. The reverse-locating capability is usable regardless of whether the current display mode is of the thick-slice array **1502** or the enlarged thick-slice view **1702**. In the event that the current display mode is the enlarged thick-slice view **1702**, the currently-displayed thick-slice image is replaced, if

necessary, by a different thick-slice image corresponding to the depth of the first location of interest.

[0104] An adjunctive ultrasound system according to the preferred embodiments does not supplant existing x-ray mammogram screening methods. Indeed, reference to the adjunctive ultrasound data is optional depending on the contents of the x-ray mammogram image, and for many patients it may not even be used at all. Rather, the adjunctive ultrasound system is there to assist the radiologist in performing their pre-existing professional duties with respect to “difficult” or “marginal” mammograms. As such, a medical establishment faces little risk of failure in acquiring an adjunctive ultrasound system according to the preferred embodiments. In a worst-case scenario, the adjunctive ultrasound system would be met with indifference by the entrenched “x-ray-only” believers, because it would not disturb their pre-existing routines. However, the adjunctive ultrasound system will be there standing by to assist in the “difficult” cases, and it is expected that even the “x-ray-only” believers will eventually find the system useful and will increasingly rely on it to increase their sensitivity and specificity performance.

[0105] Also within the scope of the preferred embodiments is a computer program product for instructing one or more processors to carry out one or more of the methods of the preferred embodiments, such computer program product being amenable to ready implementation by a person skilled in the art in view of the present disclosure. In one preferred embodiment, the computer program product is executed primarily by the ultrasound server **106** of FIG. 1, with the other system devices of FIG. 1 performing simple input/output, display, and storage functions. In other preferred embodiments, the computer program product is distributed across the different systems of FIG. 1, with different algorithmic portions being carried out by different systems or subsystems. Ultrasound server **106** comprises a computer system that includes a cabinet, a display monitor, a keyboard, and a mouse, the mouse having one or more buttons for interacting with a graphical user interface. The cabinet typically houses a CD-ROM, zip, and/or floppy disc drive, system memory and a hard drive which can be utilized to store and retrieve software programs incorporating computer code that implements the preferred embodiments, data for use with the invention, and the like. An external hard drive is also shown in FIG. 1. Although CD-ROM, zip, and floppy discs represent common computer readable storage mediums, other computer readable storage media including tape, flash memory, system memory, and hard drives can be used. Additionally, a data signal embodied in a carrier wave, such as in a network including the Internet or an intranet, can form the computer readable storage medium.

[0106] Whereas many alterations and modifications of the present invention will no doubt become apparent to a person of ordinary skill in the art after having read the foregoing description, it is to be understood that the particular embodiments shown and described by way of illustration are in no way intended to be considered limiting. By way of example, although described supra in terms of adjunctive ultrasound screening, in view of the present disclosure one skilled in the art would readily be able to apply the thick-slice display apparatus of the preferred embodiments in the context of computerized tomography (CT) and/or magnetic resonance imaging (MRI) environments. In each case, individual image slices generated from CT scans or MRI scans of the breast are compounded so as to form thick-slice images of slab-like

portions of the breast along planes parallel to a standardized x-ray mammogram view plane, and the thick-slice images are displayed to the radiologist in close proximity to an x-ray mammogram of the breast to assist in interpreting that x-ray mammogram. Preferably, a single composite view of the whole breast is shown together with the thick-slice image views, these views having their gray-scale polarities toggled and/or remapped such that they are reminiscent of x-ray mammogram views taken from the standardized direction. By way of further example, the preferred embodiments described supra may also be used with different ultrasound modalities other than B-mode scans, including power or color Doppler modalities, and may also be used in conjunction with vibrational Doppler imaging (VDI) modalities. Therefore, reference to the details of the preferred embodiments are not intended to limit their scope, which is limited only by the scope of the claims set forth below.

1. A method for facilitating breast cancer screening, comprising:

acquiring raw ultrasound slices representing sonographic properties of a breast;

forming a volumetric representation of said sonographic properties from said raw ultrasound slices;

computing a two-dimensional thick-slice ultrasound image from said volumetric representation, said thick-slice ultrasound image representing said sonographic properties within a slab-like subvolume of the breast having a thickness greater than about 2 mm and less than about 20 mm;

displaying said thick-slice ultrasound image to a user during a viewing session;

computing a planar ultrasound image from said volumetric representation, said planar ultrasound image representing said sonographic properties along a substantially planar portion of the breast substantially nonparallel to said slab-like volume; and

electronically displaying said planar ultrasound image to the user during the viewing session.

2. The method of claim 1, wherein said thick-slice ultrasound image and said planar ultrasound image are simultaneously displayed to the user near each other to facilitate back-and-forth viewing therebetween.

3. The method of claim 2, wherein said slab-like subvolume is substantially parallel to a standard x-ray mammogram view plane.

4. The method of claim 1, said slab-like subvolume being substantially parallel to a standard x-ray mammogram view plane, further comprising displaying an x-ray mammogram image of the breast taken along said standard x-ray mammogram view plane to said user during the viewing session.

5. The method of claim 4, wherein said thick-slice ultrasound image, said planar ultrasound image, and said x-ray mammogram image are simultaneously displayed to the user near each other to facilitate back-and-forth viewing thereamong.

6. The method of claim 5, wherein said x-ray mammogram is displayed as an x-ray film on a backlit display.

7. The method of claim 6, wherein said thick-slice ultrasound image is electronically displayed.

8. The method of claim 7, wherein said planar ultrasound image is displayed on a high-brightness CRT monitor positioned adjacent to said thick-slice ultrasound image.

9. The method of claim 8, wherein said thick-slice ultrasound image is displayed on an LCD monitor.

10. The method of claim 9, wherein said thick-slice ultrasound image is enlarged or reduced to have the same spatial dimensions as the x-ray mammogram image.

11. The method of claim 1, said raw ultrasound slices comprising values according to a conventional ultrasound display convention in which higher reflection readings are displayed as brighter and lower reflection readings displayed as darker, further comprising inverting said thick-slice image to an inverted ultrasound display convention in which higher reflection readings are displayed as darker and lower reflection readings displayed as brighter.

12. The method of claim 11, further comprising:

segmenting said thick-slice image into a first region lying inside the breast and a second region lying outside the breast, said second region having bright pixels directly after said inverting; and

resetting said second region pixels to dark values, the resulting thick-slice image thereby being more reminiscent of a conventional x-ray mammogram image in said second region.

13. A method for computing a two-dimensional thick-slice ultrasound image from a volumetric ultrasound representation of a breast, said volumetric ultrasound representation comprising voxels, said thick-slice ultrasound image comprising pixels and corresponding to a first slab-like subvolume of the breast lying between a first border plane and a second border plane thereof, comprising:

identifying for each pixel location in the thick-slice ultrasound image a first voxel set corresponding to a voxel column in said volumetric ultrasound representation passing through that pixel location and extending from the first border plane to the second border plane;

computing one or more statistical properties of said first voxel set; and

computing an output value for that pixel location using said one or more statistical properties of said first voxel set.

14. The method of claim 13, said one or more statistical properties of said first voxel set incurring changes across different pixel locations in mass localities that are more significant for masses greater than a preselected size of interest and that are less significant for masses smaller than said preselected size of interest, mass lesions greater than said preselected size of interest being emphasized and mass lesions smaller than said preselected size of interest being de-emphasized in said thick-slice image.

15. The method of claim 14, said computing an output value comprising:

computing a histogram of values of said first voxel set; computing at least a portion of a cumulative distribution function from said histogram;

determining a first pixel level for which said cumulative distribution function is equal to a threshold, said threshold being a function of said preselected size of interest; and

setting said output value equal to said first pixel level.

16. The method of claim 15, said threshold being a fixed value equal to a preselected constant K times a ratio of (i) said preselected size of interest, to (ii) a distance between said first and second border planes.

17. The method of claim 16, wherein K is between about 0.20 and about 0.45.

18. The method of claim 15, said threshold being variable for different pixel locations in said thick-slice ultrasound image, said threshold being equal to a variable multiplier K times a ratio of (i) said preselected size of interest, to (ii) a distance between said first and second border planes.

19. The method of claim 18, wherein values of K are maintained within a range of about 0.20 to about 0.45.

20. The method of claim 13, the breast further having a second slab-like subvolume immediately adjacent to the first slab-like volume, further comprising:

identifying for each pixel location in the thick-slice ultrasound image a second voxel set corresponding to said voxel column extending from a first intermediate elevation in said first slab-like volume to a second intermediate location in said second slab-like volume, said first and second voxel sets having about the same number of voxels;

computing said one or more statistical properties of said second voxel set;

computing an alternative result for that pixel location using said one or more statistical properties of said second voxel set; and

if said alternative result indicates an ultrasound echo intensity less than that indicated by said output value, resetting said output value to said alternative result.

21. The method of claim 20, said volumetric ultrasound representation being formed from scans taken during a sweep of an ultrasound probe across the breast, wherein said second slab-like volume is closer to a locus of said ultrasound probe sweep than said first slab-like volume.

22-28. (canceled)

* * * * *

专利名称(译)	辅助超声处理和显示乳腺癌筛查		
公开(公告)号	US20090312640A1	公开(公告)日	2009-12-17
申请号	US12/546339	申请日	2009-08-24
[标]申请(专利权)人(译)	U系统公司		
申请(专利权)人(译)	U-SYSTEMS INC.		
当前申请(专利权)人(译)	U-SYSTEMS INC.		
[标]发明人	WANG SHIH PING CHIN DONALD RAO FANGYI KARSSEMEIJER NICO		
发明人	WANG, SHIH-PING CHIN, DONALD RAO, FANGYI KARSSEMEIJER, NICO		
IPC分类号	A61B8/14 G06K9/00 A61B6/04 A61B6/00 A61B8/00 A61B8/08		
CPC分类号	A61B6/463 A61B8/5215 A61B6/5241 A61B6/5247 A61B6/563 A61B8/0825 A61B8/406 A61B8/4281 A61B8/4405 A61B8/462 A61B8/463 A61B8/467 A61B8/5238 A61B8/565 A61B6/502 A61B8/464 A61B8/ /465 A61B8/466		
优先权	60/326715 2001-10-03 US 60/252946 2000-11-24 US 60/415385 2002-10-01 US		
外部链接	Espacenet USPTO		

摘要(译)

描述了辅助超声乳房摄影系统和相关方法，其包括辅助超声显示器，其配置用于快速，直观，交互式观察从体积超声扫描得到的数据，该数据显示在常规X射线乳房X线照片显示器附近。描述了用于在厚切片图像阵列，所选择的放大的厚切片图像和平面超声视图之间导航的优选实施例，包括优选实施例，其中当光标在活动中移动时实时更新平面超声视图厚切片图像。在一个优选实施例中，厚切片图像在显示之前被反转，图像的非乳房区域优选地被分割出来并重置为暗。对于在分析常规X射线乳房X线照片方面具有多年专业知识的放射科医师而言，倒置的厚切片图像具有更为熟悉的意义。例如，与非反转的厚切片图像相比，反转的厚切片图像允许更容易地消除良性特征。还描述了用于从体积扫描数据计算厚切片图像值的优选实施例，其强调所得到的厚切片图像中的较大质量损伤，并且补偿跨越厚切片区域边界的质量损伤。

