



US 20180049719A1

(19) **United States**

(12) **Patent Application Publication**
XU et al.

(10) **Pub. No.: US 2018/0049719 A1**

(43) **Pub. Date: Feb. 22, 2018**

(54) **BUBBLE-INDUCED COLOR DOPPLER
FEEDBACK DURING HISTOTRIPSY**

A61B 5/00 (2006.01)

A61B 17/225 (2006.01)

A61B 17/22 (2006.01)

A61B 8/00 (2006.01)

(71) Applicants: **Zhen XU**, Ann Arbor, MI (US); **Ryan M. MILLER**, Ann Arbor, MI (US); **Adam D. MAXWELL**, Ann Arbor, MI (US); **Charles A. CAIN**, Ann Arbor, MI (US)

(52) **U.S. Cl.**

CPC *A61B 8/488* (2013.01); *G01S 15/899*

(2013.01); *A61B 5/0075* (2013.01); *G01S*

15/8979 (2013.01); *A61B 17/2258* (2013.01);

A61B 8/543 (2013.01); *A61B 5/0035*

(2013.01); *A61B 8/54* (2013.01); *A61B 5/4848*

(2013.01); *A61B 5/0059* (2013.01); *G01S*

15/8981 (2013.01); *A61B 17/22012* (2013.01)

(72) Inventors: **Zhen XU**, Ann Arbor, MI (US); **Ryan M. MILLER**, Ann Arbor, MI (US); **Adam D. MAXWELL**, Ann Arbor, MI (US); **Charles A. CAIN**, Ann Arbor, MI (US)

(21) Appl. No.: **15/713,441**

(57)

ABSTRACT

(22) Filed: **Sep. 22, 2017**

Related U.S. Application Data

(63) Continuation of application No. 14/046,024, filed on Oct. 4, 2013, now abandoned.

(60) Provisional application No. 61/710,172, filed on Oct. 5, 2012.

Publication Classification

(51) **Int. Cl.**

A61B 8/08 (2006.01)

G01S 15/89 (2006.01)

A Histotripsy therapy system is provided that can include any number of features. In some embodiments, the system includes a high voltage power supply, a pulse generator electrically coupled to at least one signal switching amplifier, at least one matching network electrically coupled to the signal switching amplifier(s), and an ultrasound transducer having at least one transducer element. The Histotripsy therapy system can further include an ultrasound Doppler imaging system. The Doppler imaging system and the Histotripsy therapy system can be synchronized to enable color Doppler acquisition of the fractionation of tissue during Histotripsy therapy. Methods of use are also described.

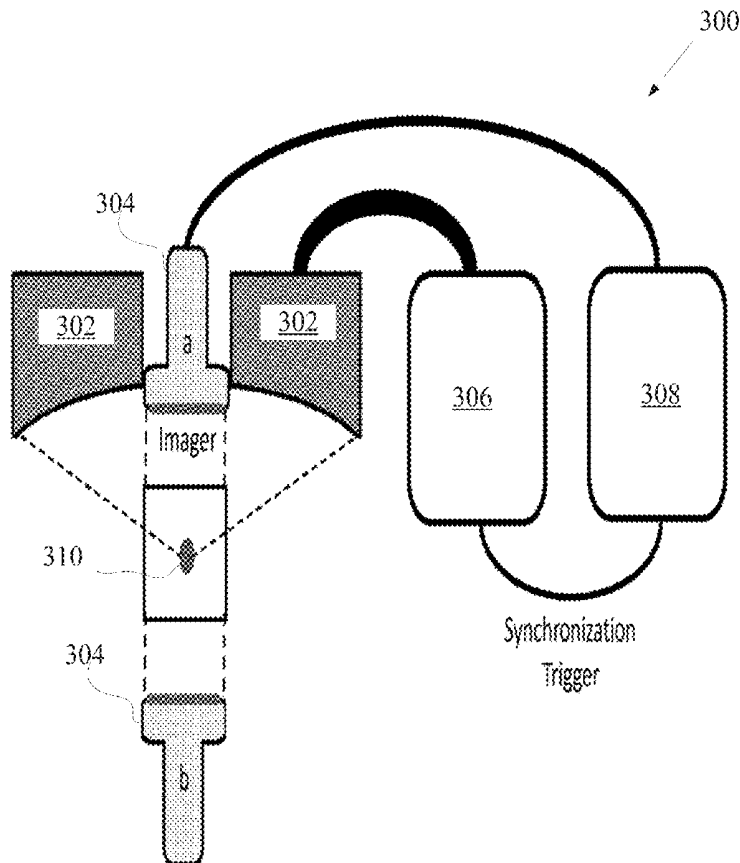


Fig. 1A

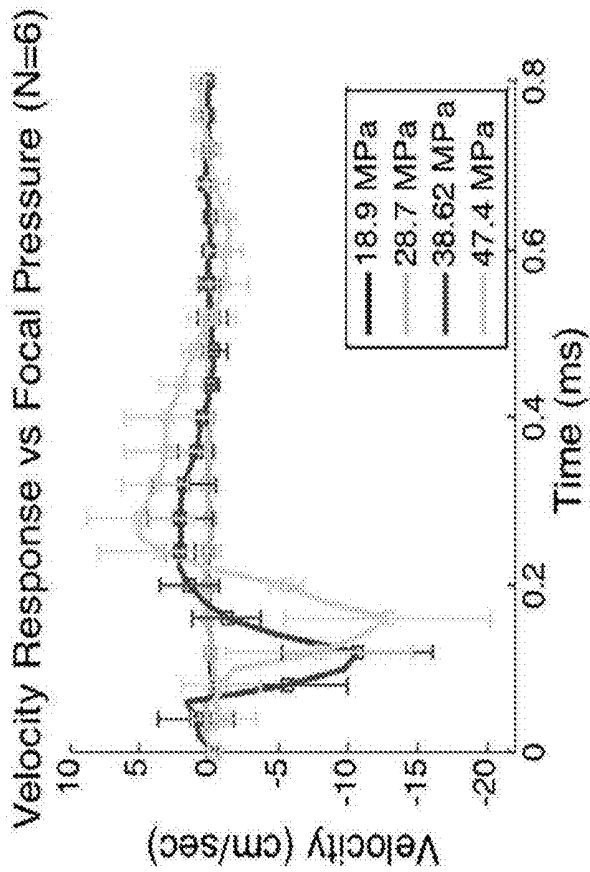
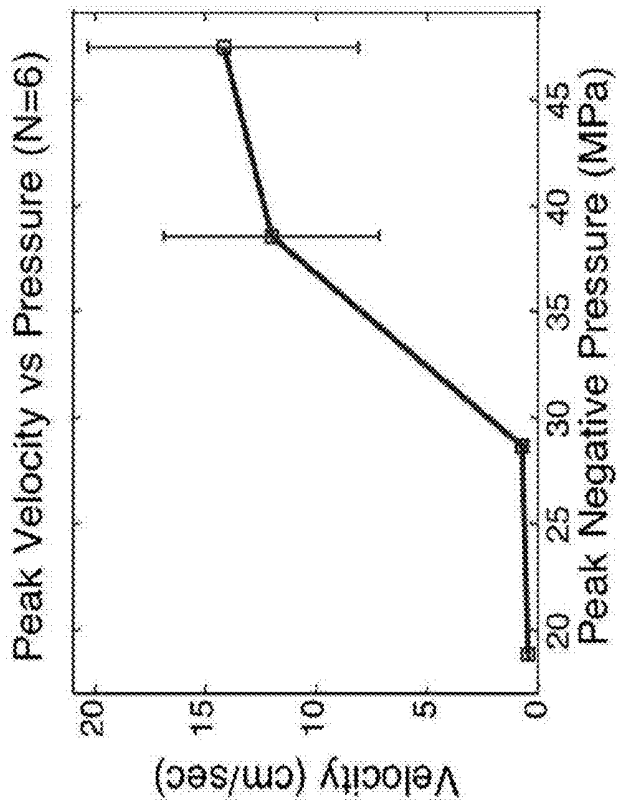


Fig. 1B



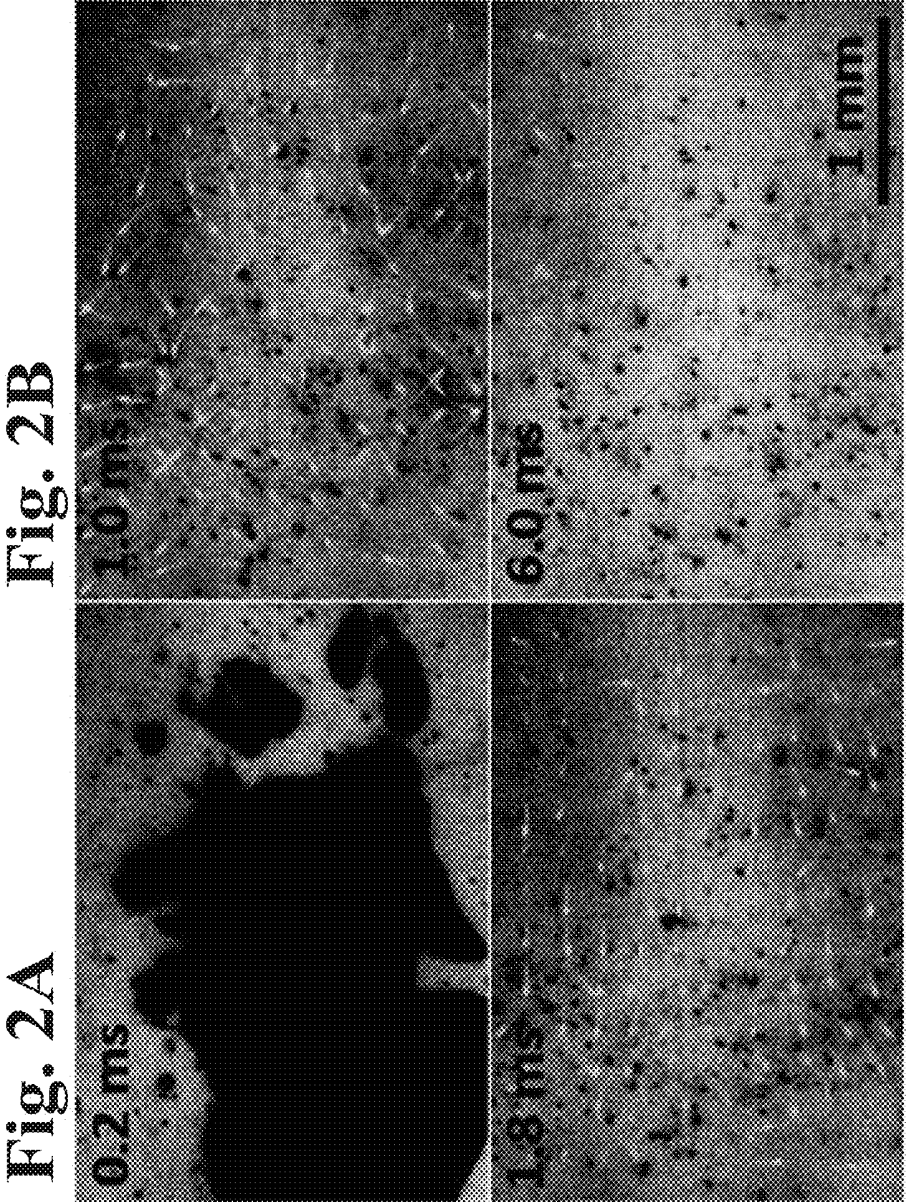


Fig. 2A

Fig. 2B

Fig. 2C

Fig. 2D

Fig. 3

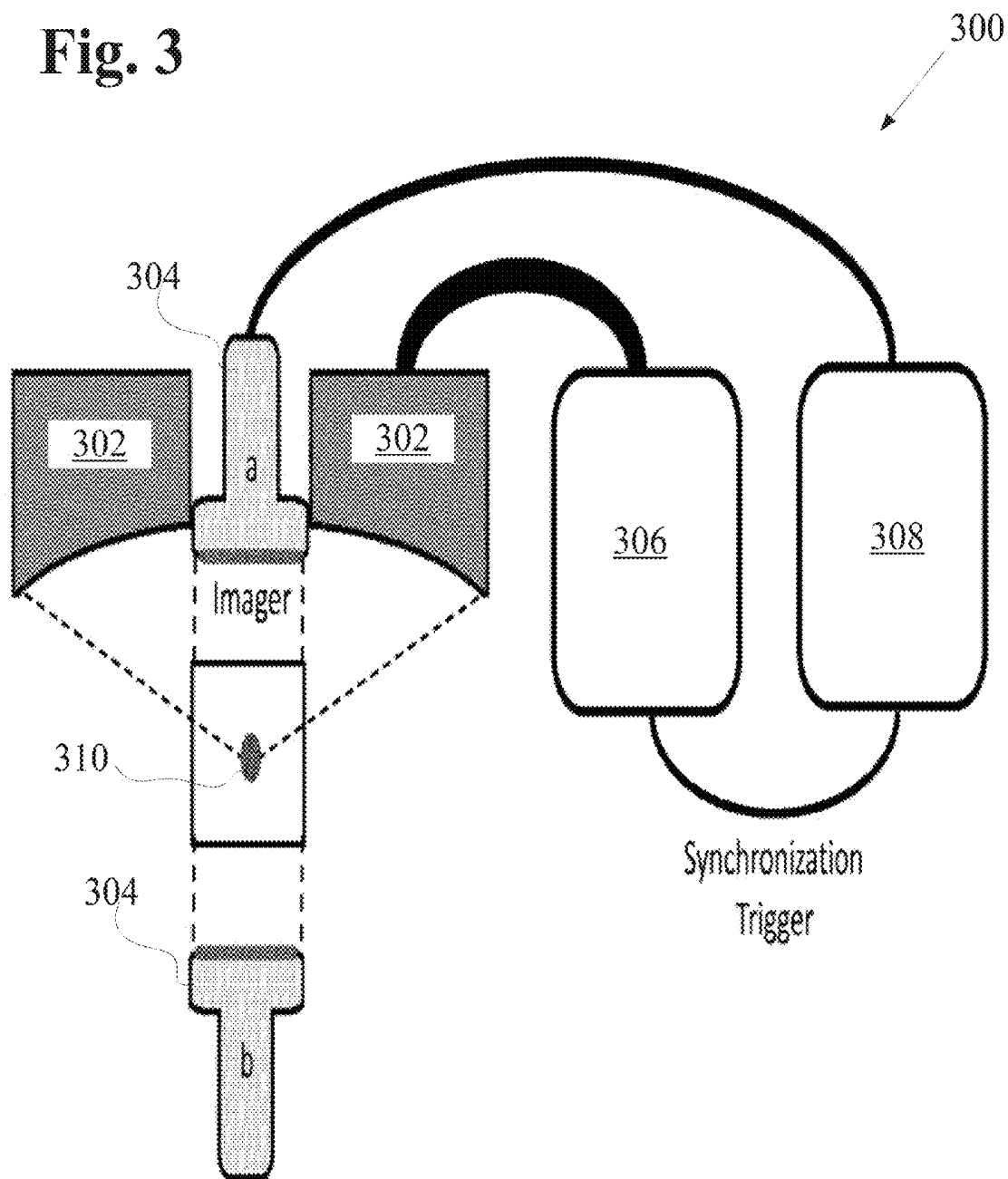
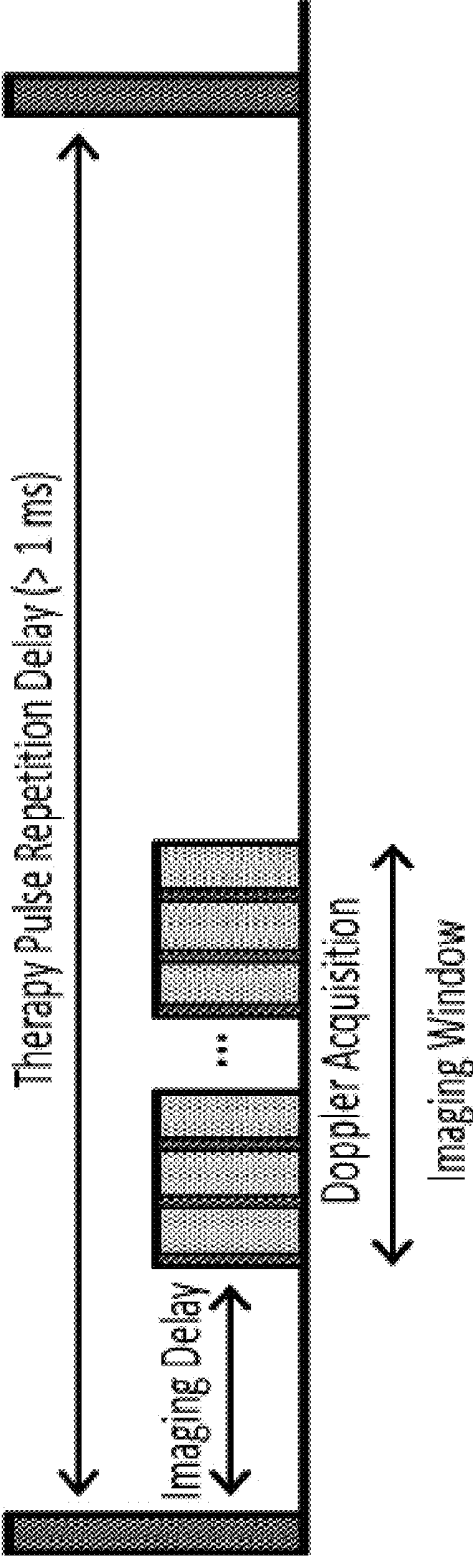


Fig. 4




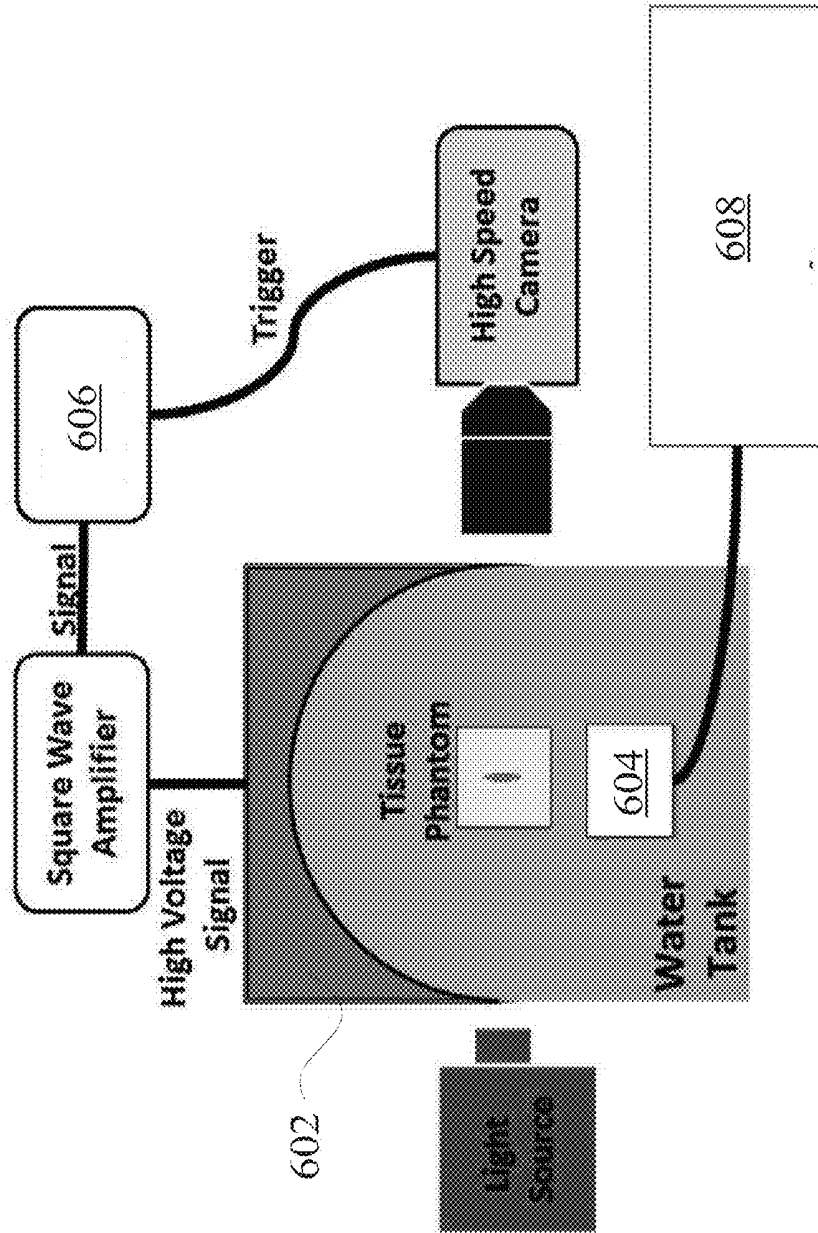


Fig. 5

Fig. 6



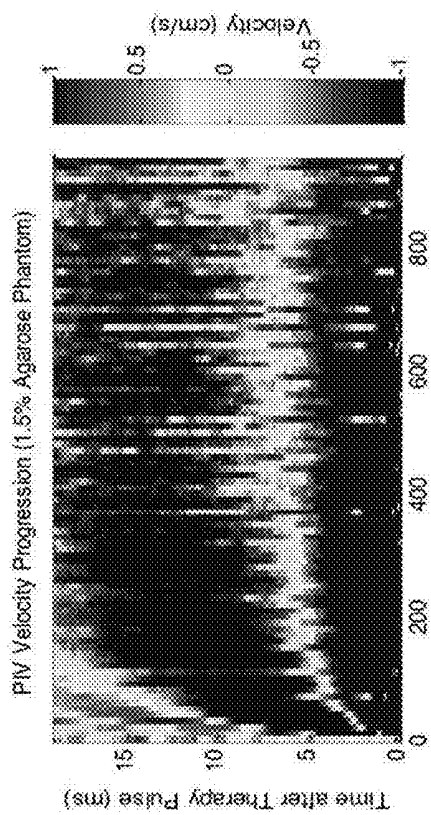


Fig. 7A

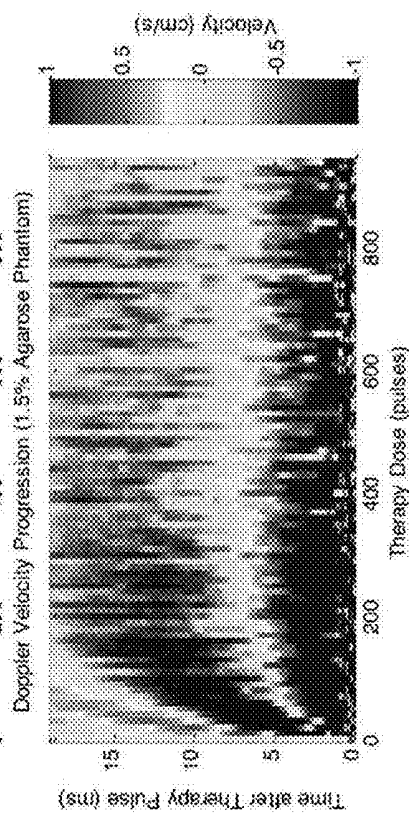


Fig. 7B

Fig. 8

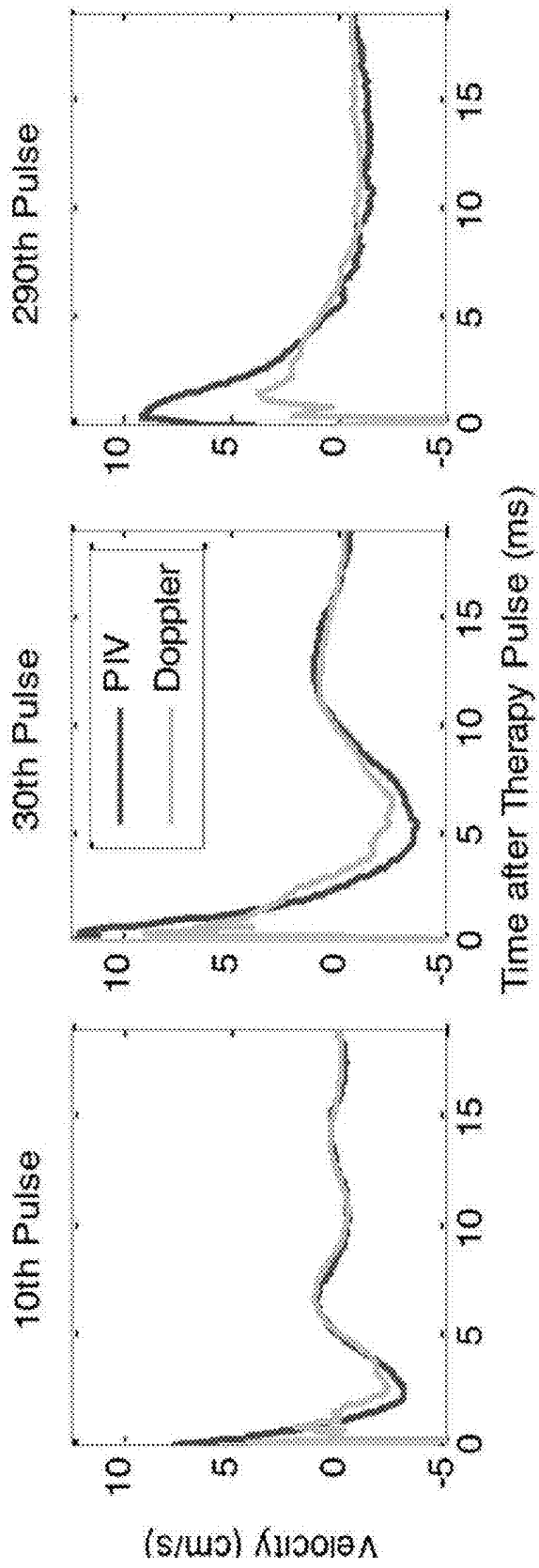


Fig. 9

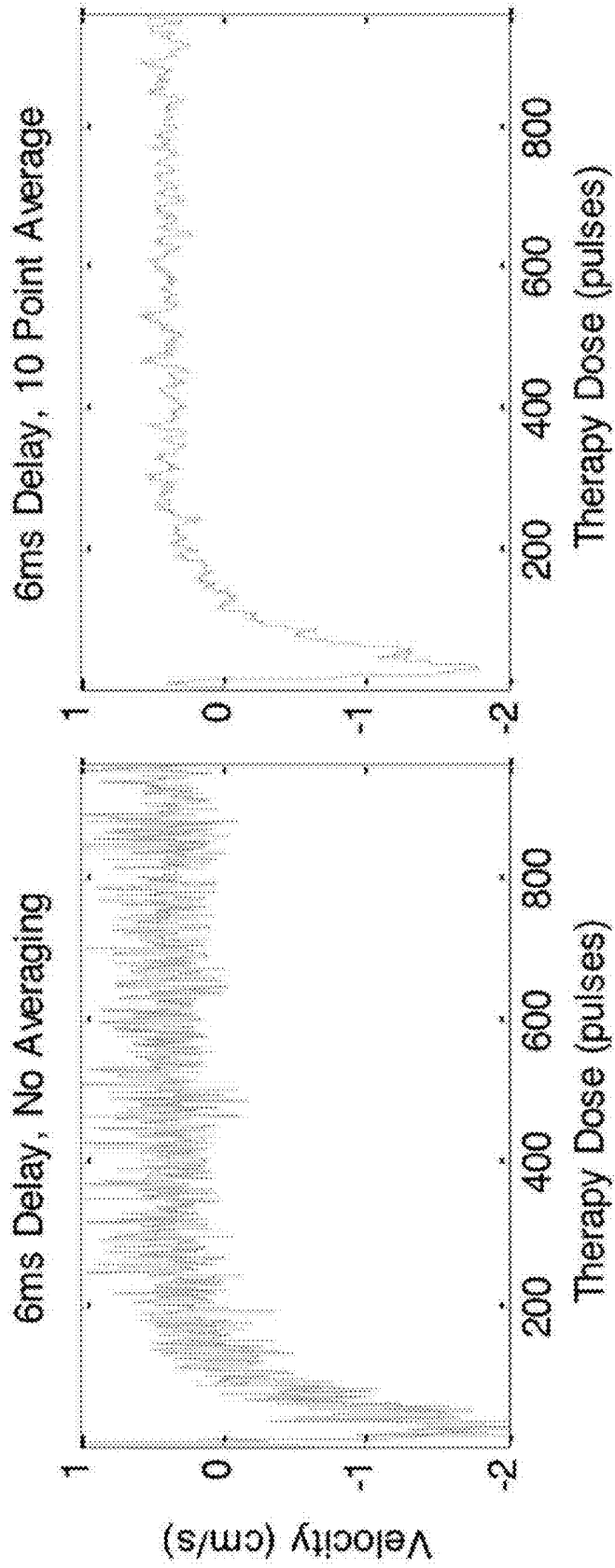


Fig. 10

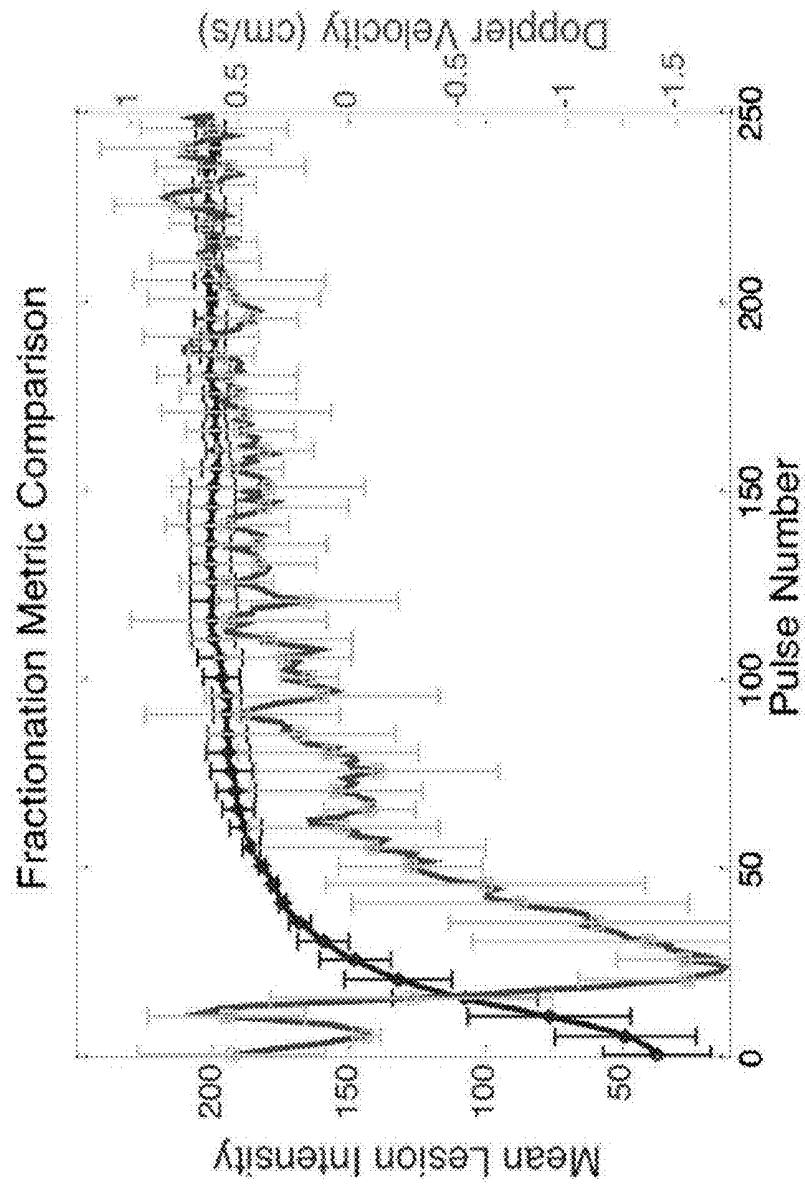


Fig. 11

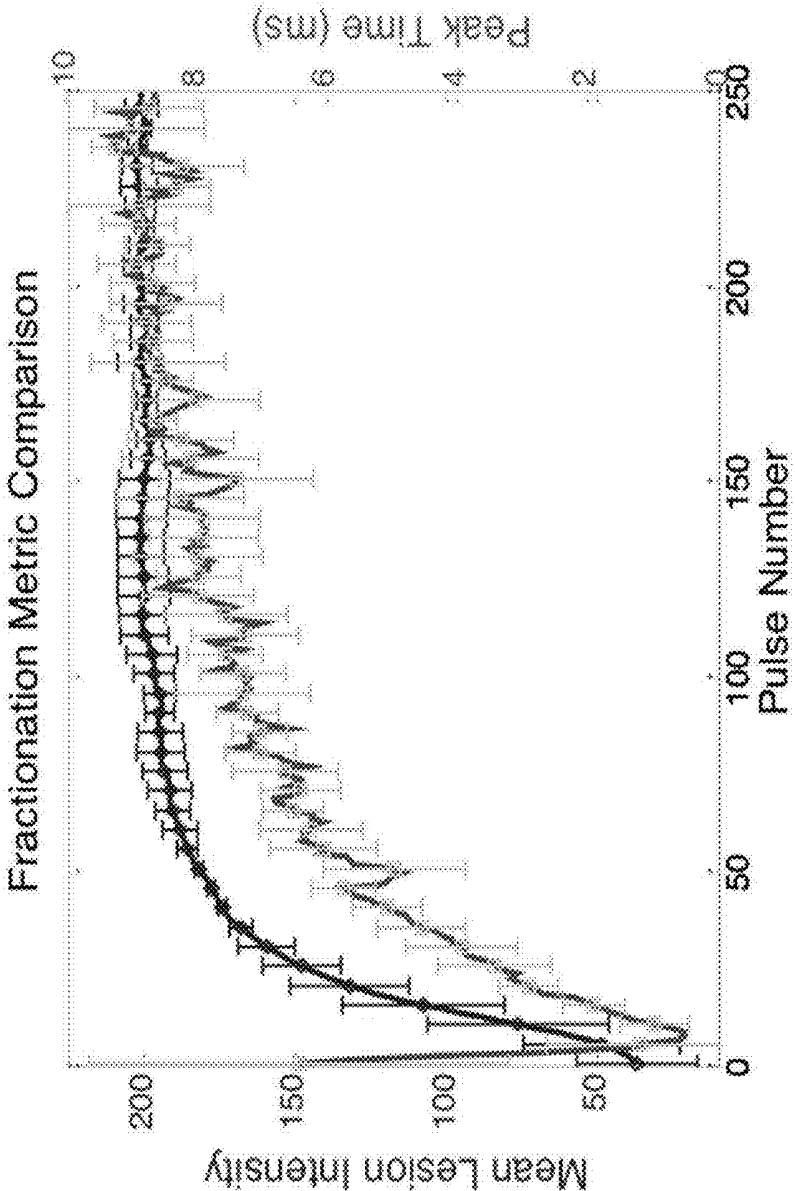


Fig. 12




Fig. 13

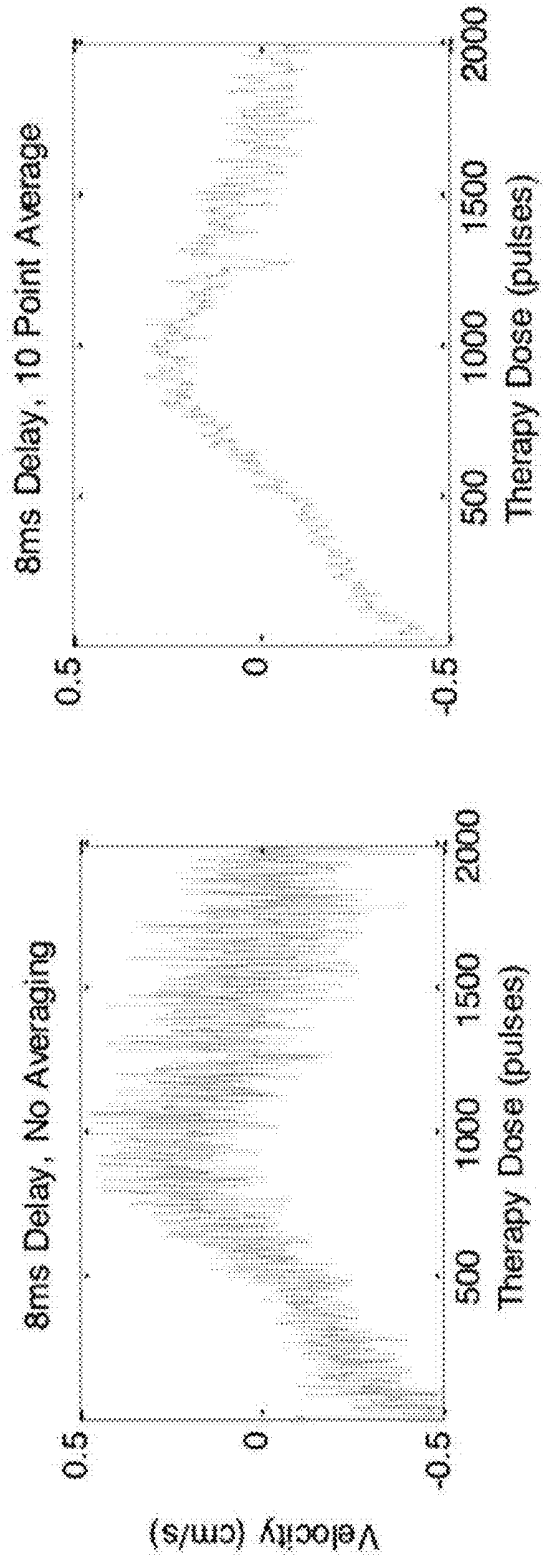


Fig. 14

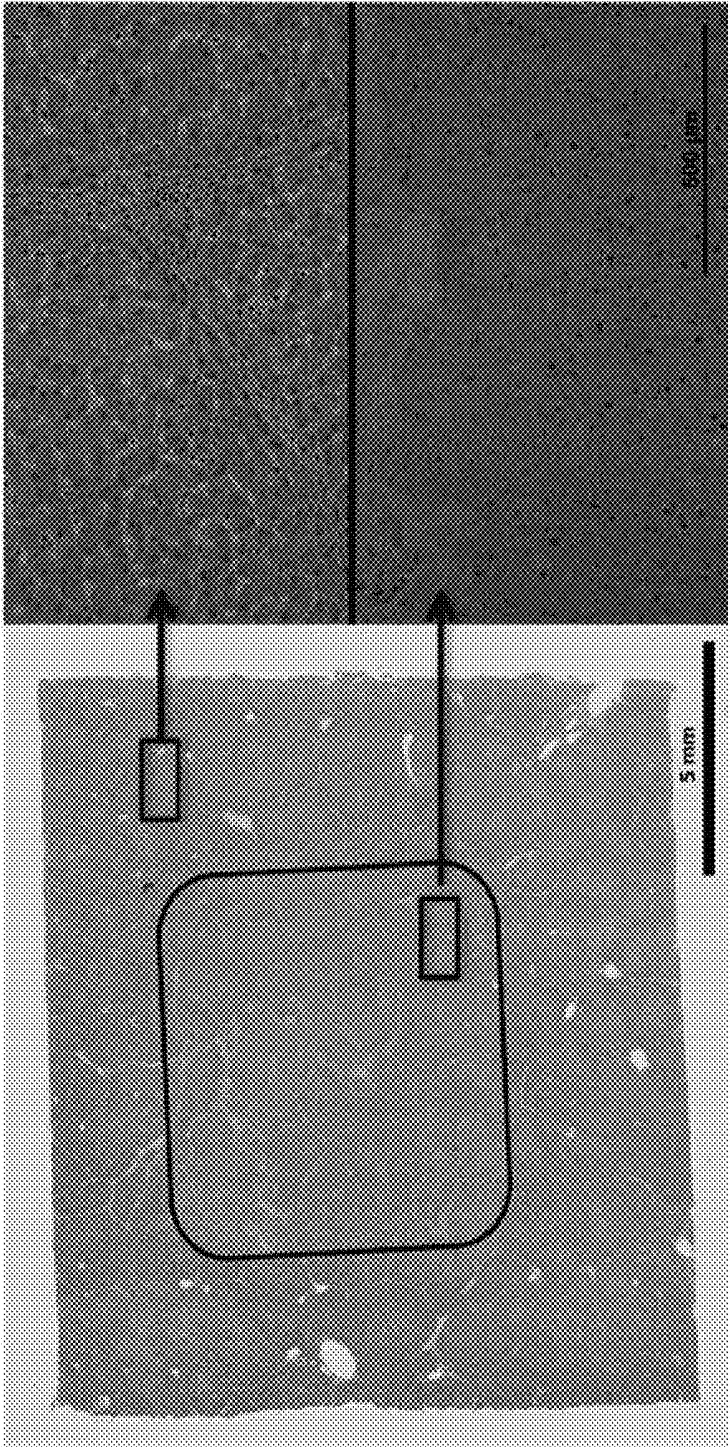


Fig. 15


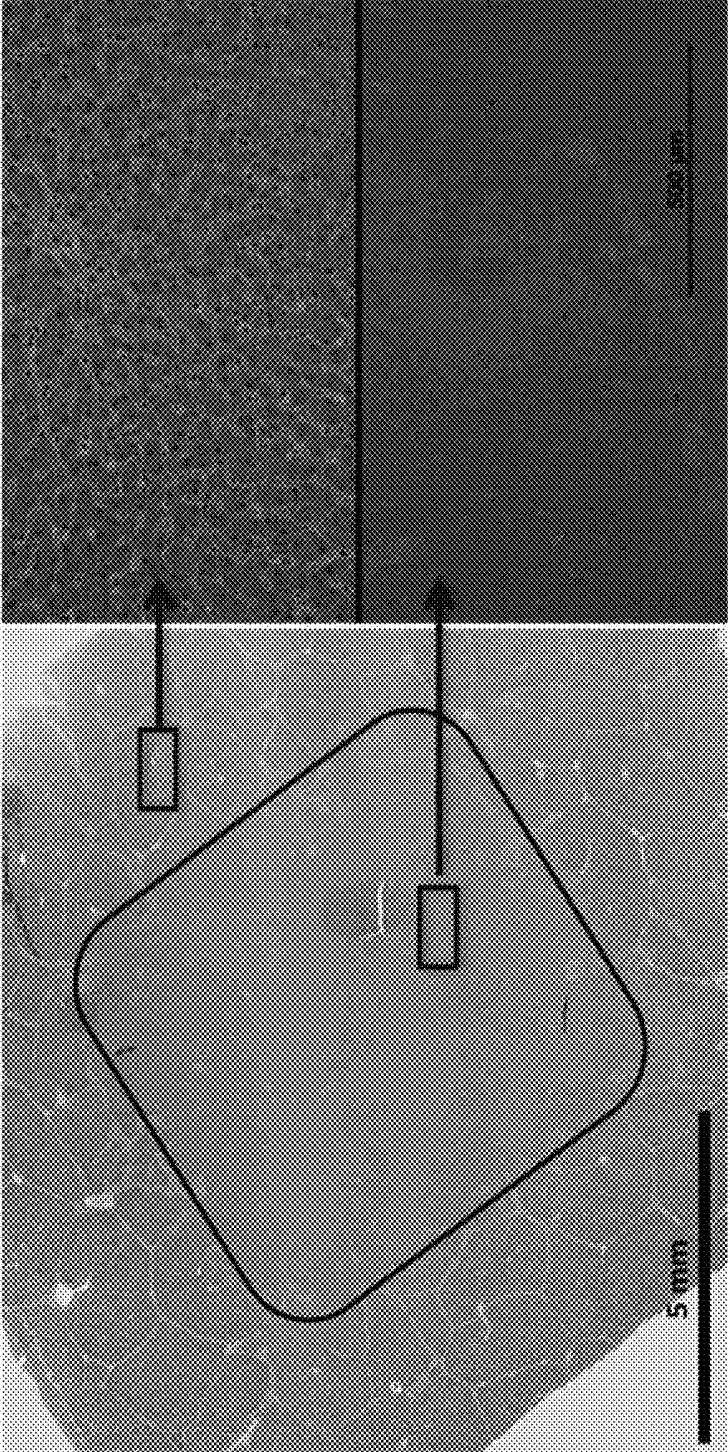


Fig. 16



**BUBBLE-INDUCED COLOR DOPPLER
FEEDBACK DURING HISTOTRIPSY****CROSS REFERENCE TO RELATED
APPLICATIONS**

[0001] This application is a continuation of U.S. application Ser. No. 14/046,024, filed Oct. 4, 2013, which application claims the benefit under 35 U.S.C. 119 of U.S. Provisional Application No. 61/710,172, filed Oct. 5, 2012, titled "Real-Time Elastography-Based Feedback During Histotripsy", which applications are incorporated by reference as if fully set forth herein.

GOVERNMENT INTEREST

[0002] This invention was made with Government support under EB008998, awarded by the National Institutes of Health. The Government has certain rights in the invention.

INCORPORATION BY REFERENCE

[0003] All publications and patent applications mentioned in this specification are herein incorporated by reference to the same extent as if each individual publication or patent application was specifically and individually indicated to be incorporated by reference.

FIELD

[0004] This disclosure generally relates to applying therapeutic ultrasound to tissue. More specifically, this disclosure relates to real-time Doppler-based feedback during Histotripsy therapy to tissue.

BACKGROUND

[0005] Imaging feedback during treatment is essential for ensuring high accuracy and safety of minimally invasive and non-invasive ablation therapies. Radiofrequency ablation (RFA) is currently the standard local ablation therapy. No imaging feedback is typically used to monitor RFA treatment. The treatment completion is usually determined by calculation of the delivered thermal dose necessary to destroy all cells within a treated volume. However, accurate dose calculation is nearly impossible to achieve. MRI-based thermometry is being investigated for RFA monitoring, but this technique requires an open magnet MRI system, which is not clinically available.

[0006] High intensity focused ultrasound (HIFU) thermal therapy is a relatively new and promising non-invasive ablation technology. Currently HIFU systems mostly use MRI thermometry to monitor the thermal dose during treatment, but the use of MRI for such long procedures is expensive. As a state of art imaging feedback for HIFU, MRI thermometry measures the temperature change in the tissue to derive the treatment tissue effect, but not the direct change in the tissue. In addition to MR thermometry, ultrasound and MRI elastography and other ultrasound-based feedback have also been investigated to monitor the tissue elasticity increase produced by the HIFU treatment.

[0007] Histotripsy is a new non-invasive and non-thermal ultrasound ablation technology. It uses high intensity, micro-second-long ultrasound pulses to control cavitating bubble clouds for tissue fractionation. In some embodiments, generating Histotripsy pulses comprises generating short (<20 μ sec), high pressure (peak negative pressure >10 MPa)

shockwave ultrasound pulses at a duty cycle <5%. The Histotripsy-induced cavitation cloud can be monitored through ultrasound imaging and provides an inherent feedback for targeting. The tissue fractionation induced by Histotripsy appears as a dark zone on B-mode ultrasound images due to speckle amplitude reduction, although significant speckle reduction is only observed when substantial tissue fractionation is generated. It is also difficult to identify a level of backscatter amplitude reduction corresponding to complete tissue fractionation or a specific fractionation level corresponding to complete tissue death, due to the variation in speckle amplitude across different tissue samples.

[0008] As the tissue elasticity decreases with increasing fractionation, Histotripsy tissue fractionation can also be monitored using ultrasound elastography. Ultrasound elastography can detect the elasticity decrease in the fractionated tissue and shows a higher sensitivity to monitor the early stage tissue fractionation compared to speckle amplitude reduction. Unlike conventional ultrasound imaging that portrays the difference in acoustic impedance of the tissue, ultrasound elastography measures the difference in tissue stiffness. The tissue stiffness can be described by an elastic modulus, which can be measured by the tissue's resistance to deformation, in compression/tension (Young's modulus) or in shear (shear modulus). Tissue deformation occurs in response to a stress being applied to the tissue. The stress can be applied by a manual push from the clinician's finger or imaging probe. It can also be applied by acoustic radiation force from an ultrasound pulse. The dynamic displacement response of the soft tissue is typically monitored using cross-correlation between adjacent ultrasound image frames of the displayed tissue. The amplitude and temporal characteristics of the displacement, including peak displacement, time to peak displacement, and tissue velocity, can then be extracted and used to calculate the elastic modulus of the tissue

[0009] Current elastography methods require relatively large processing times compared to the pulse frequency of ultrasound therapy such as Histotripsy. These processing times can be from a fraction of a second to several seconds in length, which cannot be obtained simultaneously with the application of several to a thousand Histotripsy pulses a second.

SUMMARY

[0010] In some embodiments, generating Histotripsy pulses comprises generating short (<20 μ sec), high pressure (peak negative pressure >10 MPa) shockwave ultrasound pulses at a duty cycle <5%.

[0011] An ultrasound system configured to monitor bubble-induced color Doppler during Histotripsy treatment is provided, comprising a ultrasound therapy transducer configured to transmit Histotripsy pulses into tissue having a pulse length less than 20 μ sec, a peak negative pressure greater than 10 MPa, and a duty cycle less than 5%, an ultrasound Doppler imaging system configured to transmit ultrasound imaging pulses along the propagation direction of the Histotripsy pulses and generate color Doppler imaging of the tissue from the transmitted ultrasound imaging pulses, and a control system configured to synchronize transmission of the ultrasound imaging pulses with transmission of the Histotripsy pulses to monitor Histotripsy tissue fractionation in real-time with the Doppler imaging.

[0012] In some embodiments, the control system is configured to set specific Doppler parameters to follow the tissue displacement using color Doppler, such as a time delay between a Doppler pulse packet and the Histotripsy pulses, a pulse repetition frequency of the Doppler pulse packet, and a number of frames in the Doppler pulse packet.

[0013] In one embodiment, the ultrasound therapy transducer includes a central hole configured to house an ultrasound imaging transducer of the ultrasound Doppler imaging system so as to align the ultrasound imaging transducer along a propagation path of the Histotripsy pulses.

[0014] In another embodiment, the control system is configured to synchronize transmission of the ultrasound imaging pulses with transmission of the Histotripsy pulses by sending a trigger signal from the control system to the ultrasound Doppler imaging system during the transmission of each Histotripsy pulse plus a predetermined time delay.

[0015] In some embodiments, a pulse repetition frequency (PRF) and a number of frames of Doppler imaging are set by the ultrasound Doppler imaging system so color Doppler flow velocity increases as a degree of tissue fractionation generated by the Histotripsy pulses increases.

[0016] In another embodiment, an expansion of a temporal profile of a color Doppler velocity increases as a degree of tissue fractionation generated by the Histotripsy pulses increases.

[0017] In some embodiments, a rapid expansion of a temporal profile of a color Doppler velocity corresponds to microscopic cellular damage, while a slow expansion of the temporal profile of the color Doppler velocity corresponds to macroscopic tissue structural damage generated by the Histotripsy pulses.

[0018] In one embodiment, a saturation or decrease of expansion of a temporal profile of a color Doppler velocity indicates complete homogenization and liquefaction of the tissue.

[0019] In some embodiments, a PRF and number of frames of color Doppler imaging is controlled by the ultrasound Doppler imaging system such that a direction of a color Doppler flow changes from towards an imaging transducer to away from the imaging transducer when the tissue is sufficiently fractionated by the Histotripsy pulses.

[0020] In one embodiment, a wall filter value can be set by the ultrasound Doppler imaging system such that a color Doppler flow map matches the tissue when it has been fractionated by the Histotripsy pulses.

[0021] In some embodiments, 2D or 3D images of the tissue can be reconstructed by scanning a focus of the ultrasound therapy transducer and collecting a color Doppler map at a position of the focus.

[0022] In other embodiments, the Doppler imaging can be configured to monitor vessel function and cardiac function during the transmission of Histotripsy pulses.

[0023] In some embodiments, the ultrasound Doppler imaging system can display different colors to distinguish tissue motion from blood flow.

[0024] A method of monitoring Doppler-based feedback during Histotripsy treatment is provided, comprising the steps of transmitting Histotripsy pulses into tissue having a pulse length less than 20 μ sec, a peak negative pressure greater than 10 MPa, and a duty cycle less than 5% with an ultrasound therapy transducer, obtaining color Doppler acquisition of the tissue during transmission of the Histotripsy pulses with an ultrasound imaging system, and syn-

chronizing the color Doppler acquisition with the transmission of Histotripsy pulses with a control system.

[0025] In some embodiments, the method comprises setting specific Doppler parameters to follow tissue displacement using color Doppler acquisition.

[0026] In other embodiments, the method comprises obtaining color Doppler acquisition along a propagation line of the Histotripsy pulses to measure tissue displacement of the tissue.

[0027] In one embodiment, the synchronizing step comprises sending a trigger signal to the ultrasound imaging system from the control system during the transmission of each Histotripsy pulse plus a predetermined time delay.

[0028] In another embodiment, the method comprises setting a PRF and number of frames for color Doppler acquisition such that a color Doppler flow velocity increases with an increasing degree of tissue fractionation generated by the Histotripsy pulses.

[0029] In some embodiments, the method comprises setting a PRF and number of frames for color Doppler acquisition such that a direction of a color Doppler flow changes from towards the ultrasound imaging system to away from the ultrasound imaging system when the tissue is sufficiently fractionated by the Histotripsy pulses.

[0030] In another embodiment, the method comprises setting a wall filter value such that a color Doppler flow map matches a fractionated tissue region generated by the Histotripsy pulses.

[0031] In some embodiments, the method comprises reconstructing 2D or 3D Doppler imaging of a fractionated tissue by scanning a focus of the ultrasound therapy system and collecting a color Doppler map at a position of the focus.

[0032] In other embodiments, the method comprises monitoring vessel function and cardiac function during transmission of the Histotripsy pulses.

[0033] In some embodiments, the method comprises distinguishing tissue displacement from blood flow with the color Doppler acquisition.

[0034] In other embodiments, the color Doppler acquisition can be used to monitor and indicate microscopic cellular damage versus macroscopic tissue structure homogenization.

BRIEF DESCRIPTION OF THE DRAWINGS

[0035] The novel features of the invention are set forth with particularity in the claims that follow. A better understanding of the features and advantages of the present invention will be obtained by reference to the following detailed description that sets forth illustrative embodiments, in which the principles of the invention are utilized, and the accompanying drawings of which:

[0036] FIGS. 1A-1B: Velocity observed at the therapy focus following Histotripsy pulses of various focal pressures (left), along with a plot of the average peak velocity observed for each of the tested pressures (right) within the focal region in the agarose phantom using particle image velocimetry (PIV). Without cavitation generated by the Histotripsy pulse, no appreciable motion was detected. When cavitation occurred, the peak motion detected by PIV increased with increasing Histotripsy pulse pressure.

[0037] FIGS. 2A-2D: High speed images of the focal region 50 pulses into treatment (therapy applied from the right) with PIV velocity map overlays showing the Histotripsy bubble cloud (top left), chaotic motion immediately

after the collapse of the bubble cloud (top right), and finally coherent motion, including a push away from the transducer (bottom left) and subsequent rebound (bottom right).

[0038] FIG. 3 describes the setup of the Histotripsy system and ultrasound imaging system to perform the bubble-induced color Doppler feedback for Histotripsy treatment.

[0039] FIG. 4 demonstrates one synchronization scheme to trigger the Doppler pulse transmission and acquisition using a signal sent out from the Histotripsy system at an appropriate delay time (negative or positive) after the transmission of the Histotripsy pulse.

[0040] FIG. 5: Steered focal locations for the 219 foci with alternating 1 mm spaced grids of 7×7 foci and 6×6 foci. The axial layers are separated by 1 mm, but with the 6×6 grids offset laterally from the 7×7 layers by 0.5 mm

[0041] FIG. 6: Experimental setup with 500 kHz transducer mounted to the side of a water tank with 5 MHz imaging probe mounted opposite the therapy and aligned along the therapy axis. The Phantom high speed camera was positioned perpendicular to the therapy axis.

[0042] FIGS. 7A-7B: Plots showing the velocity estimates from PIV (top) and Doppler (bottom) after every 10 therapy pulses.

[0043] FIG. 8: Individual velocity plots for the 19 ms after the therapy pulse after 10 therapy pulses (left), 30 therapy pulses (center), and 290 therapy pulses (right) showing good agreement between PIV and Doppler in measured velocity after the initial chaotic motion.

[0044] FIG. 9: Doppler velocity progression at a 6 ms delay from therapy pulse without averaging (left) and with a 10 pulse running average (right).

[0045] FIG. 10: A comparison of the Doppler velocity fractionation metric versus the mean lesion intensity metric in the damage indicating RBC layer (N=6). Both Doppler velocity and the lesion progress rapidly increased until ~100 pulses.

[0046] FIG. 11: Alternative progression metric, time to peak velocity, shows less variation and captures the same rapid change up to 100 pulses shown in the mean lesion intensity, with a slower continued progression up to 200 pulses.

[0047] FIG. 12: Plot showing the velocity estimates from Doppler after every therapy pulse in ex vivo porcine liver.

[0048] FIG. 13: Doppler velocity progression in ex vivo liver without averaging (left) and with a 10 point running average (right).

[0049] FIG. 14: Histological images of the lesion after 50 therapy pulses. Macroscopic image (left) shows little large-scale homogenization, however widespread mechanical fractionation is visible microscopically (bottom right) compared to control (top right).

[0050] FIG. 15: Histological images of the lesion after 200 therapy pulses. Macroscopic image (left) shows clear large-scale homogenization, with increased mechanical fractionation visible microscopically (bottom right) compared to control (top right).

[0051] FIG. 16: Histological images of the lesion after 500 therapy pulses. Macroscopic image (left) shows complete large-scale homogenization, with near complete homogenization visible microscopically as well (bottom right) compared to control (top right).

DETAILED DESCRIPTION

[0052] This disclosure introduces new imaging feedback systems and methods using bubble-induced color Doppler to monitor the Histotripsy-induced tissue fractionation in real-time. This novel approach can monitor the level of tissue fractionation generated by Histotripsy with improved sensitivity compared to backscatter speckle amplitude reduction and can be implemented in real-time during Histotripsy treatment. Further areas of applicability will become apparent from the description provided herein. The description and specific examples in this summary are intended for purposes of illustration only and are not intended to limit the scope of the present disclosure.

[0053] Example embodiments will now be described more fully with reference to the accompanying drawings. Embodiments are provided so that this disclosure will be thorough, and will fully convey the scope to those who are skilled in the art. Numerous specific details are set forth such as examples of specific components, devices, and methods, to provide a thorough understanding of embodiments of the present disclosure.

[0054] In some example embodiments, well-known processes, well-known device structures, and well-known technologies are not described in detail.

[0055] The terminology used herein is for the purpose of describing particular example embodiments only and is not intended to be limiting. As used herein, the singular forms “a,” “an,” and “the” may be intended to include the plural forms as well, unless the context clearly indicates otherwise. The terms “comprises,” “comprising,” “including,” and “having,” are inclusive and therefore specify the presence of stated features, integers, steps, operations, elements, and/or components, but do not preclude the presence or addition of one or more other features, integers, steps, operations, elements, components, and/or groups thereof. The method steps, processes, and operations described herein are not to be construed as necessarily requiring their performance in the particular order discussed or illustrated, unless specifically identified as an order of performance. It is also to be understood that additional or alternative steps may be employed.

[0056] When an element or layer is referred to as being “on,” “engaged to,” “connected to,” or “coupled to” another element or layer, it may be directly on, engaged, connected or coupled to the other element or layer, or intervening elements or layers may be present. In contrast, when an element is referred to as being “directly on,” “directly engaged to,” “directly connected to,” or “directly coupled to” another element or layer, there may be no intervening elements or layers present. Other words used to describe the relationship between elements should be interpreted in a like fashion (e.g., “between” versus “directly between,” “adjacent” versus “directly adjacent,” etc.). As used herein, the term “and/or” includes any and all combinations of one or more of the associated listed items.

[0057] Although the terms first, second, third, etc. may be used herein to describe various elements, components, regions, layers and/or sections, these elements, components, regions, layers and/or sections should not be limited by these terms. These terms may be only used to distinguish one element, component, region, layer or section from another region, layer or section. Terms such as “first,” “second,” and other numerical terms when used herein do not imply a sequence or order unless clearly indicated by the context.

Thus, a first element, component, region, layer or section discussed below could be termed a second element, component, region, layer or section without departing from the teachings of the example embodiments.

[0058] Spatially relative terms, such as “inner,” “outer,” “beneath,” “below,” “lower,” “above,” “upper,” and the like, may be used herein for ease of description to describe one element or feature’s relationship to another element(s) or feature(s) as illustrated in the figures. Spatially relative terms may be intended to encompass different orientations of the device in use or operation in addition to the orientation depicted in the figures. For example, if the device in the figures is turned over, elements described as “below” or “beneath” other elements or features would then be oriented “above” the other elements or features. Thus, the example term “below” can encompass both an orientation of above and below. The device may be otherwise oriented (rotated 90 degrees or at other orientations) and the spatially relative descriptors used herein interpreted accordingly.

[0059] In this disclosure, an innovative bubble-induced Color Doppler approach is described to monitor Histotripsy fractionation in real-time.

[0060] When a cavitation cloud is generated in tissue by a Histotripsy pulse, substantial motion is induced in the focal zone and observable on color Doppler synchronized with the Histotripsy pulse. Without cavitation, the motion is negligible.

[0061] To measure the motion of the focal volume exposed to Histotripsy, an experiment was conducted in transparent agarose hydrogel tissue mimicking phantom with a thin layer (<1 mm) of glass beads with an 8-12 micron mean diameter. The motion in the focal volume exposed to Histotripsy was measured by tracking the motion of the glass beads using high-speed images and particle image velocimetry (PIV). This phantom was treated with 2-cycle pulses at estimated peak negative pressures of 18.9-47.4 MPa using a 500 kHz transducer. This transducer is composed of 32 elements with 50 mm diameter mounted focally on a 15 cm hemispherical shell. High speed optical images of the focal region were captured for the 20 ms following a single Histotripsy pulse delivered. Measurable motion was detected only when the focal pressure was sufficient to produce a cavitation bubble cloud. FIGS. 1A-1B show a plot of the average velocity profile after each Histotripsy pulse along with the average peak velocity observed for each of the tested focal pressures. FIG. 1A illustrates the velocity observed at the therapy focus following Histotripsy pulses of various focal pressures, and FIG. 1B shows a plot of the average peak velocity observed for each of the tested pressures within the focal region in the agarose phantom using particle image velocimetry (PIV). Without cavitation generated by the Histotripsy pulse, no appreciable motion was detected. When cavitation occurred, the peak motion detected by PIV increased with increasing Histotripsy pulse pressure.

[0062] Following a Histotripsy pulse, a cavitation bubble cloud was generated immediately and collapsed within 300 μ S. Residual bubble, nuclei persist for over 100 ms after the cavitation collapse and were clearly visible in high-speed optical images of the focal region after a Histotripsy therapy pulse.

[0063] In FIGS. 2A-2D, PIV velocity maps showed 2 phases of motion during the 19 ms after a Histotripsy therapy pulse. For up to the first 2 ms, chaotic motion was

present, where the motion was pointed in all directions in a random manner through this period. This chaotic motion phase likely resulted from the violent collapse of the Histotripsy bubble cloud. After this chaotic motion subsides, a coherent motion along the direction of the therapy ultrasound beam was visible. The coherent motion was first moving away from the therapy transducer for up to 6 ms, and then rebounding back towards the therapy transducer through the remaining 19 ms. This coherent motion may be due to the bubble cloud being pushed by the radiation force of the Histotripsy pulse against an elastic tissue boundary or the asymmetric collapse of the cavitation cloud against the boundary. FIGS. 2A-2D show images of an example progression of the focal region PIV velocity map after the tissue had been treated with 50 Histotripsy pulses. The therapy pulse was propagated from right to left.

[0064] In FIGS. 2A-2D, high speed images of the focal region are shown approximately 50 pulses into treatment (therapy applied from the right on the page) with PIV velocity map overlays showing the Histotripsy bubble cloud (FIG. 2A), chaotic motion immediately after the collapse of the bubble cloud (FIG. 2B), and finally coherent motion, including a push away from the transducer (FIG. 2C) and subsequent rebound (FIG. 2D).

[0065] The time profile of the resulting velocity of the coherent motion expands as the tissue is fractionated and saturate when the tissue is completely liquefied. Similarly, the averaged velocity within a specific time window of the coherent motion increases with increasing degree of tissue fractionation, and saturates when the clot is completely liquefied.

[0066] The velocity resulting from the coherent motion can be detected by ultrasound color Doppler that uses the cross-correlation time/phase lag of adjacent frames to detect the target motion. By synchronizing Doppler pulses with Histotripsy pulses and choosing appropriate parameters, color Doppler can be used to monitor the coherent motion in the Histotripsy treatment region. By choosing the appropriate delay between the Histotripsy pulse and the color Doppler pulse packet, color Doppler can be used to monitor the coherent motion phase without the interference from the chaotic motion. The Doppler velocity can be then analyzed to quantitatively predict the level tissue fractionation during the treatment in real-time. The Doppler velocity map can also be displayed it as a colored region overlaid on the gray-scale image, providing real-time imaging feedback to monitor Histotripsy tissue fractionation. B-Flow and M-mode approaches are possible alternatives to color Doppler.

[0067] To perform bubble-induced color Doppler monitoring of Histotripsy, a Histotripsy system (including an ultrasound therapy transducer and associated driving electronics) and an ultrasound imaging system are required. FIG. 3 illustrates a Doppler monitoring Histotripsy system 300 including an ultrasound therapy transducer 302, a Doppler imaging transducer or transducers 304 (shown as 304a and 304b), Histotripsy therapy driving hardware 306 (which can include, for example, a pulse generator, amplifiers, matching networks, and an electronic controller configured to generate Histotripsy pulses in the ultrasound therapy transducer), and imaging hardware 308 which can control Doppler imaging with the Doppler imaging transducer(s) 304. As shown in FIG. 3, the Doppler imaging transducers can be disposed within a cut-out or hole within the ultrasound therapy

transducer, for example, so as to facilitate imaging of a focus 310 (and thus the bubble cloud) of the therapy transducer.

[0068] After application of the Histotripsy pulse, the tissue velocity along the axial direction or the propagation direction of the ultrasound pulse is monitored using color Doppler. This can be achieved by placing the ultrasound imaging transducer in-line with the therapy transducer, for example, the Histotripsy therapy transducer can have a central hole to house the ultrasound imaging transducer to ensure the imaging transducer is monitoring the axial displacement of the tissue along the propagation direction of the Histotripsy pulse.

[0069] The synchronization of the Histotripsy system and Doppler acquisition of the ultrasound imaging system is essential and can be achieved by triggering Doppler pulse transmission from the Doppler imaging transducer(s) using a signal sent out from the Histotripsy therapy driving hardware 306 at an appropriate delay time (negative or positive) after the transmission of the Histotripsy pulse. It is also possible to trigger the Histotripsy therapy driving hardware with a signal from the imaging hardware 308.

[0070] FIG. 4 demonstrates a synchronization scheme according to one embodiment. An appropriate delay needs to be set between the Histotripsy pulse and the Doppler pulse transmission, such that the Doppler velocity measures the coherent motion phase, not the chaotic motion immediately following the Histotripsy pulse. The chaotic motion phase ranges from 300 us to 2 ms, depending on the tissue type and the level of tissue fractionation.

[0071] We have treated ex vivo porcine liver tissue using Histotripsy, and compared the bubble-induced color Doppler feedback with the histology of the treated tissue. The histology results show that the temporal profile of the bubble-induced Doppler feedback may be used to predict the microscopic cellular damage versus the macroscopic tissue structure damage. Microscopic cellular damage is sufficient to result in cell death. Microscopic cellular damage to most cells within the treatment region occurs very early on in the Histotripsy treatment, only requiring ~50 pulses. Complete homogenization of tissue structure takes more than 500 pulses.

[0072] Correspondingly, the time profile of the Doppler velocity expanded with a very steep slope for the first 50 pulses. After that, the expansion of the temporal profile of the Doppler was much more gradual, until at 900 pulses, the expansion saturates. These results suggest that the bubble-induced color Doppler can be used to monitor and indicate microscopic cellular damage (i.e., cell death) versus macroscopic tissue structure homogenization (i.e., tissue liquefaction). Current B-mode ultrasound imaging is not sensitive enough to monitor the microscopic cellular damage alone. The bubble-induced color Doppler has improved sensitivity to detect the microscopic cellular death as well as damage to the macroscopic tissue structure. This improved sensitivity can dramatically increase the treatment efficiency. Using such increased sensitivity, treatment completion can be determined in real-time for different clinical applications. For example, macroscopic tissue liquefaction is needed for clot removal, while cell death may be sufficient for tumor treatment and benign lesions. This feature is innovative and of clinical importance, and is not available for any current feedback techniques.

[0073] The amplitude of bubble-induced color Doppler changes over the Histotripsy treatment may vary across

different organs and patients. Our data suggest that the slope or the rate of Doppler velocity change, either the temporal profile of the velocity within sub-time window of the coherent motion, can be used to monitor the treatment, to detect microscopic cellular damage as well as macroscopic tissue structure homogenization. Therefore, the detection does not depend on the absolute value of the Doppler velocity, but the relative change, and therefore is expected to be consistent and reliable across different organs and patients.

[0074] Moreover, the Doppler parameters, such as the pulse repetition frequency (PRF) and number of frames for each Doppler acquisition, can be selected appropriately to achieve the desired correlation between the Doppler velocity increase with the increasing degree of tissue fractionation (i.e., Histotripsy treatment progress) in different tissue types. In addition, by setting the wall filter threshold to exceed the background displacement, the color Doppler velocity map region can precisely match the fractionation region.

[0075] Further, Doppler parameters (e.g., time window of the Doppler acquisition) can be adjusted, such that the average Doppler velocity is towards the transducer prior to treatment completion shown as one color (e.g., blue), while the Doppler flow is away from the transducer at the treatment completion viewed as a different color (e.g., red). Such a definitive indication for treatment completion is apparent to even inexperienced users. This can be achieved because the temporal profiles of the coherent motion away from the transducer and back towards the transducer expand with the degree of tissue fractionation.

[0076] As the residual bubble nuclei from the cavitation bubble cloud collapse generated by Histotripsy lasts over a hundred milliseconds after each Histotripsy pulse and moves with the target tissue, these residual nuclei provide bright speckle to track the bubble-induced motion in the tissue during Histotripsy treatment. They provide strong speckles for displacement the motion tracking, even with poor imaging quality.

[0077] Moreover, since Doppler is an essential tool for monitoring cardiovascular function, the capability of color Doppler during Histotripsy treatment allows us to monitor the vessel and cardiac function during the treatment, which could have significant clinical implications. For example, Histotripsy can be used to remove blood clots in the vessel and color Doppler can evaluate whether the blood flow is restored or improved during the Histotripsy treatment in a previously completely or partially occluded vessel.

[0078] Histotripsy has also been studied to create a flow channel through the atrial septum between the two atria in the heart for patients with congenital heart disease. In this situation, color Doppler can indicate the generation of the flow channel, i.e., treatment completion. In another example, when treating diseased tissues (such as liver tumor or renal tumor) surrounding major blood vessels, color Doppler can be used to ensure no penetration is generated to the vessel during the Histotripsy treatment. Different colors can be used for bubble-induced color Doppler feedback during Histotripsy (e.g., green and yellow) to distinguish from blue and red commonly used in color Doppler for blood flow.

[0079] The bubble-induced color Doppler cannot be used directly to form an image of a large volume, as the Histotripsy pulse is used to treat one focal volume at a time. It is possible to steer the therapy transducer focus (electronically

or mechanically) over the large ablated volume and collect the data to reconstruct the 2D/3D image of the ablated volume.

[0080] The ablated tissue coagulates quickly after treatment, which may change the elasticity of the treated volume after treatment. If bubble-induced color Doppler will be used for post-treatment lesion evaluation when the tissue is coagulated, we can develop a quick ablation scan sequence to re-fractionate the coagulative tissue prior to the elastography measurement.

[0081] To allow simultaneous optical and acoustic interrogation of the focal volume over the course of Histotripsy treatment on a large volume, an experiment was conducted in an acoustically and optically transparent agarose hydrogel tissue mimicking phantom without the addition of any acoustic or optical contrast agents. In this case, a layer of contrast agents would be destroyed or dispersed into the surrounding regions as the focal volume was fractionated by Histotripsy therapy.

[0082] This phantom was treated with 2-cycle pulses at >50 MPa over a 6 mm cube using the same 500 kHz phased array transducer. This high pressure guaranteed the generation of a cavitation cloud, and the residual bubble nuclei left after its collapse for optical and acoustic contrast at the focal location. To ensure uniform fractionation over the target volume, 219 focal points at 1 mm separations (FIG. 5) were treated sequentially at 150 Hz with a single pulse applied at each location. This process was repeated every 1.5 seconds until all focal locations had been treated with 960 pulses each. This pulsing strategy guarantees uniform therapy dose over the treatment volume at all times during treatment. In FIG. 5, steered focal locations for the 219 foci are shown with alternating 1 mm spaced grids of 7×7 foci and 6×6 foci. The axial layers are separated by 1 mm, but with the 6×6 grids offset laterally from the 7×7 layers by 0.5 mm.

[0083] The internal memory of the high-speed camera may not be able to accommodate acquisitions after every pulse, so to facilitate continuous treatment without interruptions for data transfer; images can be captured periodically (e.g., after every 10th pulse delivered to the center focal location). Ultrasound Doppler acquisitions can be performed after every therapy pulse. The imaging transducer can be positioned opposite the therapy transducer, as described above, aligned along the therapy axis, i.e., the ultrasound imaging beam can be rigidly aligned with the therapy beam to avoid the effect of angle variation on Doppler. An experimental setup is illustrated in FIG. 6, which shows a therapy transducer 602, a Doppler imaging transducer 604, ultrasound control system 606, and imaging control system 608. The experimental setup also shows the tissue phantom disposed in a water tank and a high speed camera and light source for additional imaging capabilities. In one embodiment, the experimental setup included a 500 kHz transducer mounted to the side of a water tank with 5 MHz imaging probe mounted opposite the therapy and aligned along the therapy axis. The high speed camera was positioned perpendicular to the therapy axis.

[0084] In the experiment, a tissue-mimicking agarose gel phantom with an embedded red blood cell (RBC) layer was used to visualize and quantify the development of the lesion. These phantoms have been shown to produce reliable estimates of the cavitation-induced damage zone resulting from Histotripsy therapy. In this phantom, the RBC area lysed by Histotripsy changed from opaque red to translucent pink,

allowing direct visualization and quantification of the lesion development. The lesions were photographed during treatment after each application of the 219 focal patterns. Simultaneous ultrasound Doppler acquisitions were also performed for direct comparison. The average pixel intensity within the lesion was then computed over the course of the treatment as a direct quantification of the fractionation progression in the tissue phantom and compared to the measured Doppler velocity progression.

[0085] An experiment was conducted in ex vivo porcine liver to analyze the color Doppler monitoring of the Histotripsy fractionation progression in tissue and compare it to the results from the agarose phantom. This experiment used an identical setup as above, with the agarose gel tissue phantom replaced with a freshly harvested piece of porcine liver tissue, degassed and embedded in 1% agarose gel and positioned over the geometric focus.

[0086] The liver was treated with 2000 pulses at each of the 219 focal locations, with ultrasound Doppler acquisitions performed after every pulse delivered to the center focal location. High-speed optical imaging for PIV analysis was not possible in the tissue.

[0087] The high-speed optical images of the focal region were processed to estimate the motion resulting from the Histotripsy therapy pulses. The PIV analysis was performed in a ~1.7 by 0.85 mm field of view at a resolution of 151 pixels per mm (total 256×128 pixels at 50 kHz frame rate) for the glass bead layer experiments and ~6.6 by 3.3 mm field of view at a resolution of 116 pixels per mm (total 768×384 pixels at 10 kHz frame rate) for the large lesion treatments. The images were processed in pairs at two subsequent time points using a FFT window deformation algorithm with 3 pass velocity estimation with image block sizes and step sizes of 24/12 pixels for pass 1, 16/8 pixels for pass 2, and 8/4 pixels for pass 3 in the glass bead layer experiment and 64/32 pixels for pass 1, 32/16 pixels for pass 2, and 16/8 pixels for pass 3 in the larger lesion treatments. Both resulted in velocity field maps of the field of view over the 19 ms after a Histotripsy therapy pulse. The axial components of these PIV velocity maps were then averaged over the bubble cloud area to produce the final average velocity estimate over time.

[0088] The ultrasound Doppler acquisitions were also processed. To calculate the velocity over the 19 ms after the therapy pulse, the 200 acquisitions were processed in rolling 10 acquisition segments (equivalent to using 10 frames at 10 kHz PRF, with different delay times after the histotripsy pulse). These Doppler velocity maps were then averaged over the 2×4 mm bubble cloud area to produce the final average velocity estimate over time.

[0089] The full velocity profiles over the 960 pulse treatments are shown in FIGS. 7A-7B for both PIV (FIG. 7A) and Doppler (FIG. 7B) estimation methods. The estimated velocity is shown versus the delay from the therapy pulse (y axis) and the therapy dose (x axis).

[0090] FIG. 8 shows 3 individual velocity traces after 10, 30, and 290 therapy pulses. After the chaotic motion phase, PIV and Doppler estimates agree with each other well over the course of treatment. These plots show a time expansion of the velocity profile with increased therapy dose, which is likely due to the elasticity decrease as the phantom when it was gradually fractionated by Histotripsy pulses. The increase in the duration of the coherent push and rebound motion reached a peak after 400 pulses, likely because the

phantom was completely liquefied. FIG. 8 shows good agreement between PIV and Doppler in measured velocity after the initial chaotic motion.

[0091] The velocity progression at any single delay between the Histotripsy pulse and the Doppler pulse packet can be extracted from this dataset, producing the average velocity within a 1 ms window over the course of therapy. These velocity progressions are readily attainable in real-time from color Doppler during Histotripsy therapy, with an average processing frame rate around 30 Hz. The Doppler velocity progression at 6 ms delay from the Histotripsy pulse is shown in FIG. 9. In this case, the Doppler measurement estimates the average velocity during the time window from 6-7 ms after the therapy pulse. During this window, the velocity started at a positive value (first 15 pulses), then changed to a negative value (pulses 15-140), then became positive again (after 140 pulses), and eventually stabilized at a positive velocity after 260 pulses. These changes provide real-time feedback on fractionation progression during Histotripsy therapy, even indicating complete fractionation of the agarose tissue phantom when the velocity measurement peaks. FIG. 9 shows Doppler velocity progression at a 6 ms delay from therapy pulse without averaging (left) and with a 10 pulse running average (right).

[0092] FIG. 10 shows a comparison of the Doppler velocity fractionation metric versus the mean lesion intensity metric in the damage indicating RBC layer (N=6). Both Doppler velocity and the lesion progress rapidly increased until ~100 pulses. In the agarose tissue phantom containing the damage indicating red blood cell (RBC) layer, the pixel intensity within the lesion increased with increased therapy dose, saturating after approximately 100 pulses. The Doppler velocity at a 6 ms delay was observed to change rapidly during this time period until 100 pulses. The Doppler velocity continued to change at a slower rate beyond this point before saturating after approximately 200 pulses.

[0093] This Doppler velocity metric is obtainable in real-time at high frame rates (up to 200 Hz) during Histotripsy therapy, however if high frame rates are not required, alternative metrics are also possible. For example, the time to peak velocity shown in FIG. 11 also captures the same rapid change up to 100 pulses observed in the lesion intensity, and also the continued slow increase up to 200 pulses. In FIG. 11, an alternative progression metric, time to peak velocity, shows less variation and captures the same rapid change up to 100 pulses shown in the mean lesion intensity, with a slower continued progression up to 200 pulses.

[0094] In the ex vivo porcine liver, velocity profiles were collected after each of 2000 therapy pulses at the center of the treated volume. FIG. 12 shows the full velocity profile over the entire treatment. The estimated velocity is shown versus the delay from the therapy pulse (y axis) and therapy dose (x axis). The Doppler velocity profiles in the ex vivo porcine liver were similar to the agarose phantom, with a brief period of chaotic motion followed by coherent motion. These coherent motions also expanded in time with increased therapy dose very rapidly up to 50 pulses. After 50 pulses, the temporal profile of the Doppler velocity continued to expand at a slower rate until 900 pulses. After that point, the temporal profile of the Doppler velocity decreased slowly with increasing number of therapy pulses.

[0095] The velocity progression at a single delay of 8 ms was extracted from this dataset, producing the average

velocity during the 8-9 ms window over the course of therapy. This is shown in FIG. 13. During this window the velocity increased quickly for the first 50 pulses, and then steadily at a slower rate up to 900 pulses as the tissue was fractionated. After 900 pulses, the velocity decreased steadily with increased variation from pulse to pulse. In FIG. 13, Doppler velocity progression in ex vivo liver is shown without averaging (left) and with a 10 point running average (right).

[0096] Histological analysis was completed on separate lesions after 50, 200, and 500 pulse treatments to visualize the lesion progression in the tissue resulting from these treatment parameters. FIG. 14 shows the lesion resulting from a 50 pulse treatment, with widespread mechanical disruption of the cellular structures visible microscopically in the entire treatment region. This widespread microscopic cellular damage is sufficient to cause tissue death. No macroscopic homogenization of the tissue structure was visible after 50 pulses. In FIG. 14, Histological images of the lesion after 50 therapy pulses are shown. The macroscopic image (left) shows little large-scale homogenization, however widespread mechanical fractionation is visible microscopically (bottom right) compared to control (top right).

[0097] After 200 pulses however, fractionation to the macroscopic tissue structure is much more evident, with a nearly homogeneous appearing lesion as shown in FIG. 15. Microscopically, increased fractionation of cellular structure and nuclei is apparent, along with increased homogeneity and mixing of fractionation products. In FIG. 15, histological images of the lesion are shown after 200 therapy pulses. Macroscopic image (left) shows clear large-scale homogenization, with increased mechanical fractionation visible microscopically (bottom right) compared to control (top right).

[0098] After 500 pulses, as shown in FIG. 16, the lesion appears homogeneous and completely fractionated, with very few remaining cell nuclei in the homogenous fractionated tissue product. In FIG. 16, histological images of the lesion are shown after 500 therapy pulses. The macroscopic image (left) shows complete large-scale homogenization, with near complete homogenization visible microscopically as well (bottom right) compared to control (top right).

[0099] Comparing the Doppler velocity results and histology results, the initial rapid expansion in the temporal profile of the Doppler velocity match well with the microscopic cellular damage to the treated tissue, both were observed at 50 pulses. After that, the temporal profile of the Doppler velocity continues to expand, but the rate is more gradual. Correspondingly, macroscopic damage to the tissue structure is observed. When the tissue is completely liquefied with no tissue or cellular structures remaining, the temporal profile of the Doppler velocity flattens and begins to shrink at a very slow rate.

[0100] The bubble-induced color Doppler provides a real-time, high sensitivity feedback to monitor Histotripsy tissue fractionation during treatment. In comparison to the reduced echogenicity in the treatment zone (speckle amplitude reduction) currently used in monitoring Histotripsy tissue fractionation, the bubble-induced color Doppler feedback can predict microscopic cellular damage, especially at an earlier treatment stage, which cannot be achieved with reduced echogenicity. Moreover, bubble-induced color Doppler has the potential to predict microscopic cellular damage versus the macroscopic damage to the tissue structure. This

level of sensitivity is very important for clinical application to predict the end point for treatment for different clinical applications.

[0101] The bubble-induced color Doppler can provide consistent and reliable feedback across different tissues and patients. Our data suggest that the slope or the rate of Doppler velocity change, either the temporal profile of the velocity within sub-time window of the coherent motion, can be used to monitor the treatment, to detect microscopic cellular damage as well as macroscopic tissue structure homogenization. The detection does not depend on the absolute value of the Doppler velocity that may vary across patients, but the relative change, and therefore is expected to be consistent and reliable across different organs and patients.

[0102] The bubble-induced color Doppler can be displayed as color overlaid on gray-scale ultrasound images, providing a high contrast feedback to monitor the degree of tissue fractionation (i.e., treatment progress and completion). Such feedback is unambiguous and easy to use even for inexperienced users.

[0103] As described above, an ultrasound imaging transducer can be placed in-line (or co-axially) with the Histotripsy therapy transducer. For example, such configuration can be achieved by having a small center hole in the therapy transducer to house the imaging probe. The Doppler acquisition on the ultrasound imaging system needs to be synchronized by the Histotripsy therapy pulse such that the first Doppler pulse arrives at the focus at a predefined delay time after the arrival of the Histotripsy pulse.

[0104] For the speckle amplitude reduction approach currently used to monitor Histotripsy tissue fractionation, the speckle amplitude has been observed to increase back shortly after treatment likely due to the coagulation of the fractionated region, causing the speckle reduction approach ineffective. However, even with the coagulation, the change in tissue elasticity from tissue fractionation remains substantial and should still be usable in the presence of coagulation.

[0105] As Doppler is an important tool in evaluating cardiovascular function clinically, the real-time bubble-induced color Doppler should also allow evaluation of the vessel or the heart close to the treatment target during the Histotripsy treatment. Different colors can be used for tissue motion (e.g., green and yellow) to distinguish from the red and blue commonly used in color Doppler for blood flow.

[0106] The ultrasound gray-scale imaging quality of deep tissue (e.g., deep internal organs) is often degraded significantly due to the attenuation and aberration from the overlying tissue, resulting in coarse tissue speckle and making the accurate tissue motion tracking difficult. However, the residual nuclei from bubble cloud generated by Histotripsy last over 100 milliseconds after each Histotripsy pulse and moves with the target tissue, providing strong ultrasound speckles for motion tracking during bubble-induced color Doppler.

[0107] As for additional details pertinent to the present invention, materials and manufacturing techniques may be employed as within the level of those with skill in the relevant art. The same may hold true with respect to method-

based aspects of the invention in terms of additional acts commonly or logically employed. Also, it is contemplated that any optional feature of the inventive variations described may be set forth and claimed independently, or in combination with any one or more of the features described herein. Likewise, reference to a singular item, includes the possibility that there are plural of the same items present. More specifically, as used herein and in the appended claims, the singular forms “a,” “and,” “said,” and “the” include plural referents unless the context clearly dictates otherwise. It is further noted that the claims may be drafted to exclude any optional element. As such, this statement is intended to serve as antecedent basis for use of such exclusive terminology as “solely,” “only” and the like in connection with the recitation of claim elements, or use of a “negative” limitation. Unless defined otherwise herein, all technical and scientific terms used herein have the same meaning as commonly understood by one of ordinary skill in the art to which this invention belongs. The breadth of the present invention is not to be limited by the subject specification, but rather only by the plain meaning of the claim terms employed.

What is claimed is:

1. A method of monitoring Doppler-based feedback during Histotripsy treatment comprising the steps of:
 - transmitting Histotripsy pulses into a target tissue, the Histotripsy pulses having a pulse length less than 50 μ sec, a peak negative pressure greater than 10 MPa, and a duty cycle less than 5%;
 - generating a cavitation bubble cloud in the target tissue with the transmitted Histotripsy pulses;
 - transmitting Doppler ultrasound imaging pulses into the target tissue after the cavitation bubble cloud collapses;
 - monitoring a coherent motion along a direction of the transmitted Histotripsy pulses with the Doppler ultrasound imaging pulses; and
 - analyzing a Doppler velocity of the Doppler ultrasound imaging pulses to quantitatively predict a level tissue fractionation in the target tissue in real-time.
2. The method of claim 1 further comprising synchronizing the Histotripsy pulses and the Doppler ultrasound imaging pulses with a predetermined time delay.
3. The method of claim 1, further comprising determining that the target tissue is increasingly fractionated as the Doppler velocity changes.
4. The method of claim 1, further comprising determining that the target tissue is liquefied when the Doppler velocity saturates.
5. The method of claim 1 further comprising:
 - generating a Doppler velocity map;
 - displaying the Doppler velocity map as a colored region overlaid on a gray-scale image of the target tissue.
6. The method of claim 1 further comprising monitoring vessel function and cardiac function during transmission of the Histotripsy pulses.
7. The method of claim 1 further comprising distinguishing tissue displacement from blood flow with the Doppler ultrasound imaging pulses.

* * * * *

专利名称(译)	在组织化学过程中气泡诱导的彩色多普勒反馈		
公开(公告)号	US20180049719A1	公开(公告)日	2018-02-22
申请号	US15/713441	申请日	2017-09-22
[标]申请(专利权)人(译)	徐震 MILLER RYAN M MAXWELL ADAM D CAIN查尔斯		
申请(专利权)人(译)	徐甄 MILLER, RYAN M. MAXWELL, ADAM D. CAIN, 查尔斯A.		
当前申请(专利权)人(译)	徐甄 MILLER, RYAN M. MAXWELL, ADAM D. CAIN, 查尔斯A.		
[标]发明人	XU ZHEN MILLER RYAN M MAXWELL ADAM D CAIN CHARLES A		
发明人	XU, ZHEN MILLER, RYAN M. MAXWELL, ADAM D. CAIN, CHARLES A.		
IPC分类号	A61B8/08 G01S15/89 A61B5/00 A61B17/225 A61B17/22 A61B8/00		
CPC分类号	G01S15/8981 A61B5/4848 A61B5/0059 A61B8/54 G01S15/899 A61B17/22012 A61B5/0035 A61B5/0075 A61B17/2258 A61B8/543 A61B8/488 G01S15/8979		
优先权	61/710172 2012-10-05 US		
外部链接	Espacenet USPTO		

摘要(译)

提供了组织学治疗系统，其可包括任何数量的特征。在一些实施例中，该系统包括高压电源，电耦合到至少一个信号切换放大器的脉冲发生器，电耦合到信号切换放大器的至少一个匹配网络，以及具有至少一个的超声换能器换能器元件。Histotripsy治疗系统还可包括超声多普勒成像系统。多普勒成像系统和Histotripsy治疗系统可以同步，以在组织切除手术期间实现组织分割的彩色多普勒获取。还描述了使用方法。

