



US 20190069794A1

(19) **United States**

(12) **Patent Application Publication**  
**Bardy et al.**

(10) **Pub. No.: US 2019/0069794 A1**  
(43) **Pub. Date: Mar. 7, 2019**

(54) **SYSTEM AND METHOD FOR FACILITATING A CARDIAC RHYTHM DISORDER DIAGNOSIS BASED ON SUBCUTANEOUS CARDIAC MONITORING DATA**

*A61B 5/024* (2006.01)  
*A61B 5/0245* (2006.01)  
*A61B 5/0464* (2006.01)  
*A61B 5/046* (2006.01)  
*A61B 5/0452* (2006.01)  
*A61B 5/044* (2006.01)  
*A61B 5/0432* (2006.01)  
*A61B 5/0408* (2006.01)  
*A61B 5/04* (2006.01)  
*A61B 5/0468* (2006.01)  
*A61B 5/0205* (2006.01)

(71) Applicant: **Bardy Diagnostics, Inc.**, Seattle, WA (US)

(72) Inventors: **Gust H. Bardy**, Carnation, WA (US);  
**Ezra M. Dreisbach**, Vashon, WA (US)

(21) Appl. No.: **16/178,463**

(22) Filed: **Nov. 1, 2018**

**Related U.S. Application Data**

(63) Continuation-in-part of application No. 16/102,608, filed on Aug. 13, 2018, which is a continuation of application No. 15/231,752, filed on Aug. 8, 2016, now Pat. No. 10,045,709, which is a continuation of application No. 15/066,883, filed on Mar. 10, 2016, now Pat. No. 9,408,551, which is a continuation-in-part of application No. 14/997,416, filed on Jan. 15, 2016, now Pat. No. 9,345,414, which is a continuation-in-part of application No. 14/614,265, filed on Feb. 4, 2015, now Pat. No. 9,408,545, which is a continuation-in-part of application No. 14/488,230, filed on Sep. 16, 2014, now Pat. No. 9,700,227, which is a continuation-in-part of application No. 14/080,725, filed on Nov. 14, 2013, now Pat. No. 9,730,593, Continuation-in-part of application No. 15/832,385, filed on Dec. 5, 2017.

(60) Provisional application No. 62/132,497, filed on Mar. 12, 2015, provisional application No. 61/882,403, filed on Sep. 25, 2013.

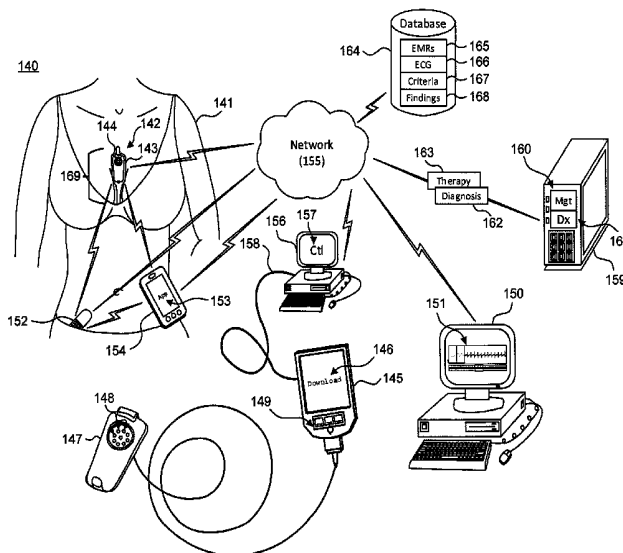
**Publication Classification**

(51) **Int. Cl.**  
*A61B 5/0456* (2006.01)  
*A61B 5/00* (2006.01)

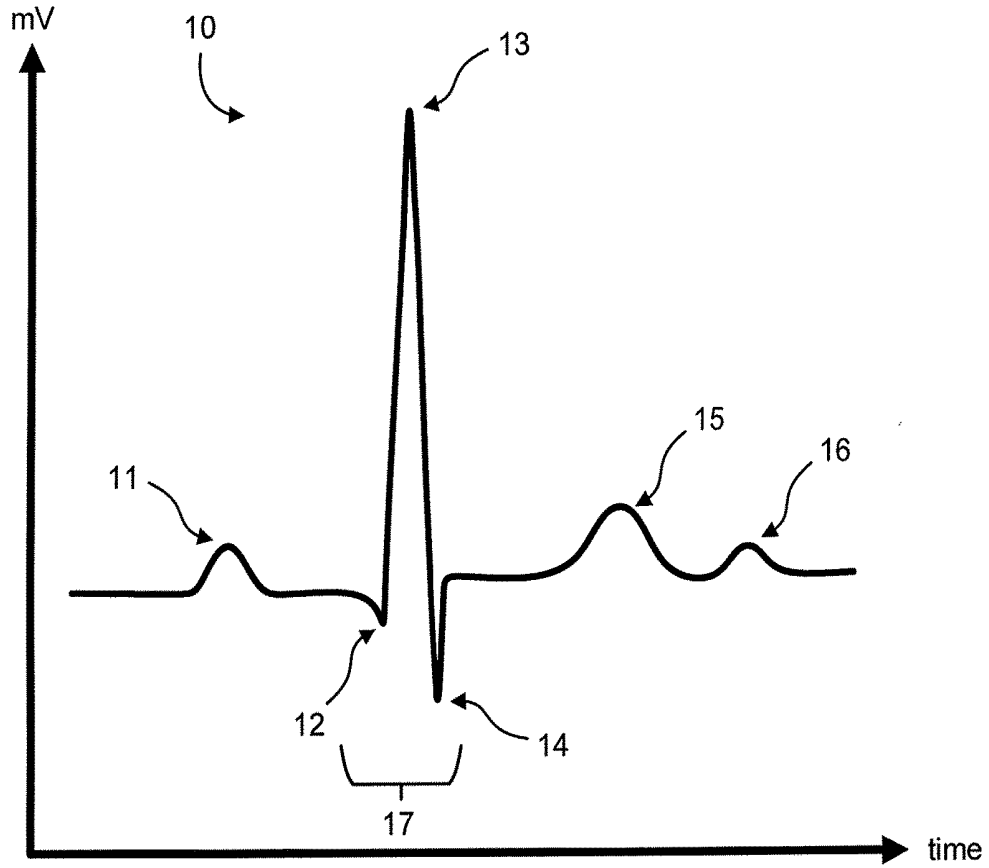
(52) **U.S. Cl.**  
CPC ..... *A61B 5/0456* (2013.01); *A61B 5/742* (2013.01); *A61B 5/02405* (2013.01); *A61B 5/0245* (2013.01); *A61B 5/6823* (2013.01); *A61B 5/0464* (2013.01); *A61B 5/046* (2013.01); *A61B 5/04525* (2013.01); *A61B 5/044* (2013.01); *A61B 5/0432* (2013.01); *A61B 5/04087* (2013.01); *A61B 5/04085* (2013.01); *A61B 5/04017* (2013.01); *A61B 5/0468* (2013.01); *A61B 5/0205* (2013.01); *A61B 5/7203* (2013.01)

(57) **ABSTRACT**

A system and method for facilitating a cardiac rhythm disorder diagnosis based on subcutaneous cardiac monitoring data with the aid of a digital computer are provided. Cutaneous action potentials of a patient are recorded as electrocardiogram (ECG) data over a set time period using a subcutaneous insertable cardiac monitor. A set of R-wave peaks is identified within the ECG data and an R-R interval plot is constructed. A difference between recording times of successive pairs of the R-wave peaks in the set is determined. A heart rate associated with each difference is also determined. The pairs of the R-wave peaks and associated heart rate are plotted as the R-R interval plot. A diagnosis of cardiac disorder is facilitated based on patterns of the plotted pairs of the R-wave peaks and the associated heart rates in the R-R interval plot.

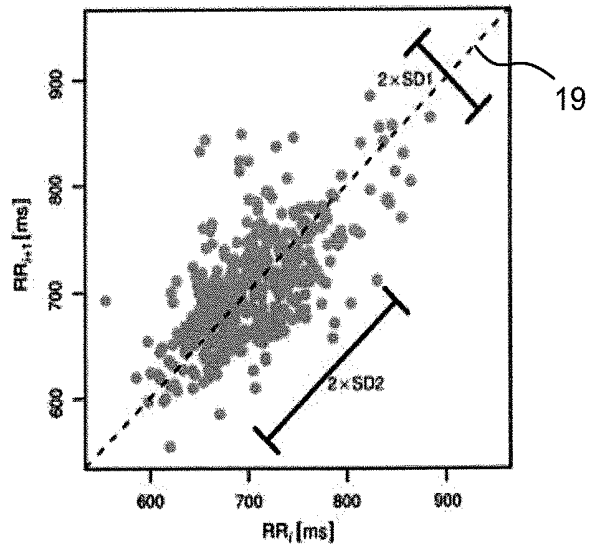


**Fig. 1.**



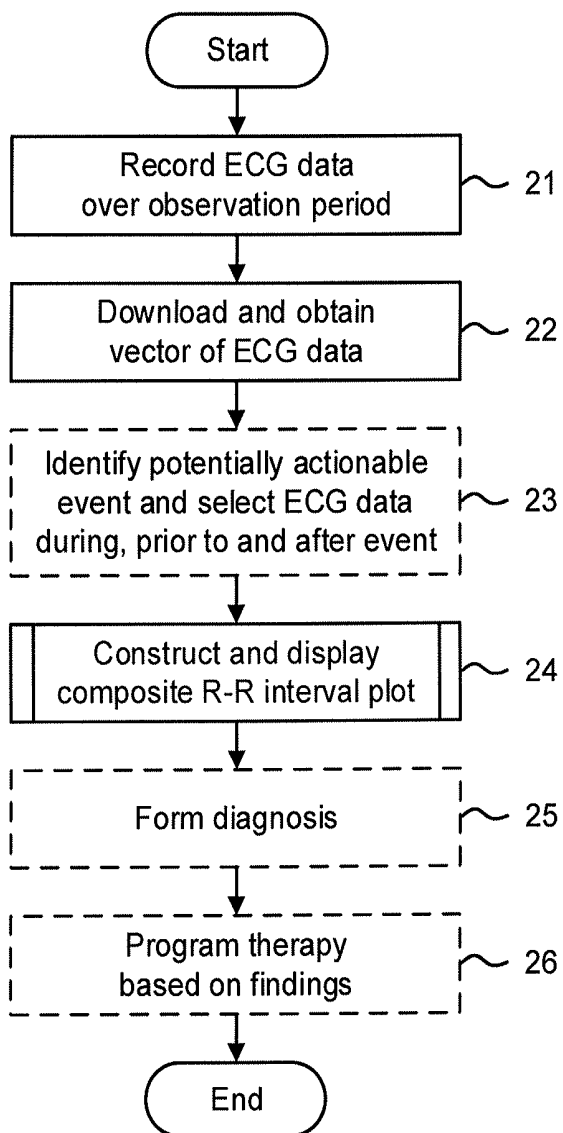
**Fig. 2.  
(Prior Art)**

18



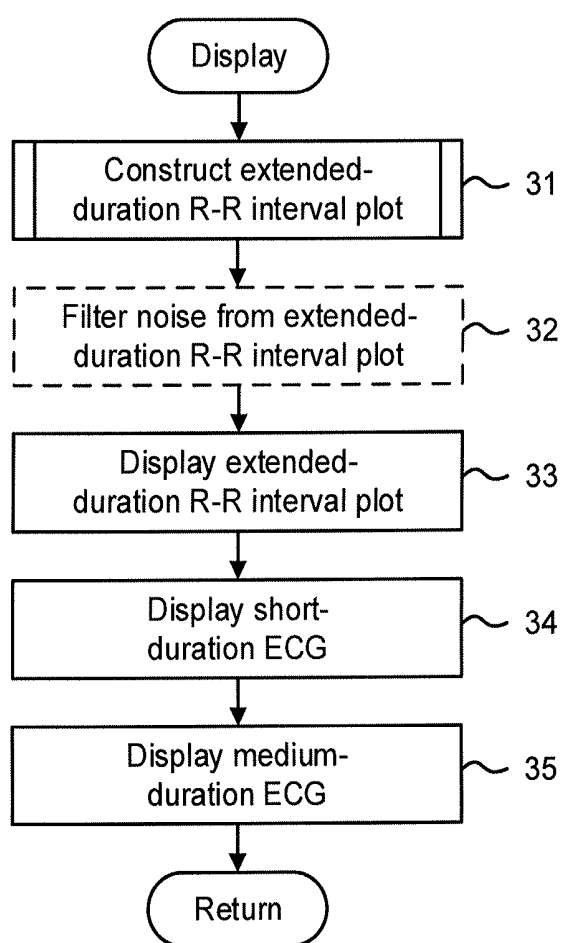
**Fig. 3.**

20



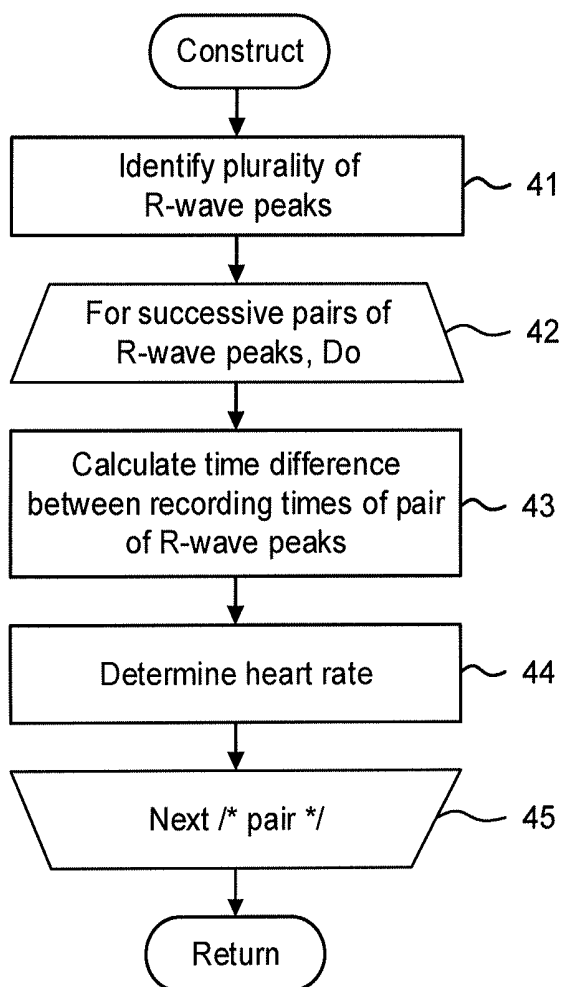
**Fig. 4.**

30

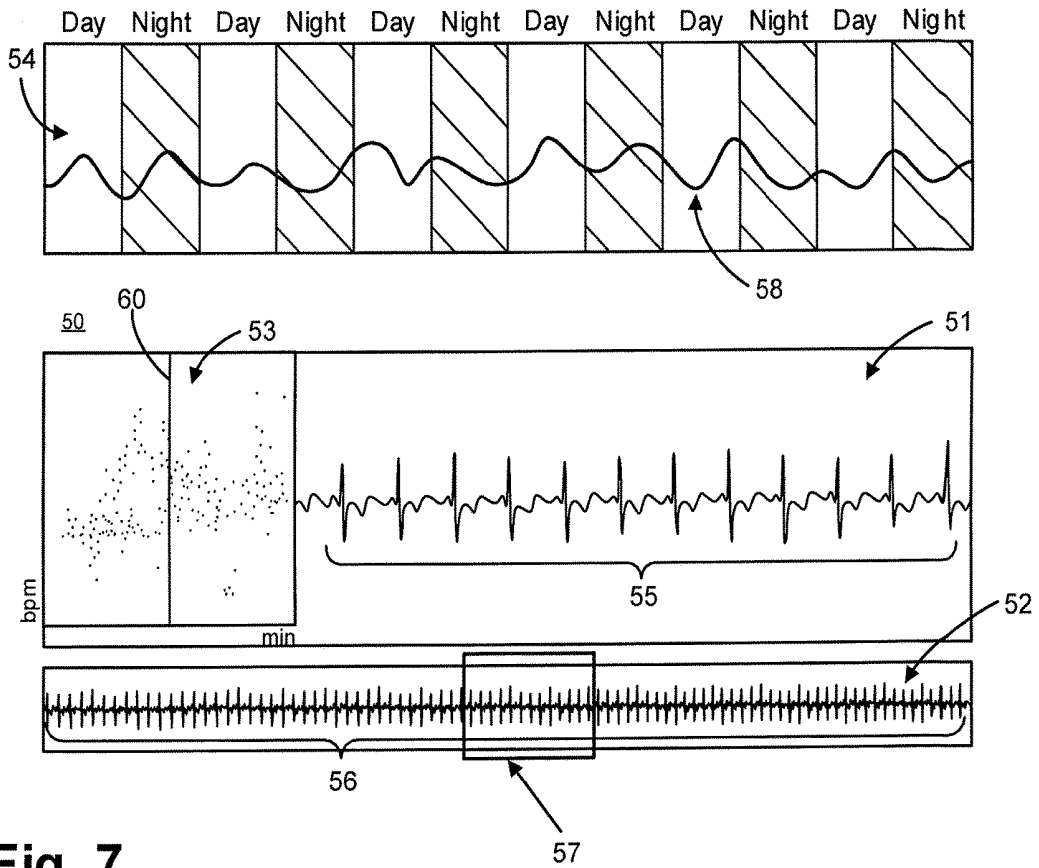


**Fig. 5.**

40



**Fig. 6.**



**Fig. 7.**

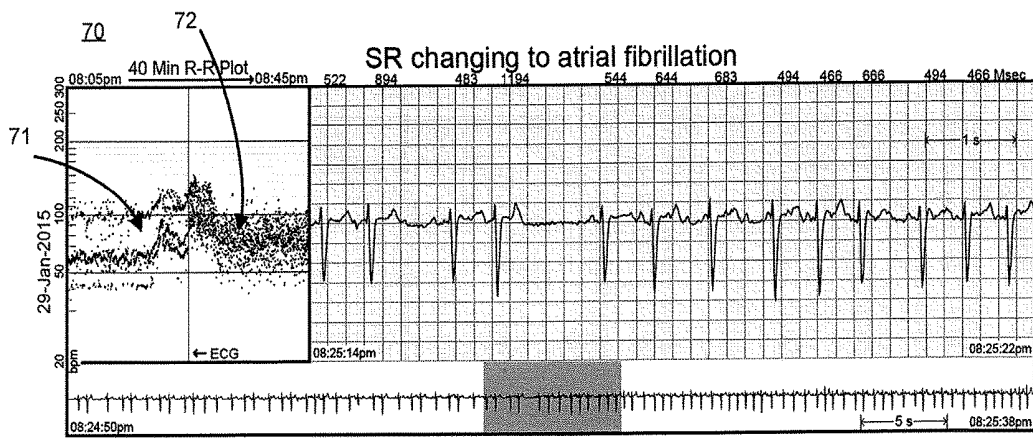


Fig. 8.

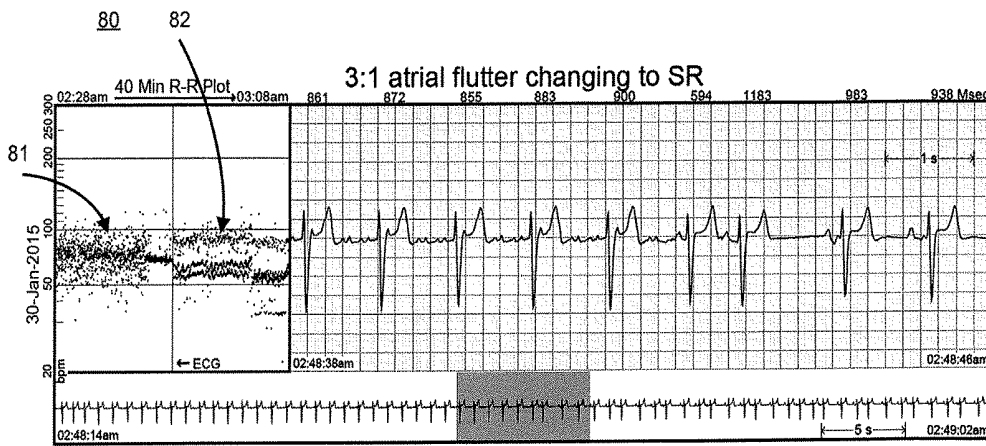


Fig. 9.

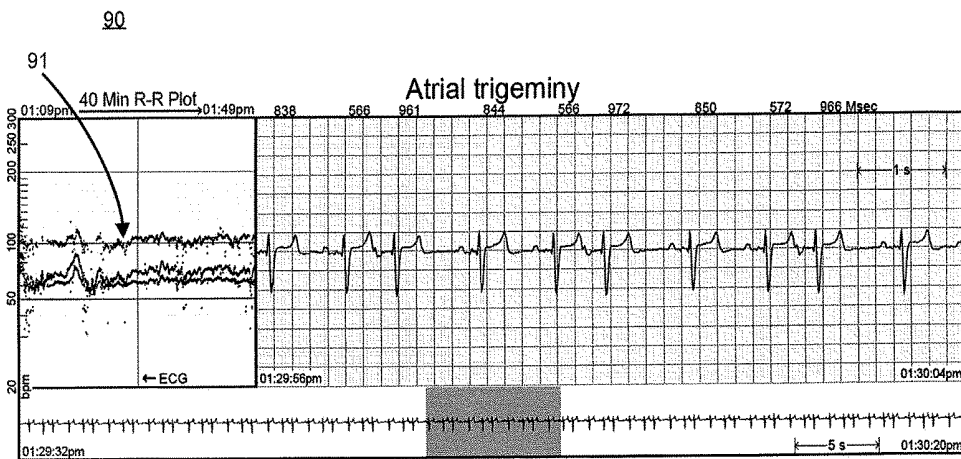


Fig. 10.

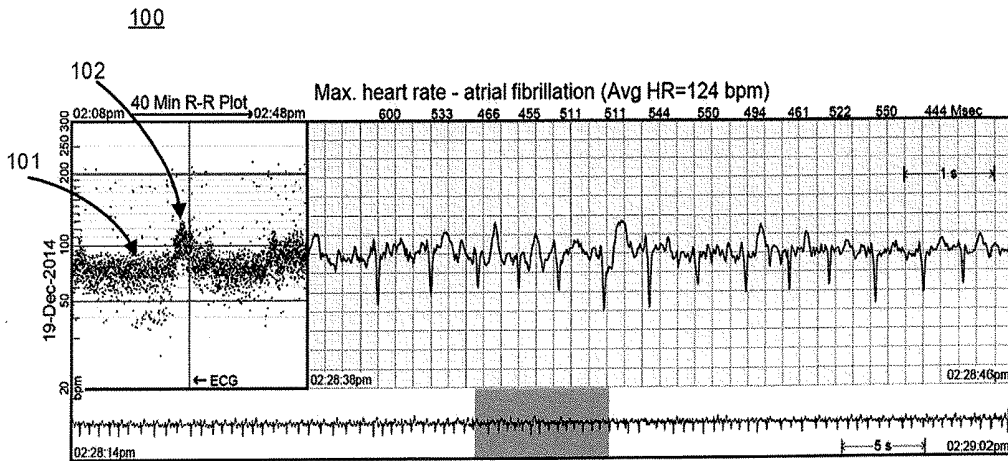


Fig. 11.

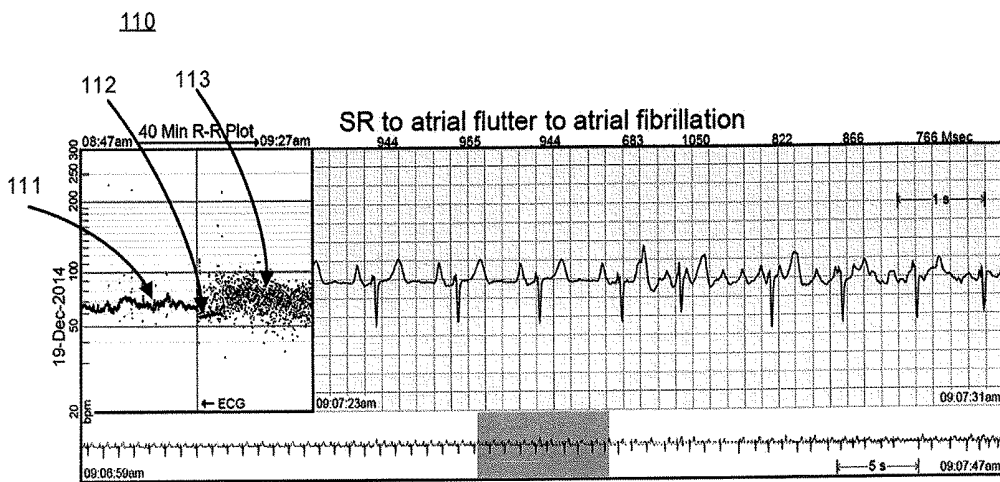


Fig. 12.

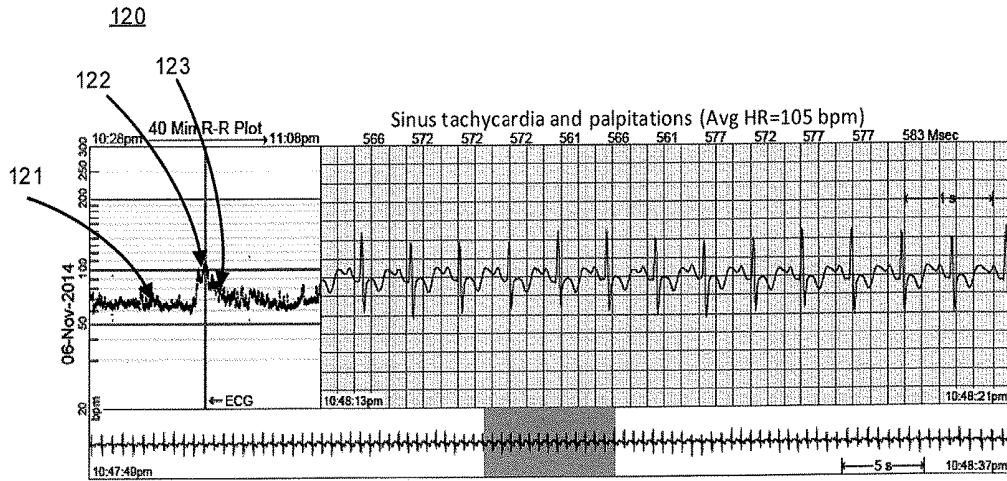
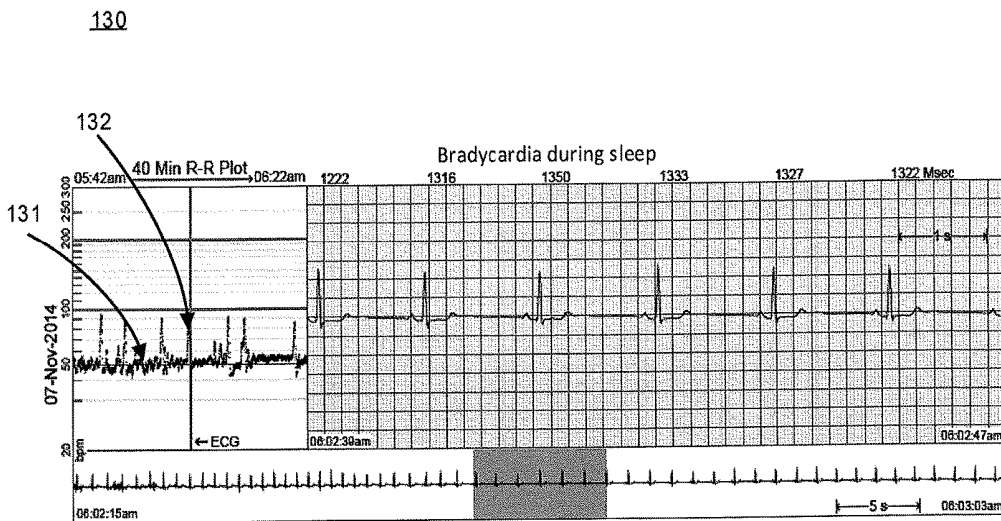
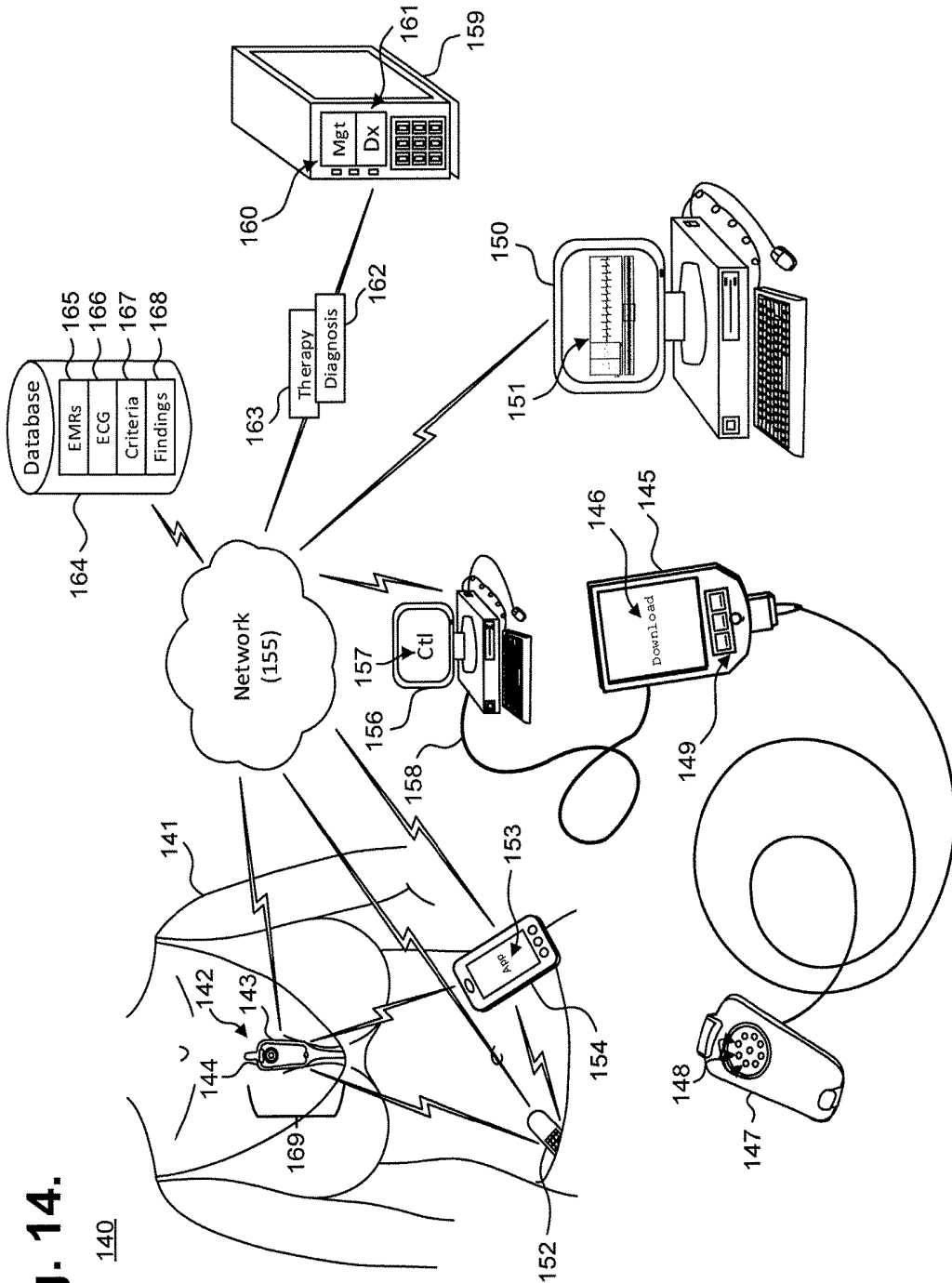


Fig. 13.

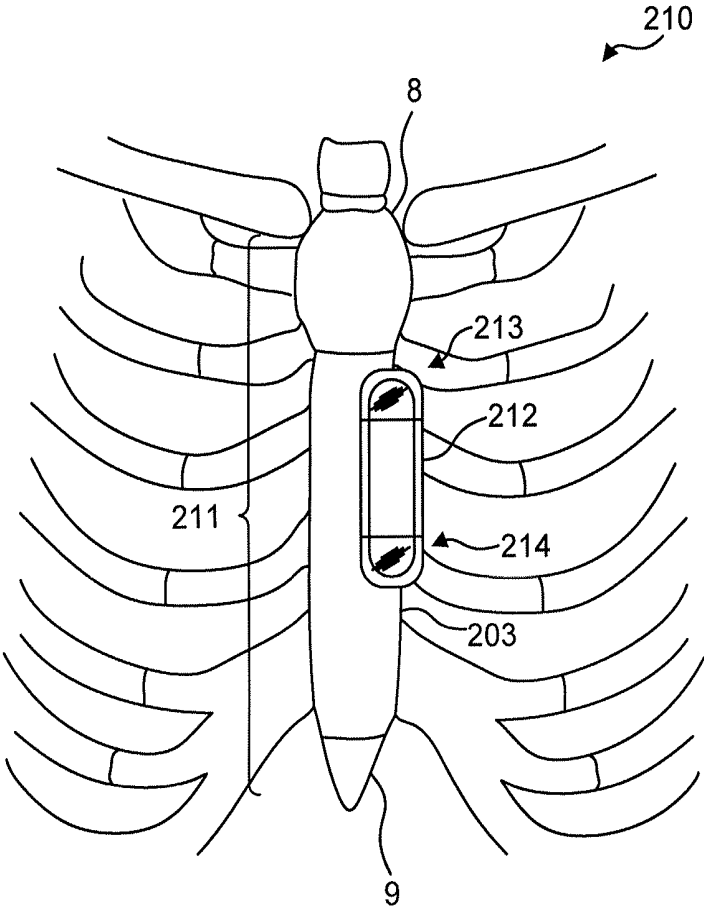




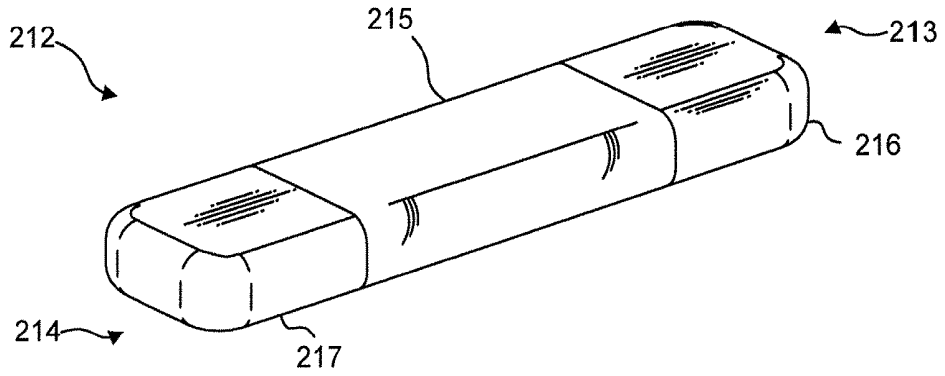
**Fig. 14.**

140

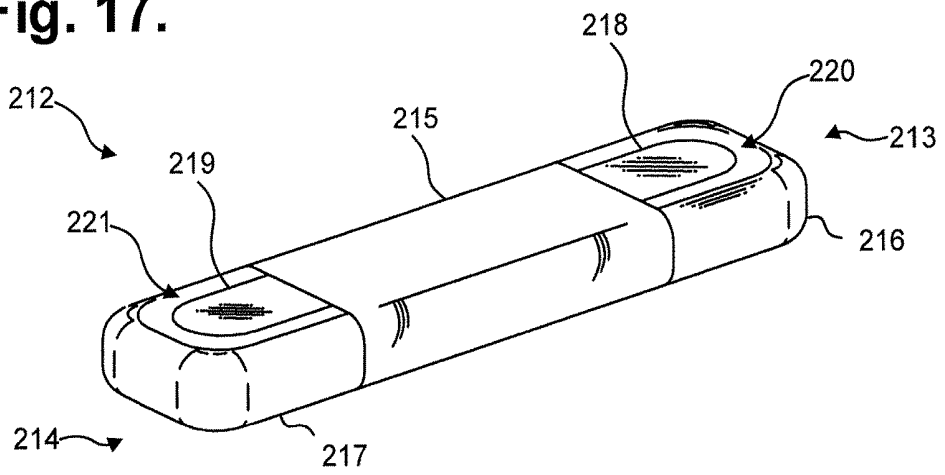
Fig. 15.



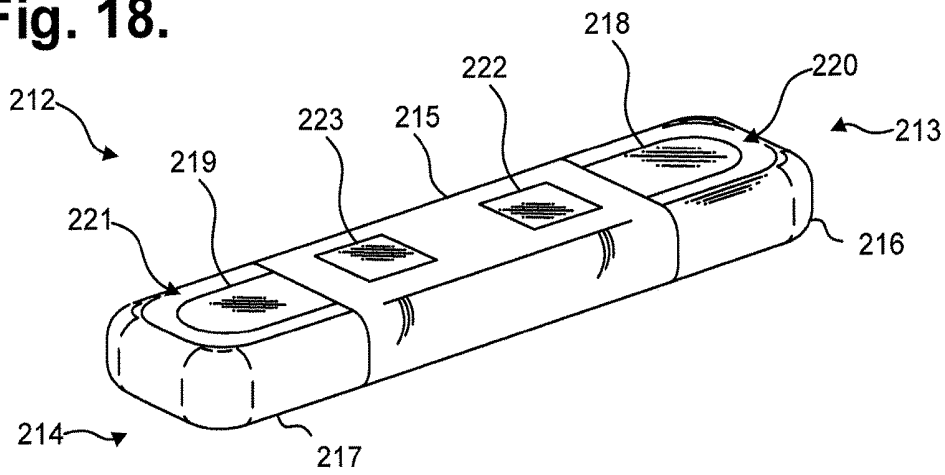
**Fig. 16.**



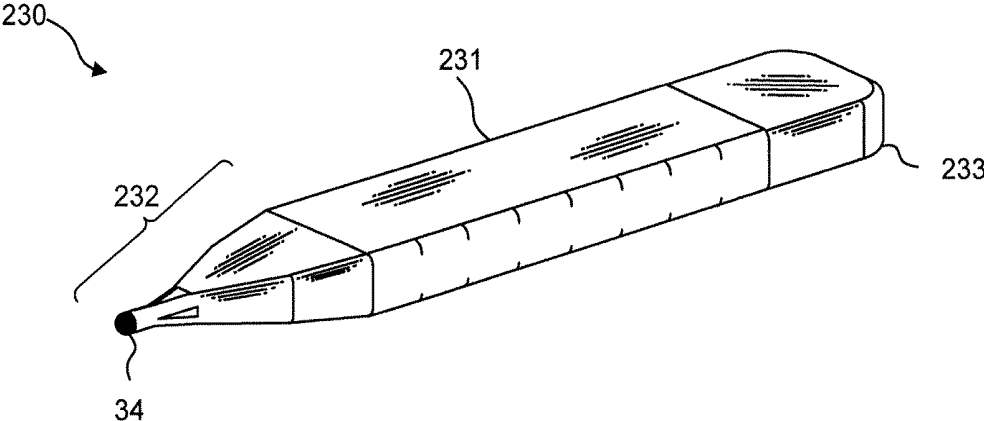
**Fig. 17.**



**Fig. 18.**



**Fig. 19.**



**Fig. 20.**

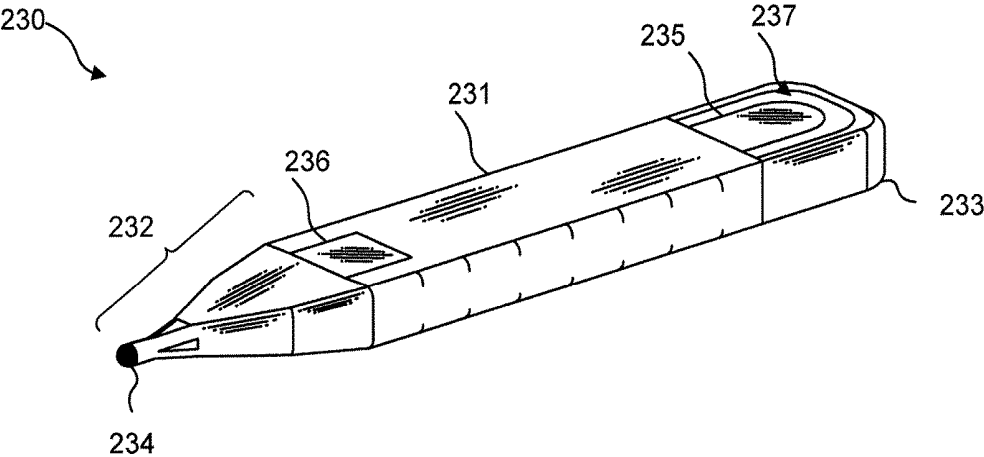


Fig. 21.

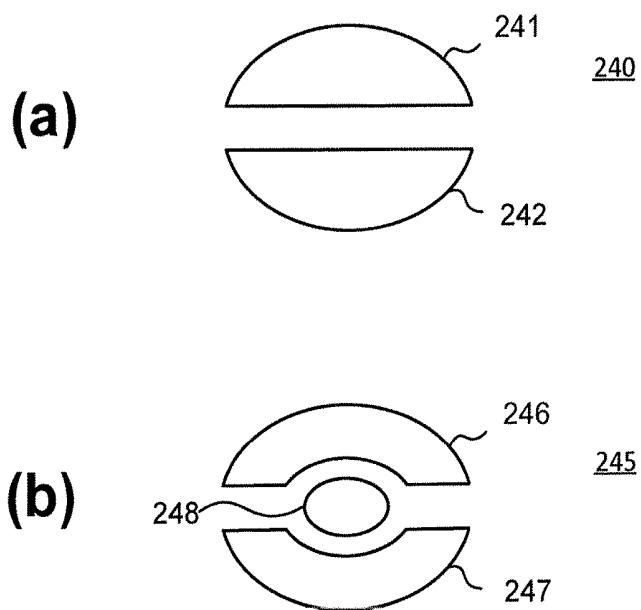
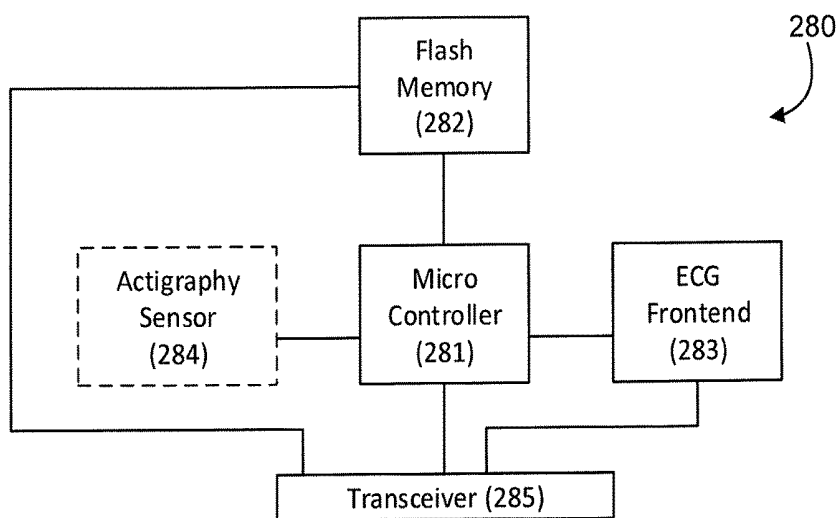


Fig. 22.



**SYSTEM AND METHOD FOR  
FACILITATING A CARDIAC RHYTHM  
DISORDER DIAGNOSIS BASED ON  
SUBCUTANEOUS CARDIAC MONITORING  
DATA**

CROSS-REFERENCE TO RELATED  
APPLICATION

**[0001]** This non-provisional patent application is a continuation-in-part of U.S. patent application Ser. No. 16/102,608, filed Aug. 13, 2018, pending, which is a continuation of U.S. Pat. No. 10,045,709, issued Aug. 14, 2018; which is a continuation of U.S. Pat. No. 9,408,551, issued Aug. 9, 2016; which is a continuation-in-part of U.S. Pat. No. 9,345,414, issued May 24, 2016; which is a continuation-in-part of U.S. Pat. No. 9,408,545, issued Aug. 9, 2016; which is a continuation-in-part of U.S. Pat. No. 9,700,227, issued Jul. 11, 2017; which is a continuation-in-part of U.S. Pat. No. 9,730,593, issued Aug. 15, 2017; and further claims priority under 35 U.S.C. § 119(e) to U.S. Provisional Patent Application Ser. No. 62/132,497, filed Mar. 12, 2015, and U.S. Provisional Patent Application Ser. No. 61/882,403, filed Sep. 25, 2013, the disclosures of which are incorporated by reference; this present non-provisional patent application is also a continuation-in-part of U.S. patent application Ser. No. 15/832,385, filed Dec. 5, 2017, pending, the disclosure of which is incorporated by reference.

FIELD

**[0002]** This application relates in general to electrocardiographic monitoring and, in particular, to a system and method for facilitating diagnosis of cardiac rhythm disorders based on subcutaneous cardiac monitoring data.

BACKGROUND

**[0003]** An electrocardiogram (ECG) allows physicians to diagnose cardiac function by visually tracing the cutaneous electrical signals (action potentials) that are generated by the propagation of the transmembrane ionic currents that trigger the depolarization of cardiac fibers. An ECG trace contains alphabetically-labeled waveform deflections that represent distinct features within the cyclic cardiac activation sequence. The P-wave represents atrial depolarization, which causes atrial contraction. The QRS-complex represents ventricular depolarization. The T-wave represents ventricular repolarization.

**[0004]** The R-wave is often used as an abbreviation for the QRS-complex. An R-R interval spans the period between successive R-waves and, in a normal heart, is 600 milliseconds (ms) to one second long, which respectively correspond to 100 to 60 beats per minute (bpm). The R-wave is the largest waveform generated during normal conduction and represents the cardiac electrical stimuli passing through the ventricular walls. R-R intervals provide information that allows a physician to understand at a glance the context of cardiac rhythms both before and after a suspected rhythm abnormality and can be of confirmational and collaborative value in cardiac arrhythmia diagnosis and treatment.

**[0005]** Conventionally, the potential of R-R interval context has not been fully realized, partly due to the difficulty of presentation in a concise and effective manner to physicians. For instance, routine ECGs are typically displayed at an effective paper speed of 25 millimeters (mm) per second. A

lower speed is not recommended because ECG graph resolution degrades at lower speeds and diagnostically-relevant features may be lost. Conversely, a half-hour ECG recording, progressing at 25 mm/s, results in 45 meters of ECG waveforms that, in printed form, is cumbersome and, in electronic display form, will require significant back and forth toggling between pages of waveforms, as well as presenting voluminous data transfer and data storage concerns. As a result, ECGs are less than ideal tools for diagnosing cardiac arrhythmia patterns that only become apparent over an extended time frame, such as 30 minutes or longer.

**[0006]** R-R intervals have also been visualized in Poincare plots, which graph  $RR(n)$  on the x-axis and  $RR(n+1)$  on the y-axis. However, a Poincare plot fails to preserve the correlation between an R-R interval and the R-R interval's time of occurrence and the linearity of time and associated contextual information, before and after a specific cardiac rhythm, are lost. In addition, significant changes in heart rate, particularly spikes in heart rate, such as due to sinus rhythm transitions to atrial flutter or atrial fibrillation, may be masked or distorted in a Poincare plot if the change occurs over non-successive heartbeats, rather than over two adjacent heartbeats, which undermines reliance on Poincare plots as dependable cardiac arrhythmia diagnostic tools. Further, Poincare plots cannot provide context and immediate temporal reference to the actual ECG, regardless of paper speed. Events both prior to and after a specific ECG rhythm can provide key clinical information disclosed in the R-R interval plot that may change patient management above and beyond the specific rhythm being diagnosed.

**[0007]** Further, in addition to the information that a physician can understand from an R-R interval plot, the P-wave is a critical component of arrhythmia monitoring and diagnosis performed every day hundreds of thousands of times across the United States. Without a knowledge of the relationship of these two basic symbols, heart rhythm disorders cannot be reliably diagnosed. Visualizing both the P-wave and the R-wave allow for the specific identification of a variety of atrial tachyarrhythmias (also known as supraventricular tachyarrhythmias, or SVTs), ventricular tachyarrhythmias (VTs), and bradycardias related to sinus node and atrioventricular (AV) node dysfunction. These categories are well understood by cardiologists but only accurately diagnosable if the P-wave and the R-wave are visualized and their relationship and behavior are clear. Visualization of the R-wave is usually readily achievable, as the R-wave is a high voltage, high frequency signal easily recorded from the skin's surface. However, as the ECG bipole spacing and electrode surface area decreases, even the R-wave can be a challenge to visualize. To make matters of rhythm identification more complicated, surface P-waves can be much more difficult to visualize from the surface because of their much lower voltage and signal frequency content. P-wave visualization becomes exacerbated further when the recording bipole inter-electrode spacing decreases.

**[0008]** Cardiac rhythm disorders may present with lightheadedness, fainting, chest pain, hypoxia, syncope, palpitations, and congestive heart failure (CHF), yet rhythm disorders are often sporadic in occurrence and may not show up in-clinic during a conventional 12-second ECG. Continuous ECG monitoring with P-wave-centric action potential acquisition over an extended period is more apt to capture sporadic cardiac events. However, recording sufficient ECG

and related physiological data over an extended period remains a significant challenge. For instance, maintaining continual contact between ECG electrodes of conventional ambulatory dermal ECG monitors and the skin after a day or two of ambulatory ECG monitoring has been a problem. Time, dirt, moisture, and other environmental contaminants, as well as perspiration, skin oil, and dead skin cells from the patient's body, can get between an ECG electrode's non-conductive adhesive and the skin's surface. These factors adversely affect electrode adhesion and the quality of cardiac signal recordings. Furthermore, the physical movements of the patient and their clothing impart various compressional, tensile, bending, and torsional forces on the contact point of an ECG electrode, especially over long recording times, and an inflexibly fastened ECG electrode will be prone to becoming dislodged. Moreover, dislodgment may occur unbeknownst to the patient, making the ECG recordings worthless. Further, some patients may have skin that is susceptible to itching or irritation, and the wearing of ECG electrodes can aggravate such skin conditions.

**[0009]** While subcutaneous ECG monitors can perform monitoring for an extended period of time, up to three years, such subcutaneous ECG monitors, because of their small size, have greater problems of demonstrating a clear and dependable P-wave. The issues related to a tiny atrial voltage are exacerbated by the small size of insertable cardiac monitors (ICMs), the signal processing limits imposed upon them by virtue of their reduced electrode size, and restricted inter-electrode spacing. Conventional subcutaneous ICMs, as well as most conventional surface ECG monitors, are notorious for poor visualization of the P-wave, which remains the primary reason that heart rhythm disorders cannot precisely be identified today from ICMs. Furthermore, even when physiologically present, the P-wave may not actually appear on an ECG because the P-wave's visibility is strongly dependent upon the signal capturing ability of the ECG recording device's sensing circuitry. This situation is further influenced by several factors, including electrode configuration, electrode surface areas and shapes, inter-electrode spacing; where the electrodes are placed on or within the body relative to the heart's atria. Further, the presence or absence of ambient noise and the means to limit the ambient noise is a key aspect of whether the low amplitude atrial signal can be seen.

**[0010]** Conventional ICMs are often used after diagnostic measures when dermal ECG monitors fail to identify a suspected arrhythmia. Consequently, when a physician is strongly suspicious of a serious cardiac rhythm disorder that may have caused loss of consciousness or stroke, for example, the physician will often proceed to the insertion of an ICM under the skin of the thorax. Although traditionally, the quality of the signal is limited with ICMs with respect to identifying the P-wave, the duration of monitoring is hoped to compensate for poor P-wave recording. This situation has led to a dependence on scrutiny of R-wave behavior, such as RR interval (R-wave-to-R-wave interval) behavior, often used as a surrogate for diagnosing atrial fibrillation, a potential cause of stroke. To a limited extent, this approach has some degree of value. Nevertheless, better recording of the P-wave would result in a significant diagnostic improvement, not only in the case of atrial fibrillation, but in a host of other rhythm disorders that can result in syncope or loss of consciousness, like VT or heart block.

**[0011]** As mentioned above, the P-wave is the most difficult ECG signal to capture by virtue of originating in the low tissue mass atria and having both low voltage amplitude and relatively low frequency content. Notwithstanding these physiological constraints, ICMs are popular, albeit limited in their diagnostic yield. The few ICMs that are commercially available today, including the Reveal LINQ ICM, manufactured by Medtronic, Inc., Minneapolis, Minn., the BioMonitor 2 (AF and S versions), manufactured by Biotronik SE & Co. KG, Berlin, Germany, and the Abbott Confirm Rx ICM, manufactured by Abbott Laboratories, Chicago, Ill., all are uniformly limited in their abilities to clearly and consistently sense, record, and deliver the P-wave.

**[0012]** Typically, the current realm of ICM devices use a loop recorder where cumulative ECG data lasting for around an hour is continually overwritten unless an episode of pre-programmed interest occurs or a patient marker is manually triggered. The limited temporal window afforded by the recordation loop is yet another restriction on the evaluation of the P-wave, and related cardiac morphologies, and further compromises diagnostic opportunities.

**[0013]** For instance, Medtronic's Reveal LINQ ICM delivers long-term subcutaneous ECG monitoring for up to three years, depending on programming. The monitor is able to store up to 59 minutes of ECG data, include up to 30 minutes of patient-activated episodes, 27 minutes of automatically detected episodes, and two minutes of the longest atrial fibrillation (AF) episode stored since the last interrogation of the device. The focus of the device is more directed to recording duration and programming options for recording time and patient interactions rather than signal fidelity. The Reveal LINQ ICM is intended for general purpose ECG monitoring and lacks an engineering focus on P-wave visualization. Moreover, the device's recording circuitry is intended to secure the ventricular signal by capturing the R-wave, and is designed to accommodate placement over a broad range of subcutaneous implantation sites, which is usually sufficient if one is focused on the R-wave given its amplitude and frequency content, but of limited value in capturing the low-amplitude, low-frequency content P-wave. Finally, electrode spacing, surface areas, and shapes are dictated (and limited) by the physical size of the monitor's housing which is quite small, an aesthetic choice, but unrealistic with respect to capturing the P-wave.

**[0014]** Similar in design is the titanium housing of Biotronik's BioMonitor 2 but with a flexible silicone antenna to mount a distal electrode lead, albeit of a standardized length. This standardized length mollifies, in one parameter only, the concerns of limited inter-electrode spacing and its curbing effect on securing the P-wave. None of the other factors related to P-wave signal revelation are addressed. Therefore the quality of sensed P-waves reflects a compromise caused by closely-spaced poles that fail to consistently preserve P-wave fidelity, with the reality of the physics imposed problems of signal-to-noise ratio limitations remaining mostly unaddressed.

**[0015]** Therefore, a need remains for a way to capture low amplitude cardiac action potential propagation during long term cardiac monitoring and to present R-R interval data to physicians to reveal temporally-related patterns as an aid to rhythm abnormality diagnosis.

## SUMMARY

**[0016]** R-R interval data is presented to physicians in a format that includes views of relevant near field and far field ECG data, which together provide contextual information that improves diagnostic accuracy. The near field (or short duration) ECG data view provides a “pinpoint” classical view of an ECG at traditional recording speed in a manner that is known to and widely embraced by physicians. The near field ECG data is coupled to a far field (or medium duration) ECG data view that provides an “intermediate” lower resolution, pre- and post-event contextual view.

**[0017]** Both near field and far field ECG data views are temporally keyed to an extended duration R-R interval data view. In one embodiment, the R-R interval data view is scaled non-linearly to maximize the visual differentiation for frequently-occurring heart rate ranges, such that a single glance allows the physician to make a diagnosis. All three views are presented simultaneously, thereby allowing an interpreting physician to diagnose rhythm and the pre- and post-contextual events leading up to a cardiac rhythm of interest.

**[0018]** The durations of the classical “pinpoint” view, the pre- and post-event “intermediate” view, and the R-R interval plot are flexible and adjustable. In one embodiment, a temporal point of reference is identified in the R-R interval plot and the ECG data that is temporally associated with the point of reference is displayed in the near field and far field ECG data views. In a further embodiment, diagnostically relevant cardiac events can be identified as the temporal point of reference. For clarity, the temporal point of reference will generally be placed in the center of the R-R interval data to allow pre- and post-event heart rhythm and ECG waveform data to present in the correct context. Thus, the pinpoint “snapshot” and intermediate views of ECG data with the extended term R-R interval data allow a physician to comparatively view heart rate context and patterns of behavior prior to and after a clinically meaningful arrhythmia, patient concern or other indicia, thereby enhancing diagnostic specificity of cardiac rhythm disorders and providing physiological context to improve diagnostic ability.

**[0019]** The ECG data from which the R-R interval plot is created can be obtained through a continuously-recording subcutaneous insertable cardiac monitor (ICM), such as one described in commonly-owned U.S. patent application Ser. No. 15/832,385, filed Dec. 5, 2017, pending, the disclosure of which is incorporated by reference. The sensing circuitry and the physical layout of the electrodes are specifically optimized to capture electrical signals from the propagation of low amplitude, relatively low frequency content cardiac action potentials, particularly the P-waves that are generated during atrial activation. In general, the ICM is intended to be implanted centrally and positioned axially and slightly to either the left or right of the sternal midline in the parasternal region of the chest.

**[0020]** In one embodiment, a system and method for facilitating a cardiac rhythm disorder diagnosis based on subcutaneous cardiac monitoring data. Cardiac action potentials of a patient over a set time period are recorded using an implantable housing comprised of a biocompatible material that is suitable for implantation within a living body; at least one pair of electrocardiographic (ECG) sensing electrodes provided on a ventral surface and on opposite ends of the implantable housing operatively placed to facilitate sensing in closest proximity to the low amplitude, low frequency

content cardiac action potentials that are generated during atrial activation; and electronic circuitry provided within the housing assembly comprising a low power microcontroller operable to execute under modular micro program control as specified in firmware, an ECG front end circuit interfaced to the microcontroller and configured to capture the cardiac action potentials sensed by the pair of ECG sensing electrodes which are output as ECG signals, and non-volatile memory electrically interfaced with the microcontroller and operable to continuously store samples of the ECG signals. The stored samples of the ECG signals as ECG data are retrieved. A set of R-wave peaks within the ECG data are identified. An R-R interval plot is constructed, including determining a difference between recording times of successive pairs of the R-wave peaks in the set; determining a heart rate associated with each difference; and plotting the pairs of the R-wave peaks and associated heart rate as the R-R interval plot. Diagnosis of a cardiac disorder of the patient based on patterns of the plotted pairs of the R-wave peaks and the associated heart rates in the R-R interval plot is facilitated. The foregoing aspects enhance the presentation of diagnostically relevant R-R interval data, reduce time and effort needed to gather relevant information by a clinician and provide the clinician with a concise and effective diagnostic tool, which is critical to accurate arrhythmia and cardiac rhythm disorder diagnoses.

**[0021]** Custom software packages have been used to identify diagnostically relevant cardiac events from the electrocardiography data, but usually require a cardiologist’s diagnosis and verification. In contrast, when presented with a machine-identified event, the foregoing approach aids the cardiologist’s diagnostic job by facilitating presentation of ECG-based background information prior to and after the identified event.

**[0022]** Still other embodiments will become readily apparent to those skilled in the art from the following detailed description, wherein are described embodiments by way of illustrating the best mode contemplated. As will be realized, other and different embodiments are possible and the embodiments’ several details are capable of modifications in various obvious respects, including time and clustering of events, all without departing from their spirit and the scope. Accordingly, the drawings and detailed description are to be regarded as illustrative in nature and not as restrictive.

## BRIEF DESCRIPTION OF THE DRAWINGS

**[0023]** FIG. 1 is a graph showing, by way of example, a single ECG waveform.

**[0024]** FIG. 2 is a graph showing, by way of example, a prior art Poincaré R-R interval plot.

**[0025]** FIG. 3 is a flow diagram showing a method for facilitating diagnosis of cardiac rhythm disorders with the aid of a digital computer in accordance with one embodiment.

**[0026]** FIG. 4 is a flow diagram showing a routine for constructing and displaying a diagnostic composite plot for use in the method of FIG. 3.

**[0027]** FIG. 5 is a flow diagram showing a routine for constructing an extended-duration R-R interval plot for use in the routine of FIG. 4.

**[0028]** FIG. 6 is a diagram showing, by way of example, a diagnostic composite plot generated by the method of FIG. 3.

**[0029]** FIG. 7 is a diagram showing, by way of example, a diagnostic composite plot for facilitating the diagnosis of sinus rhythm (SR) transitioning into atrial fibrillation (AF).

**[0030]** FIG. 8 is a diagram showing, by way of example, a diagnostic composite plot for facilitating the diagnosis of 3:1 atrial flutter (AFL) transitioning into SR.

**[0031]** FIG. 9 is a diagram showing, by way of example, a diagnostic composite plot for facilitating the diagnosis of atrial trigeminy.

**[0032]** FIG. 10 is a diagram showing, by way of example, a diagnostic composite plot for facilitating the diagnosis of maximum heart rate in an episode of AF during exercise.

**[0033]** FIG. 11 is a diagram showing, by way of example, a diagnostic composite plot for facilitating the diagnosis of SR transitioning into AFL transitioning into AF.

**[0034]** FIG. 12 is a diagram showing, by way of example, a diagnostic composite plot for facilitating the diagnosis of sinus tachycardia and palpitations that occurred during exercise accompanied by a jump in heart rate.

**[0035]** FIG. 13 is a diagram showing, by way of example, a diagnostic composite plot for facilitating the diagnosis of bradycardia.

**[0036]** FIG. 14 is a block diagram showing a system for facilitating diagnosis of cardiac rhythm disorders with the aid of a digital computer in accordance with one embodiment.

**[0037]** FIG. 15 is a diagram showing, by way of example, a subcutaneous P-wave centric insertable cardiac monitor (ICM) for long term electrocardiographic monitoring in accordance with one embodiment.

**[0038]** FIGS. 16 and 17 are respectively top and bottom perspective views showing the ICM of FIG. 15.

**[0039]** FIG. 18 is a bottom perspective view showing the ICM of FIG. 15 in accordance with a further embodiment.

**[0040]** FIGS. 19 and 20 are respectively top and bottom perspective views showing an ICM in accordance with a still further embodiment.

**[0041]** FIG. 21 is a plan view showing further electrode configurations.

**[0042]** FIG. 22 is a functional block diagram showing the P-wave focused component architecture of the circuitry of the ICM of FIG. 15.

#### DETAILED DESCRIPTION

**[0043]** A normal healthy cardiac cycle repeats through an expected sequence of events that can be visually traced through an ECG. Each cycle starts with cardiac depolarization originating high in the right atrium in the sinoatrial (SA) node before spreading leftward towards the left atrium and inferiorly towards the atrioventricular (AV) node. After a delay in the AV node, the depolarization impulse transits the Bundle of His and moves into the right and left bundle branches and Purkinje fibers to activate the right and left ventricles.

**[0044]** When a rhythm disorder is suspected, diagnostically-relevant arrhythmic events in the cardiac cycle can often be identified and evaluated with the assistance of an ECG and R-R interval tachography, such as Poincaré plots. Routine ECG evaluation is primarily focused identifying changes to expected ECG waveform shapes. FIG. 1 is a graph showing, by way of example, a single ECG waveform 10. The x-axis represents approximate time in units of tenths of a second and the y-axis represents approximate cutaneous electrical signal strength in units of millivolts. By long-

standing convention, ECGs are typically printed or displayed at an effective paper speed of 25 millimeters (mm) per second. Although in practice an ECG may be provided to a physician in traditional paper-printed form, in “virtual” electronic display form, or both, the term “effective paper speed” is nevertheless still widely applied as a metric to normalize the recorded ECG signal to a standardized grid of 1 mm squares (omitted for the sake of clarity in FIG. 1), whereby each 1 mm horizontal box in the grid corresponds to 0.04 s (40 ms) of recorded time. Other effective paper speeds, grid sizes and units of display are possible.

**[0045]** A full ECG consists of a stream of alphabetically-labeled waveforms 10 that collectively cover cardiac performance over a period of observation. For a healthy patient, within each ECG waveform 10, the P-wave 11 will normally have a smooth, normally upward, positive waveform that indicates atrial depolarization. The QRS complex 17 will usually follow, often with a downward deflection of a Q-wave 12, followed by a larger upward deflection of an R-wave 13, and be terminated with a downward waveform of the S-wave 14, which are collectively representative of ventricular depolarization. The T-wave 15 will normally be a modest upward waveform, representative of ventricular repolarization, while the U-wave 16, which is often not directly observable, will indicate the recovery period of the Purkinje conduction fibers.

**[0046]** Rhythm disorders often manifest through R-R interval variability and the patterns formed by R-R intervals over an extended time period are important tools in the diagnosis of cardiac rhythm abnormalities. For example, atrial fibrillation (AF) is the chaotic firing of the atria that leads to an erratic activation of the ventricles. AF is initially diagnosed by an absence of organized P-waves 11 and confirmed by erratic ventricular rates that manifest in an ECG R-R interval plot as a cloud-like pattern of irregular R-R intervals due to an abnormal conduction of impulses to the ventricles. There is a Gaussian-like distribution to these R-R intervals during AF. Similarly, atrial flutter (AFL) is an abnormal heart rhythm in which cardiac impulses travel along pathways within the right atrium in an organized circular motion, causing the atria to beat faster than and out of sync with the ventricles. During AFL, the heart beats quickly, yet with a regular pattern. Although AFL presents in an electrogram (e-gram) as a “sawtooth” pattern, AFL can be confirmed in an ECG by characteristic R-R interval patterns that usually manifest as 2:1 atrioventricular (AV) conduction or 4:1 atrioventricular conduction. On occasion, the conduction through the AV node is variable and not fixed.

**[0047]** Conventionally, R-R intervals have been visualized using Poincaré plots. FIG. 2 is a graph showing, by way of example, a prior art Poincaré R-R interval plot 18. The x-axis represents the duration of R-R interval  $n$  in units of milliseconds (ms). The y-axis represents the duration of R-R interval  $n+1$  also in units of ms. Ordinarily, the x- and y-axis use the same units, so as to form a trend line 19 along the 45-degree angle. When an R-R interval is equal to the successive R-R interval, as often occurs when heart rhythm is regular, the dot representing the two intervals falls onto the 45-degree trend line 19. Conversely, when an R-R interval has changed since the preceding R-R interval, the dot representing the two intervals falls off the 45-degree trend line 19 and, as the difference between successive R-R intervals increases, the dots fall further away from the trend line 19.

[0048] The number of dots deviating from the trend line **19** in a Poincare plot can indicate the frequency of occurrence of irregular heartbeats when compared to the number of dots on the trend line **19**. The distance of the dots to the trend line **19** can approximate the extent of heart rate change from one heartbeat to the next. However, as heart rate change is limited to only successively-occurring heartbeats, the linearity of time and associated contextual information over an extended time frame are lost. In addition, significant changes in heart rate, particularly spikes in heart rate, such as due to sinus rhythm transitions to atrial flutter, may be masked, distorted or even omitted in a Poincare plot if the change occurs over non-successive heartbeats. In summary, a Poincare plot is more useful as a mathematical tool than a physiological one, and therefore a Poincare plot cannot truly represent what the heart is doing serially over time with respect to changes in the heart's normal and abnormal physiology.

[0049] Despite the limitations of Poincare plots and related forms of R-R interval tachography, R-R interval data when presented in a format duplicating temporal physiological events remains a key tool that physicians can rely upon to identify temporally-related cardiac dysrhythmic patterns. Interpretation of R-R interval data can be assisted by including multiple temporal points of reference and a plot of R-R interval data that comparatively depicts heart rate variability in concert with R-R interval data. FIG. **3** is a flow diagram showing a method **20** for facilitating diagnosis of cardiac rhythm disorders with the aid of a digital computer in accordance with one embodiment. The method **20** can be implemented in software and execution of the software can be performed on a computer, such as further described infra with reference to FIG. **14**, as a series of process or method modules or steps.

[0050] As a precursor step, the cutaneous action potentials of a patient are monitored and recorded as ECG data over a set time period (step **21**), which can be over a short term or extended time frame. ECG recordation, as well as physiological monitoring, can be provided through various kinds of ECG-capable monitoring ensembles, including a standardized 12-lead ECG setup, such as used for clinical ECG monitoring, a portable Holter-type ECG recorder for traditional ambulatory ECG monitoring, or a wearable ambulatory ECG monitor, such as a flexible extended wear electrode patch and a removable reusable (or single use) monitor recorder, such as described in commonly-assigned U.S. patent application, entitled "Method for Providing Dynamic Gain over Electrocardiographic Data with the aid of a Digital Computer," Ser. No. 14/997,416, filed Jan. 15, 2016, pending, the disclosure of which is incorporated by reference, the latter of which includes an electrode patch and monitor recorder that are synergistically optimized to capture electrical signals from the propagation of low amplitude, relatively low frequency content cardiac action potentials, particularly the P-waves, generated during atrial activation. Still other forms of ECG monitoring assemblies are possible.

[0051] Upon completion of the monitoring period, the ECG and any physiological data are downloaded or retrieved into a digital computer, as further described infra with reference to FIG. **14**, with, for instance, the assistance of a download station or similar device, or via wireless connection, if so equipped, and a vector of the downloaded or retrieved ECG data is obtained (step **22**). In one embodi-

ment, the vector of ECG data represents a 40-minute (or other duration) time span that is used in constructing the plot of R-R interval data, although other pre-event and post-event time spans are possible. Optionally, a potentially-actionable cardiac event within the vector of ECG data can be identified and the ECG data during, prior to and after the event is selected (step **23**). The event could be identified with the assistance of a software package, such as Holter LX Analysis Software, licensed by NorthEast Monitoring, Inc., Maynard, Mass.; IntelliSpace Cardiovascular Image and Information management system, licensed Koninklijke Philips N.V., Amsterdam, Netherlands; MoMe System, licensed by InfoBionic, Lowell, Mass.; Pyramis ECG Management, licensed by Mortara Instrument Inc., Milwaukee, Wis.; ICS Clinical Suite, licensed by Spacelabs Healthcare Inc., Snoqualmie, Wash.; or a customized software package. Alternatively, the potentially-actionable cardiac event could be identified by a physician or technician during review of the ECG data.

[0052] To improve diagnosis of heart rate variability, a diagnostic composite plot is constructed that includes one or more temporal points of reference into the ECG data, which provide important diagnostic context, and a plot of R-R interval data is constructed based on the vector of ECG data (step **24**), as further described infra with reference to FIG. **4**. Briefly, both near field and far field contextual views of the ECG data are constructed and displayed. Both views are temporally keyed to an extended duration R-R interval data view that, in one embodiment, is scaled non-linearly to maximize the visual differentiation for frequently-occurring heart rate ranges, such that a single glance allows the physician to make a diagnosis. All three views are presented simultaneously, thereby allowing the interpreting physician to diagnose rhythm and the pre- and post-contextual events leading up to a cardiac rhythm of interest.

[0053] In a further embodiment, findings made through interpretation of heart rate variability patterns in the diagnostic composite plot can be analyzed to form a diagnosis of a cardiac rhythm disorder (step **25**), such as the cardiac rhythm disorders listed, by way of example, in Table 1. For instance, the heart rate variability patterns in the diagnostic composite plot could be provided to a system that programmatically detects AF by virtue of looking for the classic Gaussian-type distribution on the "cloud" of heart rate variability formed in the plot of R-R interval data, which can be corroborated by the accompanying contextual ECG data. Finally, therapy to address diagnosed disorder findings can optionally be programmed into a cardiac rhythm therapy delivery device (step **26**), such as an implantable medical device (IMD) (not shown), including a pacemaker, implantable cardioverter defibrillator (ICD), or similar devices.

TABLE 1

## Cardiac Rhythm Disorders

|   |
|---|
| Normal sinus rhythm                                       |
| Sinus Bradycardia   |
| Sinus Tachycardia   |
| Premature atrial and ventricular beats                    |
| Ectopic atrial tachycardia                                |
| Atrial fibrillation                                       |
| Atrial flutter  |
| Atrial or ventricular bigeminy, trigeminy or quadrigeminy |
| Sinus Bradycardia   |
| Fusion beats  |

TABLE 1-continued

| Cardiac Rhythm Disorders                          |
|---|
| Interpolated ventricular premature beats          |
| Intraventricular conduction delay                 |
| Junctional rhythm                                 |
| AV Nodal re-entrant tachycardia                   |
| AV re-entrant tachycardia                         |
| Wolff-Parkinson-White Syndrome and Pre-excitation |
| Ventricular tachycardia                           |
| Accelerated idioventricular rhythm                |
| AV Wenckebach block                               |
| AV Type II block                                  |
| Sinoatrial block                                  |

**[0054]** A diagnostic composite plot is constructed and displayed to help physicians identify and diagnose temporally-related cardiac dysrhythmic patterns. The diagnostic composite plot includes ECG traces from two or more temporal points of reference and a plot of R-R interval data, although other configurations of ECG data plots when combined with the R-R interval plot will also provide critical information. FIG. 4 is a flow diagram showing a routine 30 for constructing and displaying a diagnostic composite plot for use in the method 20 of FIG. 3. Specific examples of diagnostic composite plots are discussed in detail infra with reference to FIGS. 7-13.

**[0055]** In the diagnostic composite plot, R-R interval data is presented to physicians in a format that includes views of relevant near field and far field ECG data, which together provide contextual information that improves diagnostic accuracy. In a further embodiment, other views of ECG data can be provided in addition to or in lieu of the near field and far field ECG data views. The near field (or short duration) ECG data provides a “pinpoint” classical view of an ECG at traditional recording speed in a manner that is known to and widely embraced by physicians. The near field ECG data is coupled to a far field (or medium duration) ECG data view that provides an “intermediate” lower resolution, pre- and post-event contextual view. Thus, the extended-duration R-R interval plot is first constructed (step 31), as further described infra with reference to FIG. 5. Optionally, noise can be filtered from the R-R interval plot (step 32), which is then displayed (step 33). Noise filtering can include low-pass or high-pass filtering or other forms of signal processing, including automatic gain control, such as described in commonly-assigned U.S. patent application Ser. No. 14/997, 416, cited supra.

**[0056]** Rhythm disorders have different weightings depending upon the context with which they occur. In the diagnostic composite plot, the R-R interval data view and the multiple views of the ECG data provide that necessary context. Effectively, the short and medium duration ECG data that accompanies the extended-duration R-R interval plot represents the ECG data “zoomed” in around a temporal point of reference identified in the center (or other location) of the R-R interval plot, thereby providing a visual context to the physician that allows temporal assessment of cardiac rhythm changes in various complementary views of the heart’s behavior. The durations of the classical “pinpoint” view, the pre- and post-event “intermediate” view, and the R-R interval plot are flexible and adjustable. In one embodiment, the diagnostic composite plot displays R-R interval data over a forty-minute duration and ECG data over short and medium durations (steps 34 and 35), such as four-

second and 24-second durations that provide two- and 12-second segments of the ECG data before and after the R-R interval plot’s temporal point of reference, which is generally in the center of the R-R interval plot, although other locations in the R-R interval plot could be identified as the temporal point of reference. The pinpoint “snapshot” and intermediate views of ECG data with the extended term R-R interval data comparatively depicts heart rate context and patterns of behavior prior to and after a clinically meaningful arrhythmia or patient concern, thereby enhancing diagnostic specificity of cardiac rhythm disorders and providing physiological context to improve diagnostic ability. In a further embodiment, diagnostically relevant cardiac events can be identified and the R-R interval plot can be constructed with a cardiac event centered in the middle (or other location) of the plot, which thereby allows pre- and post-event heart rhythm data to be contextually “framed” through the pinpoint and intermediate ECG data views. Other durations, intervals and presentations of ECG data are possible.

**[0057]** The extended-duration R-R interval plot presents beat-to-beat heart rate variability in a format that is intuitive and contextual, yet condensed. The format of the R-R interval plot is selected to optimize visualization of cardiac events in a compressed, yet understandable field of view, that allows for compact presentation of the data akin to a cardiologists understanding of clinical events. FIG. 5 is a flow diagram showing a routine 40 for constructing an extended-duration R-R interval plot for use in the routine 30 of FIG. 4. The duration of the R-R interval plot can vary from less than one minute to the entire duration of the recording. Thus, a plurality of R-wave peaks is first selected out of the vector of ECG data (step 41) appropriate to the duration of the R-R interval plot to be constructed. For successive pairs of the R-wave peaks (steps 42-43), the difference between the recording times of the R-peaks is calculated (step 43). Each recording time difference represents the length of one heartbeat. The heart rate associated with the recording time difference is determined by taking an inverse of the recording time difference and normalizing the inverse to beats per minute (step 44). Taking the inverse of the recording time difference yields a heart rate expressed in beats per second, which can be adjusted by a factor of 60 to provide a heart rate expressed in bpm. Calculation of the differences between the recording times and the associated heart rate continues for all of the remaining pairs of the R-wave peaks (step 44).

**[0058]** The pairings of R-R intervals and associated heart rates are formed into a two-dimensional plot. R-R intervals are plotted along the x-axis and associated heart rates are plotted along the y-axis. The range and scale of the y-axis (heart rate) can be adjusted according to the range and frequency of normal or patient-specific heart rates, so as to increase the visual distinctions between the heart rates that correspond to different R-R intervals. In one embodiment, the y-axis of the R-R interval plot has a range of 20 to 300 beats per minute and R-R intervals corresponding to heart rates falling extremely outside of this range are excluded to allow easy visualization of 99+% of the heart rate possibilities.

**[0059]** In a further embodiment, they-axis has a non-linear scale that is calculated as a function of the x-axis (R-R interval), such that:

$$y = \left( \frac{x - \min \text{ bpm}}{\max \text{ bpm} - \min \text{ bpm}} \right)^n$$

where  $x$  is the time difference,  $\min \text{ bpm}$  is the minimum heart rate,  $\max \text{ bpm}$  is the maximum heart rate, and  $n < 1$ . The non-linear scale of the y-axis accentuates the spatial distance between successive heart rates when heart rate is low. For example, when  $n=2$ , the spatial difference between 50 and 60 bpm is 32% larger than the spatial difference between 90 bpm and 100 bpm, and 68% larger than the spatial difference between 150 bpm and 160 bpm. As a result the overall effect is to accentuate the spatial differences in frequently-occurring ranges of heart rate and de-emphasize the spatial differential in ranges of heart rate where a deviation from norm would have been apparent, thus maximizing the spatial efficiency in data presentation. The goal is to show cardiac events in a simple, small visual contextual format. Larger scales and larger formats bely the practical limits of single-page presentations for the easy visualization at a glance by the busy physician. The visual distinctions between the heart rates that correspond to different R-R intervals stand out, especially when plotted on a non-linear scale. Other y-axis ranges and scales are possible as may be selected by distinct clinical needs and specific diagnostic requirements.

**[0060]** The diagnostic composite plot includes a single, long range view of R-R interval data and a pair of pinpoint ECG data views that together help to facilitate rhythm disorder diagnosis by placing focused long-term heart rate information alongside short-term and medium-term ECG information. Such pairing of ECG and R-R interval data is unique in its ability to inform the physician of events prior to, during and after a cardiovascular event. FIG. 6 is a diagram showing, by way of example, a diagnostic composite plot 50 generated by the method 30 of FIG. 3. Note that the diagnostic composite plot can be tailored to include more than one view of R-R interval data and as many views of contextual ECG data as needed. In a further embodiment, a background information plot presenting an extended far field of related information can be included, such as activity amount, activity intensity, posture, syncope impulse detection, respiratory rate, blood pressure, oxygen saturation ( $\text{SpO}_2$ ), blood carbon dioxide level ( $\text{pCO}_2$ ), glucose, lung wetness, and temperature. Other forms of background information are possible. In a still further embodiment, background information can be layered on top of or keyed to the diagnostic composite plot 50, particularly at key points of time in the R-R interval data plot, so that the context provided by each item of background information can be readily accessed by the reviewing physician.

**[0061]** The diagnostic composite plot 50 includes an ECG plot presenting a near field (short duration) view 51, an ECG plot presenting an intermediate field (medium duration) view 52, and an R-R interval data plot presenting a far field (extended duration) view 53. The three views 51, 52, 53 are juxtaposed alongside one other to allow quick back and forth referencing of the full context of the heart's normal and abnormal physiology. Typically, a temporal point of reference, which could be a diagnostically relevant cardiac event, patient concern or other indicia, would be identified and centered on the x-axis in all three views. The placement of the temporal point of reference in the middle of all three x-axes enables the ECG data to be temporally keyed to the R-R interval data appearing in the center 60 of the R-R

interval data view 53, with a near field view 51 of an ECG displayed at normal (paper-based) recording speed and a far field view 52 that presents the ECG data occurring before and after the center 60. As a result, the near field view 51 provides the ECG data corresponding to the R-R interval data at the center 60 (or other location) in a format that is familiar to all physicians, while the intermediate field view 52 enables presentation of the broader ECG data context going beyond the borders of the near field view 51. In a further embodiment, the center 60 can be slidably adjusted backwards and forwards in time, with the near field view 51 and the far field view 52 of the ECG data automatically adjusting accordingly to stay in context with the R-R interval data view 51. In a still further embodiment, multiple temporal points of reference can be identified with each temporal point of reference being optionally accompanied by one or more dedicated sets of ECG data views.

**[0062]** The collection of plots are conveniently arranged close enough to one another to facilitate printing on a single page of standard sized paper (or physical paper substitute, such as a PDF file), although other layouts of the plots are possible. The far field view 53 is plotted with time in the x-axis and heart rate in the y-axis. The R-R intervals are calculated by measuring the time occurring between successive R-wave peaks. In one embodiment, the far field view 53 presents R-R interval data (expressed as heart rate in bpm) that begins about 20 minutes prior to and ends about 20 minutes following the center 60, although other durations are possible.

**[0063]** The near field view 51 and intermediate field view 52 present ECG data relative to the center 60 of the far field view 53. The near field view 51 provides a pinpoint or short duration view of the ECG data. In one embodiment, the near field view 51 presents ECG data 55 that begins about two seconds prior to and ends about two seconds following the center 60, although other durations are possible. The intermediate field view 52 provides additional contextual ECG information allowing the physician to assess the ECG itself and gather a broader view of the rhythm before and after a "blow-up" of the specific arrhythmia of interest. In one embodiment, the intermediate field view 52 presents ECG data 56 that begins about 12 seconds prior to and ends about 12 seconds following the center 60, although other durations are possible. For convenience, the eight-second interval of the ECG data 56 in the intermediate field view 52 that makes up the ECG data 56 in the near field view 51 is visually highlighted, here, with a surrounding box 57. In addition, other views of the ECG data, either in addition to or in lieu of the near field view 51 and the far field view 52 are possible. Optionally, an ECG plot presenting an extended far field view 54 of the background information can be included in the diagnostic composite plot 50. In one embodiment, the background information is presented as average heart rate with day and night periods 58 alternately shaded along the x-axis. Other types of background information, such as activity amount, activity intensity, posture, syncope impulse detection, respiratory rate, blood pressure, oxygen saturation ( $\text{SpO}_2$ ), blood carbon dioxide level ( $\text{pCO}_2$ ), glucose, lung wetness, and temperature, are possible.

**[0064]** Examples of the diagnostic composite plot as applied to specific forms of cardiac rhythm disorders will now be discussed. These examples help to illustrate the distinctive weightings that accompany different forms of rhythm disorders and the R-R interval and ECG waveform

deflection context with which they occur. FIG. 7 is a diagram showing, by way of example, a diagnostic composite plot 70 for facilitating the diagnosis of sinus rhythm (SR) transitioning into AF. SR is indicated through the presence of a reasonably steady baseline, but with subsidiary lines of premature beats and their compensatory pauses. SR manifests as a shadowing 71 of a high heart rate line and a low heart rate line. AF is characterized by irregular heartbeats with a somewhat random variation of R-R intervals, although within a limited range and concentrating in a Gaussian-like distribution pattern around a mean that varies over time. Although AF can be diagnosed by viewing a near field view 51 of ECG data showing heartbeats with reversed P-wave and irregular R-R intervals, this approach may be unclear when viewing “snippets” of ECG data, especially when associated with poor quality ECG signals. The presence of AF can also be confirmed through a far field view 53 of R-R interval data, in which the R-R intervals assume superficially appearing disorganized, spread-out and decentralized scattered cloud 72 along the x-axis, in comparison to a concentrated, darkened line typical of a more organized cardiac rhythm.

[0065] FIG. 8 is a diagram showing, by way of example, a diagnostic composite plot 80 for facilitating the diagnosis of 3:1 atrial flutter (AFL) transitioning into SR with frequent premature ectopic atrial beats. In the initial part of the R-R interval plot, the R-R intervals have a discernible aggregated line in the middle of the cloud 81 when the rhythm has yet to stabilize into a set pattern, not quite AF and not quite AFL. Immediately thereafter, a dense line representing firm 3:1 atrial flutter stabilizes the rhythm prior to the transition into SR associated with the presence of two seesawing baselines that result from frequent atrial ectopy causing short coupling intervals and then compensatory long coupling intervals. SR is indicated by the middle of the three lines with a low heart rate line consistent with the compensatory pause (long coupling interval) and a high heart rate line with the shortest coupling interval representing the series of atrial premature beats 82, and thus, at a faster heart rate.

[0066] FIG. 9 is a diagram showing, by way of example, a diagnostic composite plot 90 for facilitating the diagnosis of atrial trigeminy. Atrial trigeminy is characterized by three heartbeat rates appearing intermittently yet reasonably regularly. Although atrial trigeminy can be diagnosed by viewing a near field view 51 of ECG data, the pattern is significantly more recognizable in a far field view 53 of R-R interval data, in which a repeating pattern of three distinct heartbeat lines are persistently present and clearly visible 91. This view also provides the physician with a qualitative feel for the frequency of the event troubling the patient that is not discernible from a single ECG strip.

[0067] FIG. 10 is a diagram showing, by way of example, a diagnostic composite plot 100 for facilitating the diagnosis of maximum heart rate in an episode of AF during exercise. In a far field view 50 of R-R interval data, AF manifests through a dispersed cloud of dots (Gaussian-like distribution) without a discernible main heart rate line representing regular heartbeats 101. Under exercise, the maximum heart-beat can be located by an increase in heart rate clustered about the cloud 102. In addition, individual dots above the 200 bpm range throughout the entire 40-minute range indicates the maximum heart rate during exercise. The very rapid rise in heart rate can be critical to patient management, as such bumps in rate by exercise can prove serious and even

trigger cardiac arrest. Their very presence is easily visualized in the R-R interval data plot, thereby allowing the physician to alter therapy sufficiently to control such potentially damaging rises in heart rate.

[0068] FIG. 11 is a diagram showing, by way of example, a diagnostic composite plot 110 for facilitating the diagnosis of SR transitioning into AFL transitioning into AF. In a far field view 53 of R-R interval data, SR manifests as an uneven main heart rate line with a fluctuating height 111. At the onset of AFL, the main heart rate line breaks away at a lower heart rate than the SR main heart rate line 112. The episode of AFL further evolves into AF as characterized by a dispersed cloud of irregular heartbeats without concentrated heart rate lines 113. This view provides critical information to the physician managing AF patients in that, at a glance, the view provides data that tells the physician that the patient’s AF may be the consequence of AFL. Such knowledge may alter both drug and procedure therapies, like catheter ablation details of intervention.

[0069] FIG. 12 is a diagram showing, by way of example, a diagnostic composite plot 120 for facilitating the diagnosis of sinus tachycardia and palpitations that occurred during exercise accompanied by a jump in heart rate. In a far field view 50 of R-R interval data, sinus tachycardia is indicated by the presence of a baseline heart rate of about 60 bpm 121 that spikes up to around 100 bpm 122 and gradually slopes down with a wide tail 123, reflecting a sharp rise of heart rates followed by a gradual decline. The associated ECG data in the near field and intermediate field views (not shown) can confirm the rhythm as sinus rhythm and a normal response to exercise. This rhythm, although superficially obvious, was associated with symptoms of palpitations and demonstrates a sensitivity to heart rate fluctuations, rather than a sensitivity to an arrhythmia. This common problem is often dismissed as merely sinus tachycardia, rather than recognizing the context of a changing rate that generated the patient’s complaint, a problem, visible only in the R-R interval data plot.

[0070] FIG. 13 is a diagram showing, by way of example, a diagnostic composite plot 90 for facilitating the diagnosis of bradycardia during sleep and a R-R interval pattern characteristic of sleep. Bradycardia refers to a resting heart rate of under 60 bpm. Bradycardia during sleep is often tempered with occasional spikes of rapid heart rate, which can be a secondary compensatory response to dreaming, snoring or sleep apnea. In a far field view 50 of R-R interval data, bradycardia manifests as the presence of a base line heart rate in the range of about 50 bpm 131, coupled with multiple spikes of dots 132 representing intermittent episodes of elevated heart rate. Such elevations in heart rate during a pre-dominantly slower rate may be signs of a cardio-respiratory disorder. Still other applications of the diagnostic composite plot 80 are possible.

[0071] The diagnostic composite plots are a tool used by physicians as part of a continuum of cardiac care provisioning that begins with ECG monitoring, continues through diagnostic overread and finally, if medically appropriate, concludes with cardiac rhythm disorder treatment. Each of these steps involve different physical components that collaboratively allow physicians to acquire and visualize R-R interval and ECG data in a way that accurately depicts heart rate variability over time. FIG. 14 is a block diagram showing a system 140 for facilitating diagnosis of cardiac rhythm disorders with the aid of a digital computer 150 in

accordance with one embodiment. Each diagnostic composite plot **151** is based on ECG data **166** that has either been recorded by a conventional electrocardiograph (not shown) or retrieved or obtained from some other type of ECG monitoring and recording device. Following completion of the ECG monitoring, the ECG data is assembled into a diagnostic composite plot **151**, which can be used by a physician to diagnosis and, if required, treat a cardiac rhythm disorder, or for other health care or related purposes.

**[0072]** Each diagnostic composite plot **151** is based on ECG data **166** that has been recorded over a period of observation, which can be for just a short term, such as during a clinic appointment, or over an extended time frame of months. ECG recordation and, in some cases, physiological monitoring can be provided through various types of ECG-capable monitoring ensembles, including a standardized 12-lead ECG setup (not shown), such as used for clinical ECG monitoring, a portable Holter-type ECG recorder for traditional ambulatory ECG monitoring (also not shown), or a wearable ambulatory ECG monitor.

**[0073]** One form of ambulatory ECG monitor **142** particularly suited to monitoring and recording ECG and physiological data employs an electrode patch **143** and a removable reusable (or single use) monitor recorder **144**, such as described in commonly-assigned U.S. patent application Ser. No. 14/997,416, cited supra. The electrode patch **143** and monitor recorder **144** are synergistically optimized to capture electrical signals from the propagation of low amplitude, relatively low frequency content cardiac action potentials, particularly the P-waves generated during atrial activation. The ECG monitor **142** sits centrally (in the midline) on the patient's chest along the sternum **169** oriented top-to-bottom. The ECG monitor **142** interfaces to a pair of cutaneous electrodes (not shown) on the electrode patch **143** that are adhered to the patient's skin along the sternal midline (or immediately to either side of the sternum **169**). The ECG monitor **142** has a unique narrow "hourglass"-like shape that significantly improves the ability of the monitor to be comfortably worn by the patient **141** for an extended period of time and to cutaneously sense cardiac electric signals, particularly the P-wave (or atrial activity) and, to a lesser extent, the QRS interval signals in the ECG waveforms indicating ventricular activity.

**[0074]** The electrode patch **143** itself is shaped to conform to the contours of the patient's chest approximately centered on the sternal midline. To counter the dislodgment due to compressional and torsional forces, a layer of non-irritating adhesive, such as hydrocolloid, is provided at least partially on the underside, or contact, surface of the electrode patch, but only on the electrode patch's distal and proximal ends. To counter dislodgment due to tensile and torsional forces, a strain relief is defined in the electrode patch's flexible circuit using cutouts partially extending transversely from each opposite side of the flexible circuit and continuing longitudinally towards each other to define in 'S'-shaped pattern. In a further embodiment, the electrode patch **143** is made from a type of stretchable spunlace fabric. To counter patient bending motions and prevent disadhesion of the electrode patch **143**, the outward-facing aspect of the backing, to which a (non-stretchable) flexible circuit is fixedly attached, stretches at a different rate than the backing's skin-facing aspect, where a skin adhesive removably affixes the electrode patch **143** to the skin. Each of these components are distinctive and allow for comfortable and extended

wear, especially by women, where breast mobility would otherwise interfere with ECG monitor use and comfort. Still other forms of ECG monitoring and recording assemblies are possible.

**[0075]** When operated standalone, the monitor recorder **142** senses and records the patient's ECG data **166** and physiological data (not shown) into a memory onboard the monitor recorder **144**. The recorded data can be downloaded using a download station **145**, which could be a dedicated download station **145** that permits the retrieval of stored ECG data **166** and physiological data, if applicable, execution of diagnostics on or programming of the monitor recorder **144**, or performance of other functions. To facilitate physical connection with the download station **145**, the monitor recorder **144** has a set of electrical contacts (not shown) that enable the monitor recorder **144** to physically interface to a set of terminals **148**. In turn, the download station **145** can be operated through user controls **149** to execute a communications or data download program **146** ("Download") or similar program that interacts with the monitor recorder **144** via the physical interface to retrieve the stored ECG data **166**. The download station **145** could alternatively be a server, personal computer, tablet or handheld computer, smart mobile device, or purpose-built device designed specific to the task of interfacing with a monitor recorder **144**. Still other forms of download station **145** are possible. In a further embodiment, the ECG data **166** from the monitor recorder **144** can be offloaded wirelessly.

**[0076]** The ECG data **166** can be retrieved from the download station **145** using a control program **157** ("Ctl") or analogous application executing on a personal digital computer **156** or other connectable computing device, via a hard wired link **158**, wireless link (not shown), or by physical transfer of storage media (not shown). The personal digital computer **156** may also execute middleware (not shown) that converts the ECG data **166** into a format suitable for use by a third-party post-monitoring analysis program. The personal digital computer **156** stores the ECG data **166** along with each patient's electronic medical records (EMRs) **165** in the secure database **64**, as further discussed infra. In a further embodiment, the download station **145** is able to directly interface with other devices over a computer communications network **155**, which could be a combination of local area and wide area networks, including the Internet or another telecommunications network, over wired or wireless connections.

**[0077]** A client-server model can be employed for ECG data **166** analysis. In this model, a server **62** executes a patient management program **160** ("Mgt") or similar application that accesses the retrieved ECG data **166** and other information in the secure database **164** cataloged with each patient's EMRs **165**. The patients' EMRs can be supplemented with other information (not shown), such as medical history, testing results, and so forth, which can be factored into automated diagnosis and treatment. The patient management program **160**, or other trusted application, also maintains and safeguards the secure database **164** to limit access to patient EMRs **165** to only authorized parties for appropriate medical or other uses, such as mandated by state or federal law, such as under the Health Insurance Portability and Accountability Act (HIPAA) or per the European Union's Data Protection Directive. Other schemes and safeguards to protect and maintain the integrity of patient EMRs **165** are possible.

**[0078]** In a further embodiment, the wearable monitor **142** can interoperate wirelessly with other wearable or implantable physiology monitors and activity sensors **152**, such as activity trackers worn on the wrist or body, and with mobile devices **153**, including smart watches and smartphones. Wearable or implantable physiology monitors and activity sensors **152** encompass a wide range of wirelessly interconnectable devices that measure or monitor a patient's physiological data, such as heart rate, temperature, blood pressure, respiratory rate, blood pressure, blood sugar (with or without an appropriate subcutaneous probe), oxygen saturation, minute ventilation, and so on; physical states, such as movement, sleep, footsteps, and the like; and performance, including calories burned or estimated blood glucose level. Frequently, wearable and implantable physiology monitors and activity sensors **152** are capable of wirelessly interfacing with mobile devices **153**, particularly smart mobile devices, including so-called "smartphones" and "smart watches," as well as with personal computers and tablet or handheld computers, to download monitoring data either in real-time or in batches through an application ("App") or similar program.

**[0079]** Based on the ECG data **166**, physicians can rely on the data as medically certifiable and are able to directly proceed with diagnosing cardiac rhythm disorders and determining the appropriate course of treatment for the patient **141**, including undertaking further medical interventions as appropriate. The ECG data **166** can be retrieved by a digital computer **150** over the network **155**. A diagnostic composite plot **151** that includes multiple temporal points of reference and a plot of R-R interval data is then constructed based on the ECG data **166**, as discussed in detail supra with reference to FIG. 3, and displayed or, alternatively, printed, for use by a physician.

**[0080]** In a further embodiment, the server **159** executes a patient diagnosis program **161** ("Dx") or similar application that can evaluate the ECG data **166** to form a diagnosis of a cardiac rhythm disorder. The patient diagnosis program **161** compares and evaluates the ECG data **166** to a set of medical diagnostic criteria **167**, from which a diagnostic overread **162** ("diagnosis") is generated. Each diagnostic overread **162** can include one or more diagnostic findings **168** that can be rated by degree of severity, such as with the automated diagnosis of atrial fibrillation. If at least one of the diagnostic findings **168** for a patient exceed a threshold level of tolerance, which may be tailored to a specific client, disease or medical condition group, or applied to a general patient population, in a still further embodiment, therapeutic treatment ("Therapy") to address diagnosed disorder findings can be generated and, optionally, programmed into a cardiac rhythm therapy delivery device, such as an IMD (not shown), including a pacemaker, implantable cardioverter defibrillator (ICD), or similar devices.

**[0081]** In a further embodiment, the ECG data **166** can be recorded using a subcutaneous insertable cardiac monitor. Long-term electrocardiographic and physiological monitoring over a period lasting up to several years in duration can be provided through a continuously-recording subcutaneous insertable cardiac monitor (ICM), such as one described in commonly-owned U.S. patent application Ser. No. 15/832,385, filed Dec. 5, 2017, pending, the disclosure of which is incorporated by reference. FIG. 15 is a diagram showing, by way of example, a subcutaneous P-wave centric ICM **212** for long term electrocardiographic monitoring in accordance

with one embodiment. The ICM **212** is implanted in the parasternal region **211** of a patient **210**. The sensing circuitry and components, compression algorithms, and the physical layout of the electrodes are specifically optimized to capture electrical signals from the propagation of low amplitude, relatively low frequency content cardiac action potentials, particularly the P-waves generated during atrial activation. The position and placement of the ICM **212** coupled to engineering considerations that optimize the ICM's sensing circuitry, discussed infra, aid in demonstrating the P-wave clearly.

**[0082]** Implantation of a P-wave centric ICM **212** in the proper subcutaneous site facilitates the recording of high quality ECG data with a good delineation of the P-wave. In general, the ICM **212** is intended to be implanted anteriorly and be positioned axially and slightly to either the right or left of the sternal midline in the parasternal region **211** of the chest, or if sufficient subcutaneous fat exists, directly over the sternum. Optimally, the ICM **212** is implanted in a location left parasternally to bridge the left atrial appendage. However, either location to the right or left of the sternal midline is acceptable; placement of the device, if possible, should bridge the vertical height of the heart, which lies underneath the sternum **203**, thereby placing the ICM **212** in close proximity to the anterior right atrium and the left atrial appendage that lie immediately beneath.

**[0083]** The ICM **212** is shaped to fit comfortably within the body under the skin and to conform to the contours of the patient's parasternal region **211** when implanted immediately to either side of the sternum **203**, but could be implanted in other locations of the body. In most adults, the proximal end **213** of the ICM **212** is generally positioned below the manubrium **8** but, depending upon patient's vertical build, the ICM **212** may actually straddle the region over the manubrium **8**. The distal end **214** of the ICM **212** generally extends towards the xiphoid process **9** and lower sternum but, depending upon the patient's build, may actually straddle the region over or under the xiphoid process **9**, lower sternum and upper abdomen.

**[0084]** Although internal tissues, body structures, and tissue boundaries can adversely affect the current strength and signal fidelity of all body surface potentials, subsurface low amplitude cardiac action potentials, particularly P-wave signals with a normative amplitude of less than 0.25 millivolts (mV) and a normative duration of less than 120 milliseconds (ms), are most apt to be negatively impacted by these factors. The atria, which generate the P wave, are mostly located posteriorly within the thoracic cavity (with the exception of the anterior right atrium, right atrial appendage and left atrial appendage). The majority of the left atrium constitutes the portion of the heart furthest away from the surface of the skin on the chest and harbors the atrial tissue most likely to be the source of serious arrhythmias, like atrial fibrillation. Conversely, the ventricles, which generate larger amplitude signals, are located anteriorly as in the case of the anterior right ventricle and most of the anterior left ventricle situated relatively close to the skin surface of the central and left anterior chest. These factors, together with larger size and more powerful impulse generation from the ventricles, contribute to the relatively larger amplitudes of ventricular waveforms.

**[0085]** Nevertheless, both the P-wave and the R-wave are required for the physician to make a proper rhythm diagnosis from the dozens of arrhythmias that can occur. Yet, the

quality of P-waves is more susceptible to weakening from distance and the intervening tissues and structures and from signal attenuation and signal processing than the high voltage waveforms associated with ventricular activation. The added value of avoiding further signal attenuation resulting from dermal impedance makes a subcutaneous P-wave centric ICM even more likely to match, or even outperform dermal ambulatory monitors designed to analogous engineering considerations and using similar sensing circuitry and components, compression algorithms, and physical layout of electrodes, such as described in U.S. Pat. No. 9,545,204, issued January 21, 2017 to Bishay et al.; U.S. Pat. No. 9,730,593, issued Aug. 15, 2017 to Felix et al.; U.S. Pat. No. 9,700,227, issued Jul. 11, 2017 to Bishay et al.; U.S. Pat. No. 9,721,433, issued Aug. 1, 2017 to Felix et al.; and U.S. Pat. No. 9,615,763, issued Apr. 11, 2017 to Felix et al., the disclosures of which are incorporated by reference.

**[0086]** The ICM **212** can be implanted in the patient's chest using, for instance, a minimally invasive subcutaneous implantation instrument or other suitable surgical implement. The ICM **212** is positioned slightly to the right or left of midline, covering the center third of the chest, roughly between the second and sixth ribs, approximately spanning between the level of the manubrium **8** and the level of the xiphoid process **9** on the inferior border of the sternum **203**, depending upon the vertical build of the patient **210**.

**[0087]** During monitoring, the amplitude and strength of action potentials sensed by an ECG device, including dermal ECG monitors and ICMs, can be affected to varying degrees by cardiac, cellular, extracellular, vector of current flow, and physical factors, like obesity, dermatitis, lung disease, large breasts, and high impedance skin, as can occur in dark-skinned individuals. Performing ECG sensing subcutaneously in the parasternal region **211** significantly improves the ability of the ICM **212** to counter some of the effects of these factors, particularly high skin impedance and impedance from subcutaneous fat. Thus, the ICM **212** exhibits superior performance when compared to conventional dermal ECG monitors to existing implantable loop recorders, ICMs, and other forms of implantable monitoring devices by virtue of its engineering and proven P-wave documentation above the skin, as discussed in W. M. Smith et al., "Comparison of diagnostic value using a small, single channel, P-wave centric sternal ECG monitoring patch with a standard 3-lead Holter system over 24 hours," *Am. Heart J.*, March 20217; 2185:67-73, the disclosure of which is incorporated by reference.

**[0088]** Moreover, the sternal midline implantation location in the parasternal region **211** allows the ICM's electrodes to record an ECG of optimal signal quality from a location immediately above the strongest signal-generating aspects of the atrial. Signal quality is improved further in part because cardiac action potential propagation travels simultaneously along a north-to-south and right-to-left vector, beginning high in the right atrium and ultimately ending in the posterior and lateral region of the left ventricle. Cardiac depolarization originates high in the right atrium in the SA node before concurrently spreading leftward towards the left atrium and inferiorly towards the atrioventricular (AV) node. On the proximal end **213**, the ECG electrodes of the ICM **212** are subcutaneously positioned with the upper or superior pole (ECG electrode) slightly to the right or left of the sternal midline in the region of the manubrium **8** and,

on the distal end **214**, the lower or inferior pole (ECG electrode) is similarly situated slightly to the right or left of the sternal midline in the region of the xiphoid process **9** and lower sternum **203**. The ECG electrodes of the ICM **212** are placed primarily in a north-to-south orientation along the sternum **203** that corresponds to the north-to-south waveform vector exhibited during atrial activation. This orientation corresponds to the aVF lead used in a conventional 12-lead ECG that is used to sense positive or upright P-waves. In addition, the electrode spacing and the electrodes' shapes and surface areas mimic the electrodes used in the ICM's dermal cousin, designed as part of the optimal P-wave sensing electrode configuration, such as provided with the dermal ambulatory monitors cited supra.

**[0089]** Despite the challenges faced in capturing low amplitude cardiac action potentials, the ICM **212** is able to operate effectively using only two electrodes that are strategically sized and placed in locations ideally suited to high fidelity P-wave signal acquisition. This approach has been shown to clinically outperform more typical multi-lead monitors because of the improved P-wave clarity, as discussed in W. M. Smith et al., cited supra. FIGS. **16** and **17** are respectively top and bottom perspective views showing the ICM **212** of FIG. **1**. Physically, the ICM **212** is constructed with a hermetically sealed implantable housing **215** with at least one ECG electrode forming a superior pole on the proximal end **213** and at least one ECG electrode forming an inferior pole on the distal end **214**.

**[0090]** When implanted, the housing **215** is oriented most cephalad. The housing **215** is constructed of titanium, stainless steel or other biocompatible material. The housing **215** contains the sensing, recordation and interfacing circuitry of the ICM **212**, plus a long life battery. A wireless antenna is integrated into or within the housing **215** and can be positioned to wrap around the housing's internal periphery or location suited to signal reception. Other wireless antenna placement or integrations are possible.

**[0091]** Physically, the ICM **212** has four ECG electrodes **216**, **217**, **218**, **219**. There could also be additional ECG electrodes, as discussed infra. The ECG electrodes include two ventral (or dorsal) ECG electrodes **218**, **219** and two wraparound ECG electrodes **216**, **217**. One ventral ECG electrode **218** is formed on the proximal end **213** and one ventral ECG electrode **219** is formed on the distal end **214**. One wraparound ECG electrode **216** is formed circumferentially about the proximal end **213** and one wraparound ECG electrode **217** is formed circumferentially about the distal end **214**. Each wraparound ECG electrode **216**, **217** is electrically insulated from its respective ventral ECG electrode **218**, **219** by a periphery **220**, **221**.

**[0092]** The four ECG electrodes **216**, **217**, **218**, **219** are programmatically controlled by a microcontroller through onboard firmware programming to enable a physician to choose from several different electrode configurations that vary the electrode surface areas, shapes, and inter-electrode spacing. The sensing circuitry can be programmed, either pre-implant or in situ, to use different combinations of the available ECG electrodes (and thereby changing electrode surface areas, shapes, and inter-electrode spacing), including pairing the two ventral ECG electrodes **216**, **217**, the two wraparound ECG electrodes **218**, **219**, or one ventral ECG electrode **216**, **217** with one wraparound ECG electrode **218**, **219** located on the opposite end of the housing **215**. In addition, the periphery **220**, **221** can be programmatically

controlled to logically combine the wraparound ECG electrode **216**, **217** on one end of the ICM **212** with its corresponding ventral ECG electrode **218**, **219** to form a single virtual ECG electrode with larger surface area and shape. (Although electronically possible, the two ECG electrodes that are only on one end of the ICM **212**, for instance, wraparound ECG electrode **216** and ventral ECG electrode **218**, could be paired; however, the minimal inter-electrode spacing would likely yield a signal of poor fidelity in most situations.)

[0093] In a further embodiment, the housing **215** and contained circuitry can be provided as a standalone ICM core assembly to which a pair of compatible ECG electrodes can be operatively coupled to form a full implantable ICM device.

[0094] Other ECG electrode configurations are possible. For instance, additional ECG electrodes can be provided to increase the number of possible electrode configurations, all of which are to ensure better P-wave resolution. FIG. **18** is a bottom perspective view showing the ICM **212** of FIG. **15** in accordance with a further embodiment. An additional pair of ventral ECG electrodes **222**, **223** are included on the housing's ventral surface. These ventral ECG electrodes **222**, **223** are spaced closer together than the ventral ECG electrodes **218**, **219** on the ends of the housing **215** and a physician can thus choose to pair the two inner ventral ECG electrodes **222**, **223** by themselves to allow for minimal electrode-to-electrode spacing, or with the other ECG electrodes **216**, **217**, **218**, **219** to vary electrode surface areas, shapes, and inter-electrode spacing even further to explore optimal configurations to acquire the P-wave.

[0095] Other housing configurations of the ICM are possible. For instance, the housing of the ICM can be structured to enhance long term comfort and fitment, and to accommodate a larger long life battery or more circuitry or features, including physiologic sensors, to provide additional functionality. FIGS. **19** and **20** are respectively top and bottom perspective views showing an ICM **230** in accordance with a still further embodiment. The ICM **230** has a housing **31** with a tapered extension **32** that is terminated on the distal end with an electrode **34**. On a proximal end, the housing **31** includes a pair of ECG electrodes electrically insulated by a periphery **37** that include a ventral ECG electrode **33** and a wraparound ECG electrode **34**. In addition, a ventral ECG electrode **36** is oriented on the housing's distal end before the tapered extension **32**. Still other housing structures and electrode configurations are possible.

[0096] In general, the basic electrode layout is sufficient to sense cardiac action potentials in a wide range of patients. Differences in thoracic tissue density and skeletal structure from patient to patient, though, can affect the ability of the sensing electrodes to efficaciously capture action potential signals, yet the degree to which signal acquisition is affected may not be apparent until after an ICM has been implanted and deployed, when the impacts of the patient's physical constitution and his patterns of mobility and physical movement on ICM monitoring can be fully assessed.

[0097] In further embodiments, the electrodes can be configured post-implant to allow the ICM to better adapt to a particular patient's physiology. For instance, electrode configurations having more than two sensing electrodes are possible. FIG. **21** is a plan view showing further electrode configurations. Referring first to FIG. **21(a)**, a single disc ECG electrode **40** could be bifurcated to form a pair of

half-circle ECG electrodes **241**, **242** that could be programmatically selected or combined to accommodate a particular patient's ECG signal characteristics post-ICM implant. Referring next to FIG. **21(b)**, a single disc ECG electrode **245** could be divided into three sections, a pair of crescent-shaped ECG electrodes **246**, **247** surrounding a central semicircular ECG electrode **48** that could similarly be programmatically selected or combined. Still other ECG electrode configurations are possible.

[0098] ECG monitoring and other functions performed by the ICM **212** are provided through a micro controlled architecture. FIG. **22** is a functional block diagram showing the P-wave focused component architecture of the circuitry **280** of the ICM **212** of FIG. **15**. The circuitry **280** is powered through the long life battery **21** provided in the housing **215**. Operation of the circuitry **280** of the ICM **212** is managed by a microcontroller **281**, such as the EFM32 Tiny Gecko 32-bit microcontroller, manufactured by Silicon Laboratories Inc., Austin, Tex. The microcontroller **281** has flexible energy management modes and includes a direct memory access controller and built-in analog-to-digital and digital-to-analog converters (ADC and DAC, respectively). The microcontroller **281** also includes a program memory unit containing internal flash memory (not shown) that is readable, writeable, and externally programmable.

[0099] The microcontroller **281** operates under modular micro program control as specified in firmware stored in the internal flash memory. The microcontroller **281** draws power from the battery provided in the housing **215** and connects to the ECG front end circuit **283**. The front end circuit **283** measures raw subcutaneous electrical signals using a driven reference signal that eliminates common mode noise, as further described infra.

[0100] The circuitry **280** of the ICM **212** also includes a flash memory **82** external to the microcontroller **281**, which the microcontroller **281** uses for continuously storing samples of ECG monitoring signal data and other physiology, such as respiratory rate, blood oxygen saturation level (SpO<sub>2</sub>), blood pressure, temperature sensor, and physical activity, and device and related information. The flash memory **82** also draws power from the battery provided in the housing **215**. Data is stored in a serial flash memory circuit, which supports read, erase and program operations over a communications bus. The flash memory **82** enables the microcontroller **281** to store digitized ECG data. The communications bus further enables the flash memory **82** to be directly accessed wirelessly through a transceiver **285** coupled to an antenna **217** built into (or provided with) the housing **215**. The transceiver **285** can be used for wirelessly interfacing over Bluetooth or other types of wireless technologies for exchanging data over a short distance with a paired mobile device, including smartphones and smart watches, that are designed to communicate over a public communications infrastructure, such as a cellular communications network, and, in a further embodiment, other wearable (or implantable) physiology monitors, such as activity trackers worn on the wrist or body. Other types of device pairings are possible, including with a desktop computer or purpose-built bedside monitor. The transceiver **285** can be used to offload stored ECG monitoring data and other physiology data and information, such as by wirelessly transmitting the samples of ECG signals stored in the flash memory **82** to the download station and any other physiological data to the download station **145**, and for device

firmware reprogramming. In a further embodiment, the flash memory **82** can be accessed through an inductive coupling (not shown), with the accessed samples of the ECG signals being provided to the download station **145**.

**[0101]** The microcontroller **281** includes functionality that enables the acquisition of samples of analog ECG signals, which are converted into a digital representation. In one mode, the microcontroller **281** implements a loop recorder feature that will acquire, sample, digitize, signal process, and store digitized ECG data into available storage locations in the flash memory **82** until all memory storage locations are filled, after which existing stored digitized ECG data will either be overwritten through a sliding window protocol, albeit at the cost of potentially losing the stored data that was overwritten, if not previously downloaded, or transmitted wirelessly to an external receiver, such as the download station **145**, to unburden the flash memory. In another mode, the stored digitized ECG data can be maintained permanently until downloaded or erased to restore memory capacity. Data download or erasure can also occur before all storage locations are filled, which would free up memory space sooner, albeit at the cost of possibly interrupting monitoring while downloading or erasure is performed. Still other modes of data storage and capacity recovery are possible.

**[0102]** The circuitry **280** of the ICM **212** can include functionality to programmatically select pairings of sensing electrodes when the ICM **212** is furnished with three or more electrodes. In a further embodiment, multiple sensing electrodes could be provided on the ICM **212** to provide a physician the option of fine-tuning the sensing dipole (or tripole or multipole) in situ by parking active electrodes and designating any remaining electrodes inert. The pairing selection can be made remotely through an inductive coupling or by the transceiver **285** via, for instance, a paired mobile device. Thus, the sensing electrode configuration, including number of electrodes, electrode-to-electrode spacing, and electrode size, shape, surface area, and placement, can be modified at any time during the implantation of the ICM **212**.

**[0103]** In a further embodiment, the circuitry **280** of the ICM **212** can include an actigraphy sensor **84** implemented as a 3-axis accelerometer. The accelerometer may be configured to generate interrupt signals to the microcontroller **281** by independent initial wake up and free fall events, as well as by device position. In addition, the actigraphy provided by the accelerometer can be used during post-monitoring analysis to correct the orientation of the ICM **212** if, for instance, the ICM **212** has been inadvertently implanted upside down, that is, with the ICM's housing oriented caudally, as well as for other event occurrence analyses.

**[0104]** In a still further embodiment, the circuitry **280** of the ICM **212** can include one or more physiology sensors. For instance, a physiology sensor can be provided as part of the circuitry **280** of the ICM **212**, or can be provided on the electrode assembly **14** with communication with the microcontroller **281** provided through a circuit trace. The physiology sensor can include an SpO<sub>2</sub> sensor, blood pressure sensor, temperature sensor, respiratory rate sensor, glucose sensor, airflow sensor, volumetric pressure sensing, or other types of sensor or telemetric input sources.

**[0105]** In a yet further embodiment, firmware with programming instructions, including machine learning and

other forms of artificial intelligence-originated instructions, can be downloaded into the microcontroller's internal flash memory. The firmware can include heuristics to signal patient and physician with alerts over health conditions or arrhythmias of selected medical concern, such as where a heart pattern particular to the patient is identified and the ICM **212** is thereby reprogrammed to watch for a reoccurrence of that pattern, after which an alert will be generated and sent to the physician (or other caregiver) through the transceiver **285** via, for instance, a paired mobile device. Similarly, the firmware can include heuristics that can be downloaded to the ICM **212** to actively identify or narrow down a pattern (or even the underlying cause) of sporadic cardiac conditions, for instance, atrial tachycardia (AT), atrial fibrillation (AF), atrial flutter (AFL), AV node reciprocating tachycardia, ventricular tachycardia (VT), sinus bradycardia, asystole, complete heart block, and other cardiac arrhythmias, again, after which an alert will be generated and sent to the physician (or other caregiver) through the transceiver **285**. For instance, an alert that includes a compressed ECG digitized sample can also be wirelessly transmitted by the ICM **212** upon the triggering of a preset condition, such as an abnormally low heart rate in excess of 170 beats per minute (bpm), an abnormally low heart rate falling below 30 bpm, or AF detected by onboard analysis of RR interval variability by the microcontroller **61**. Finally, a similar methodology of creating firmware programming tailored to the monitoring and medical diagnostic needs of a specific patient (or patient group or general population) can be used for other conditions or symptoms, such as syncope, palpitations, dizziness and giddiness, unspecified convulsions, abnormal ECG, transient cerebral ischemic attacks and related syndromes, cerebral infarction, occlusion and stenosis of pre-cerebral and cerebral arteries not resulting in cerebral infarction personal history of transient ischemic attack, and cerebral infarction without residual deficits, to trigger an alert and involve the physician or initiate automated analysis and follow up back at the patient's clinic. Finally, in a still further embodiment, the circuitry **280** of the ICM **212** can accommodate patient-interfaceable components, including an external tactile feedback device (not shown) that wirelessly interfaces to the ICM **212** through the transceiver **285**. A patient **210** can press the external tactile feedback device to mark events, such as a syncope episode, or to perform other functions. The circuitry **280** can also accommodate triggering an external buzzer **267**, such as a speaker, magnetic resonator or piezoelectric buzzer, implemented as part of the external tactile feedback device or as a separate wirelessly-interfaceable component. The buzzer **67** can be used by the microcontroller **281** to indirectly output feedback to a patient **210**, such as a low battery or other error condition or warning. Still other components, provided as either part of the circuitry **280** of the ICM **212** or as external wirelessly-interfaceable devices, are possible.

**[0106]** In a further embodiment, the ECG front end circuit **283** of the ICM **212** measures raw subcutaneous electrical signals using a driven reference signal, such as described in U.S. Pat. Nos. 9,700,227, 9,7217,433, and 9,615,763, cited supra. The driven reference signal effectively reduces common mode noise, power supply noise and system noise, which is critical to preserving the characteristics of low amplitude cardiac action potentials, especially the P wave signals originating from the atria.

[0107] The ECG front end circuit 283 is organized into a passive input filter stage, a unity gain voltage follower stage, a passive high pass filtering stage, a voltage amplification and active filtering stage, and an anti-aliasing passive filter stage, plus a reference generator. The passive input filter stage passively shifts the frequency response poles downward to counter the high electrode impedance from the patient on the signal lead and reference lead, which reduces high frequency noise. The unity gain voltage follower stage allows the circuit to accommodate a very high input impedance, so as not to disrupt the subcutaneous potentials or the filtering effect of the previous stage. The passive high pass filtering stage includes a high pass filter that removes baseline wander and any offset generated from the previous stage. As necessary, the voltage amplification and active filtering stage amplifies or de-amplifies (or allows to pass-through) the voltage of the input signal, while applying a low pass filter. The anti-aliasing passive filter stage provides an anti-aliasing low pass filter. The reference generator drives a driven reference signal containing power supply noise and system noise to the reference lead and is connected directly to the patient, thereby avoiding the thermal noise of the protection resistor that is included as part of the protection circuit.

[0108] While the invention has been particularly shown and described as referenced to the embodiments thereof, those skilled in the art will understand that the foregoing and other changes in form and detail may be made therein without departing from the spirit and scope.

What is claimed is:

1. A system for facilitating a cardiac rhythm disorder diagnosis based on subcutaneous cardiac monitoring data, comprising:

- a subcutaneous insertable cardiac monitor, comprising:
  - an implantable housing comprised of a biocompatible material that is suitable for implantation within a living body;
  - at least one pair of electrocardiographic (ECG) sensing electrodes provided on a ventral surface and on opposite ends of the implantable housing operatively placed to facilitate sensing in closest proximity to the low amplitude, low frequency content cardiac action potentials that are generated during atrial activation; and
  - electronic circuitry provided within the housing assembly comprising a low power microcontroller operable to execute under modular micro program control as specified in firmware, an ECG front end circuit interfaced to the microcontroller and configured to capture the cardiac action potentials sensed by the pair of ECG sensing electrodes which are output as ECG signals, and non-volatile memory electrically interfaced with the microcontroller and operable to continuously store samples of the ECG signals; and
- a download station adapted to retrieve the stored samples of the ECG signals from the subcutaneous insertable cardiac monitor as ECG data;
- a processor and memory within which code for execution by the processor is stored, further comprising:
  - an identification module to identify a set of R-wave peaks within the ECG data;
  - a construction module to construct an R-R interval plot, comprising:

- a determination submodule to determine a difference between recording times of successive pairs of the R-wave peaks in the set and to determine a heart rate associated with each difference; and
  - a plot submodule to plot the pairs of the R-wave peaks and associated heart rate as the R-R interval plot;
  - a display to facilitate diagnosis of a cardiac disorder of the patient based on patterns of the plotted pairs of the R-wave peaks and the associated heart rates in the R-R interval plot.
- 2. A system in accordance with claim 1, the processor further comprising:
  - a diagnostic module configured to form a diagnosis based on heart rate variability patterns in the R-R interval plot.
- 3. A system in accordance with claim 2, further comprising:
  - the diagnostic module further configured to detect atrial fibrillation by identifying a Gaussian-type distribution of heart rate variability in the duration R-R interval plot.
- 4. A system in accordance with claim 1, wherein the processor is configured to form:
  - a background information plot with the R-R interval plot comprising one or more of activity amount, activity intensity, posture, syncope impulse detection, respiratory rate, blood pressure, oxygen saturation (SpO<sub>2</sub>), blood carbon dioxide level (pCO<sub>2</sub>), glucose, lung wetness, and temperature; and
  - background information layered to or keyed with the R-R interval plot comprising one or more of activity amount, activity intensity, posture, syncope impulse detection, respiratory rate, blood pressure, oxygen saturation (SpO<sub>2</sub>), blood carbon dioxide level (pCO<sub>2</sub>), glucose, lung wetness, and temperature.
- 5. A system in accordance with claim 1, wherein the display displays the R-R interval plot with one or more views of at least a portion of the ECG data as contextual data for the R-R interval plot.
- 6. A system in accordance with claim 1, wherein each ECG data view comprises one of a near field view providing ECG data corresponding to the data for the R-wave peak pairs at a center of the R-R interval plot and an intermediate field view providing presentation of additional ECG data than the near field view.
- 7. A system in accordance with claim 1, wherein the set of R-wave peaks is collected over a period of at least 40 minutes.
- 8. A system in accordance with claim 1, further comprising:
  - a selection module to select the set of R-wave peaks by identifying a potential cardiac event within the ECG data and obtaining a portion of the ECG data corresponding to a time during, prior to, and after the potential cardiac event as the set of R-wave peaks.
- 9. A system in accordance with claim 8, further comprising:
  - a representation module to represent the potential cardiac event in the R-R interval plot via a temporal point of reference.

10. A system in accordance with claim 9, wherein the display displays the temporal point of reference in the R-R interval plot in one of a center and another location.

11. A method for facilitating a cardiac rhythm disorder diagnosis based on subcutaneous cardiac monitoring data, comprising:

recording cardiac action potentials of a patient over a set time period using a subcutaneous insertable cardiac monitor, comprising an implantable housing comprised of a biocompatible material that is suitable for implantation within a living body; at least one pair of electrocardiographic (ECG) sensing electrodes provided on a ventral surface and on opposite ends of the implantable housing operatively placed to facilitate sensing in closest proximity to the low amplitude, low frequency content cardiac action potentials that are generated during atrial activation; and electronic circuitry provided within the housing assembly comprising a low power microcontroller operable to execute under modular micro program control as specified in firmware, an ECG front end circuit interfaced to the microcontroller and configured to capture the cardiac action potentials sensed by the pair of ECG sensing electrodes which are output as ECG signals, and non-volatile memory electrically interfaced with the microcontroller and operable to continuously store samples of the ECG signals; and

retrieving the stored samples of the ECG signals as ECG data;

identifying a set of R-wave peaks within the ECG data; constructing an R-R interval plot, comprising:

determining a difference between recording times of successive pairs of the R-wave peaks in the set; determining a heart rate associated with each difference; and

plotting the pairs of the R-wave peaks and associated heart rate as the R-R interval plot;

facilitating diagnosis of a cardiac disorder of the patient based on patterns of the plotted pairs of the R-wave peaks and the associated heart rates in the R-R interval plot.

12. A method in accordance with claim 11, further comprising:

forming a diagnosis based on heart rate variability patterns in the R-R interval plot.

13. A method in accordance with claim 12, further comprising:

detecting atrial fibrillation by identifying a Gaussian-type distribution of heart rate variability in the duration R-R interval plot.

14. A method in accordance with claim 11, further comprising at least one of:

including a background information plot with the R-R interval plot comprising one or more of activity amount, activity intensity, posture, syncope impulse detection, respiratory rate, blood pressure, oxygen saturation (SpO<sub>2</sub>), blood carbon dioxide level (pCO<sub>2</sub>), glucose, lung wetness, and temperature; and

layering or keying background information with the R-R interval plot comprising one or more of activity amount, activity intensity, posture, syncope impulse detection, respiratory rate, blood pressure, oxygen saturation (SpO<sub>2</sub>), blood carbon dioxide level (pCO<sub>2</sub>), glucose, lung wetness, and temperature.

15. A method in accordance with claim 11, further comprising:

displaying the R-R interval plot with one or more views of at least a portion of the ECG data as contextual data for the R-R interval plot.

16. A method in accordance with claim 11, wherein each ECG data view comprises one of a near field view providing ECG data corresponding to the data for the R-wave peak pairs at a center of the R-R interval plot and an intermediate field view providing presentation of additional ECG data than the near field view.

17. A method in accordance with claim 11, wherein the set of R-wave peaks is collected over a period of at least 40 minutes.

18. A method in accordance with claim 11, further comprising:

selecting the set of R-wave peaks, comprising:

identifying a potential cardiac event within the ECG data; and

obtaining a portion of the ECG data corresponding to a time during, prior to, and after the potential cardiac event as the set of R-wave peaks.

19. A method in accordance with claim 18, further comprising:

representing the potential cardiac event in the R-R interval plot via a temporal point of reference.

20. A method in accordance with claim 19, further comprising:

displaying the temporal point of reference in the R-R interval plot in one of a center and another location.

\* \* \* \* \*

|                |   |         |            |
|----------------|---|---------|------------|
| 专利名称(译)        | 用于基于皮下心脏监测数据促进心律失常诊断的系统和方法  |         |            |
| 公开(公告)号        | <a href="#">US20190069794A1</a>   | 公开(公告)日 | 2019-03-07 |
| 申请号            | US16/178463   | 申请日     | 2018-11-01 |
| [标]申请(专利权)人(译) | BARDY诊断   |         |            |
| 申请(专利权)人(译)    | BARDY诊断, INC.   |         |            |
| 当前申请(专利权)人(译)  | BARDY诊断, INC.   |         |            |
| [标]发明人         | BARDY GUST H<br>DREISBACH EZRA M  |         |            |
| 发明人            | BARDY, GUST H.<br>DREISBACH, EZRA M.  |         |            |
| IPC分类号         | A61B5/0456 A61B5/00 A61B5/024 A61B5/0245 A61B5/0464 A61B5/046 A61B5/0452 A61B5/044<br>A61B5/0432 A61B5/0408 A61B5/04 A61B5/0205 A61B5/0468  |         |            |
| CPC分类号         | A61B5/044 A61B5/742 A61B5/0432 A61B5/04017 A61B5/7203 A61B5/6823 A61B5/04085 A61B5/<br>/04525 A61B5/046 A61B5/04087 A61B5/0468 A61B5/0464 A61B5/0245 A61B5/02405 A61B5/0205<br>A61B5/0456 A61B5/02055 A61B5/04011 A61B5/0422 A61B5/686 A61B2560/0468 A61B2562/162 |         |            |
| 优先权            | 62/132497 2015-03-12 US<br>61/882403 2013-09-25 US  |         |            |
| 其他公开文献         | US10433751  |         |            |
| 外部链接           | <a href="#">Espacenet</a> <a href="#">USPTO</a>   |         |            |

摘要(译)

提供了一种借助于数字计算机基于皮下心脏监测数据来促进心律失常诊断的系统和方法。使用皮下可插入心脏监测器在设定时间段内将患者的皮肤动作电位记录为心电图 ( ECG ) 数据。在 ECG 数据内识别一组 R 波峰，并构建 R-R 区间图。确定该组中连续的 R 波峰对的记录时间之间的差异。还确定与每个差异相关联的心率。将 R 波峰对和相关心率对绘制为 R-R 间隔图。基于绘制的 R 波峰对的模式和 R-R 间隔图中的相关心率，促进心脏病的诊断。

