



(19) **United States**

(12) **Patent Application Publication**
Bardy et al.

(10) **Pub. No.: US 2018/0344191 A1**

(43) **Pub. Date: Dec. 6, 2018**

(54) **SYSTEM AND METHOD FOR FACILITATING A CARDIAC RHYTHM DISORDER DIAGNOSIS WITH THE AID OF A DIGITAL COMPUTER**

A61B 5/024 (2006.01)
A61B 5/0245 (2006.01)
A61B 5/0464 (2006.01)
A61B 5/046 (2006.01)
A61B 5/0452 (2006.01)
A61B 5/044 (2006.01)
A61B 5/0432 (2006.01)
A61B 5/0408 (2006.01)
A61B 5/04 (2006.01)
A61B 5/0468 (2006.01)
A61B 5/0205 (2006.01)

(71) Applicant: **Bardy Diagnostics, Inc.**, Seattle, WA (US)

(72) Inventors: **Gust H. Bardy**, Carnation, WA (US);
Ezra M. Dreisbach, Vashon, WA (US)

(21) Appl. No.: **16/102,608**

(52) **U.S. Cl.**

(22) Filed: **Aug. 13, 2018**

CPC *A61B 5/0456* (2013.01); *A61B 5/742* (2013.01); *A61B 5/02405* (2013.01); *A61B 5/0245* (2013.01); *A61B 5/6823* (2013.01); *A61B 5/0464* (2013.01); *A61B 5/046* (2013.01); *A61B 5/04525* (2013.01); *A61B 5/044* (2013.01); *A61B 5/0432* (2013.01); *A61B 5/04087* (2013.01); *A61B 5/04085* (2013.01); *A61B 5/04017* (2013.01); *A61B 5/0468* (2013.01); *A61B 5/0205* (2013.01); *A61B 5/7203* (2013.01)

Related U.S. Application Data

(63) Continuation of application No. 15/231,752, filed on Aug. 8, 2016, now Pat. No. 10,045,709, which is a continuation of application No. 15/066,883, filed on Mar. 10, 2016, now Pat. No. 9,408,551, which is a continuation-in-part of application No. 14/997,416, filed on Jan. 15, 2016, now Pat. No. 9,345,414, which is a continuation-in-part of application No. 14/614,265, filed on Feb. 4, 2015, now Pat. No. 9,408,545, which is a continuation-in-part of application No. 14/488,230, filed on Sep. 16, 2014, now Pat. No. 9,700,227, which is a continuation-in-part of application No. 14/080,725, filed on Nov. 14, 2013, now Pat. No. 9,730,593.

(60) Provisional application No. 62/132,497, filed on Mar. 12, 2015, provisional application No. 61/882,403, filed on Sep. 25, 2013.

Publication Classification

(51) **Int. Cl.**
A61B 5/0456 (2006.01)
A61B 5/00 (2006.01)

(57)

ABSTRACT

A system and method for facilitating a cardiac rhythm disorder diagnosis with the aid of a digital computer is provided. A plurality of R-wave peaks are identified in a set of ECG data and a difference between recording times of successive pairs of the R-wave peaks are calculated as R-R intervals. A heart rate associated with each time difference is determined. An R-R interval plot of the ECG data is formed. The R-R intervals are plotted along an x-axis of the R-R interval plot and the heart rates associated with the R-R intervals are plotted along a y-axis of the R-R interval plot. A diagnostic composite plot is generated, including the R-R interval plot, a near field view of a portion of the ECG data, and an intermediate field view of a different portion of the ECG data for diagnosis of a cardiac event.

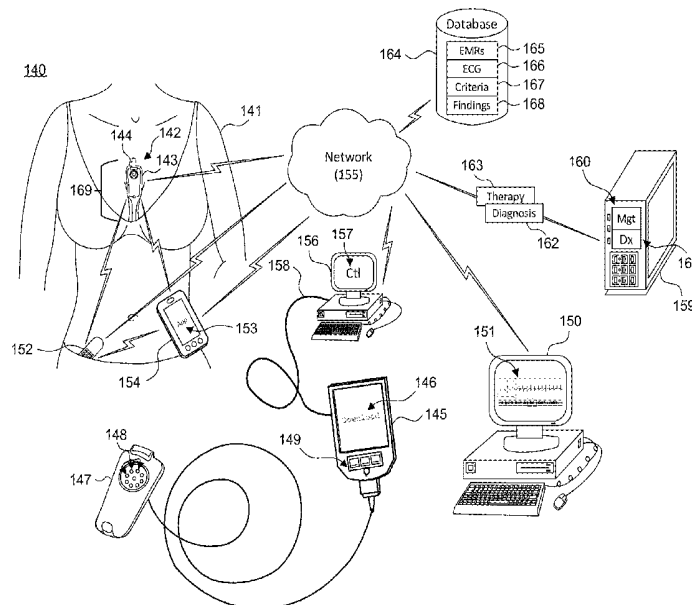
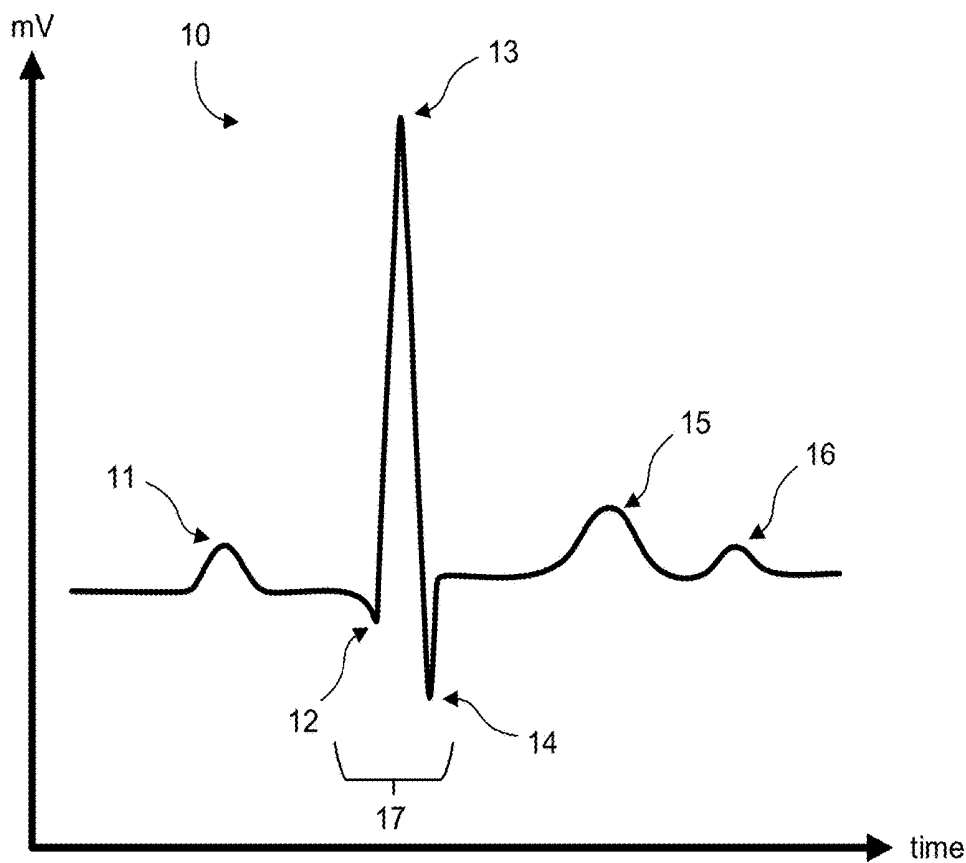


Fig. 1.



**Fig. 2.
(Prior Art)**

18

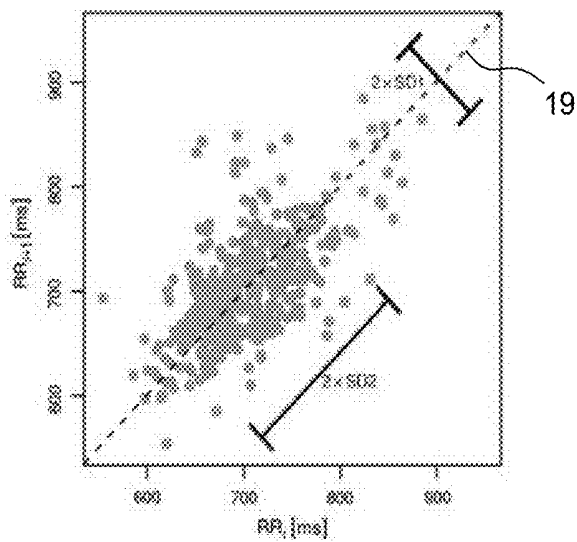


Fig. 3.

20

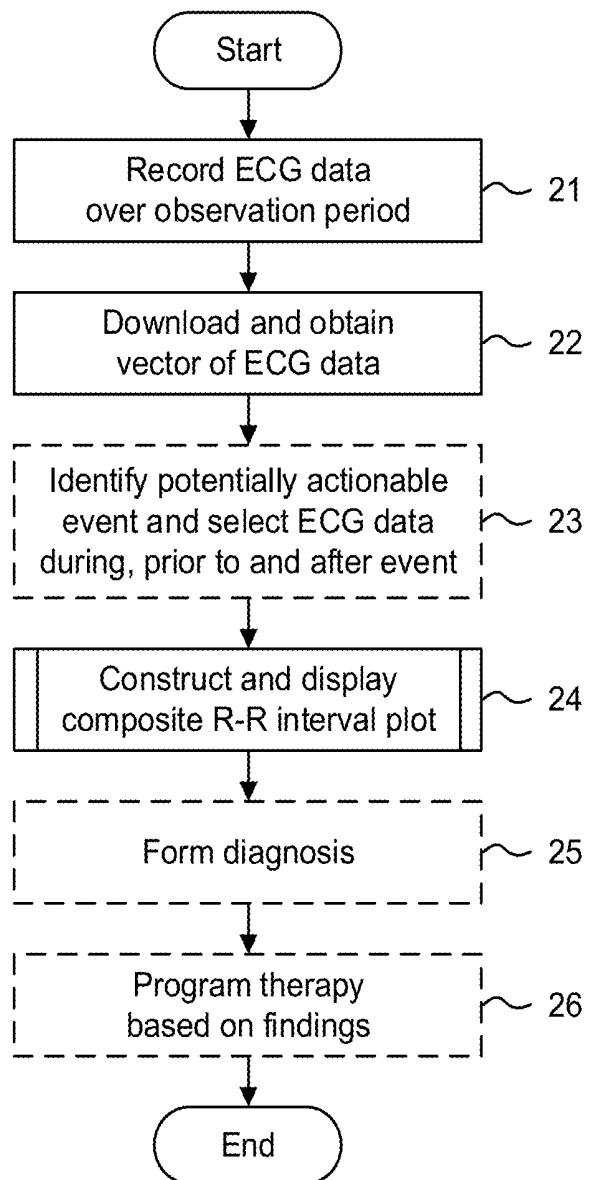


Fig. 4.

30

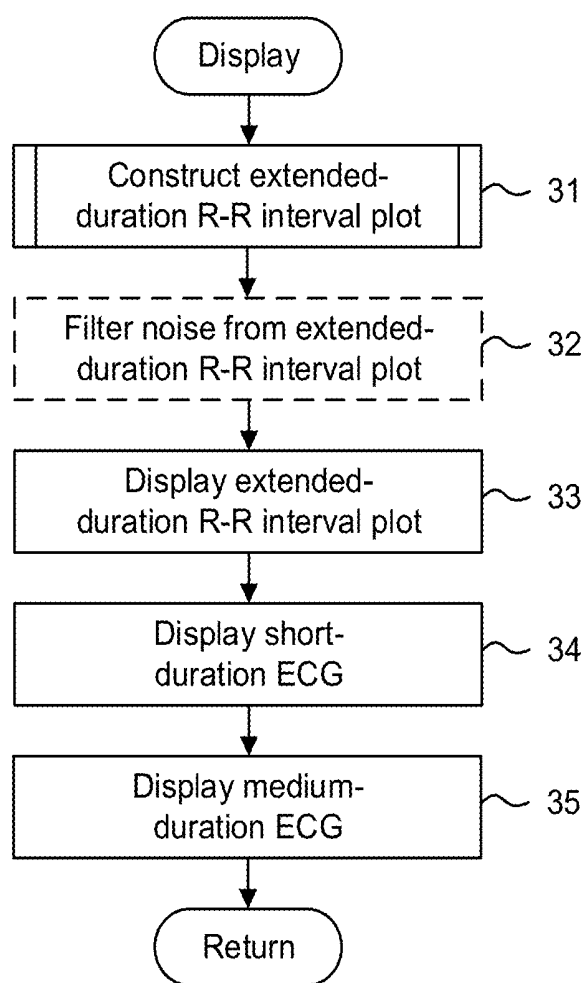


Fig. 5.

40

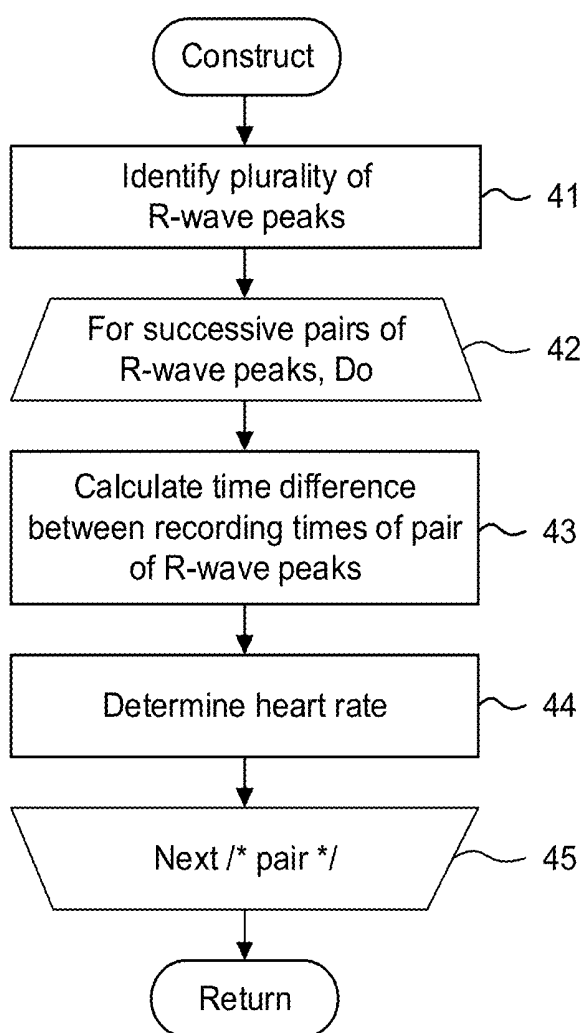


Fig. 6.

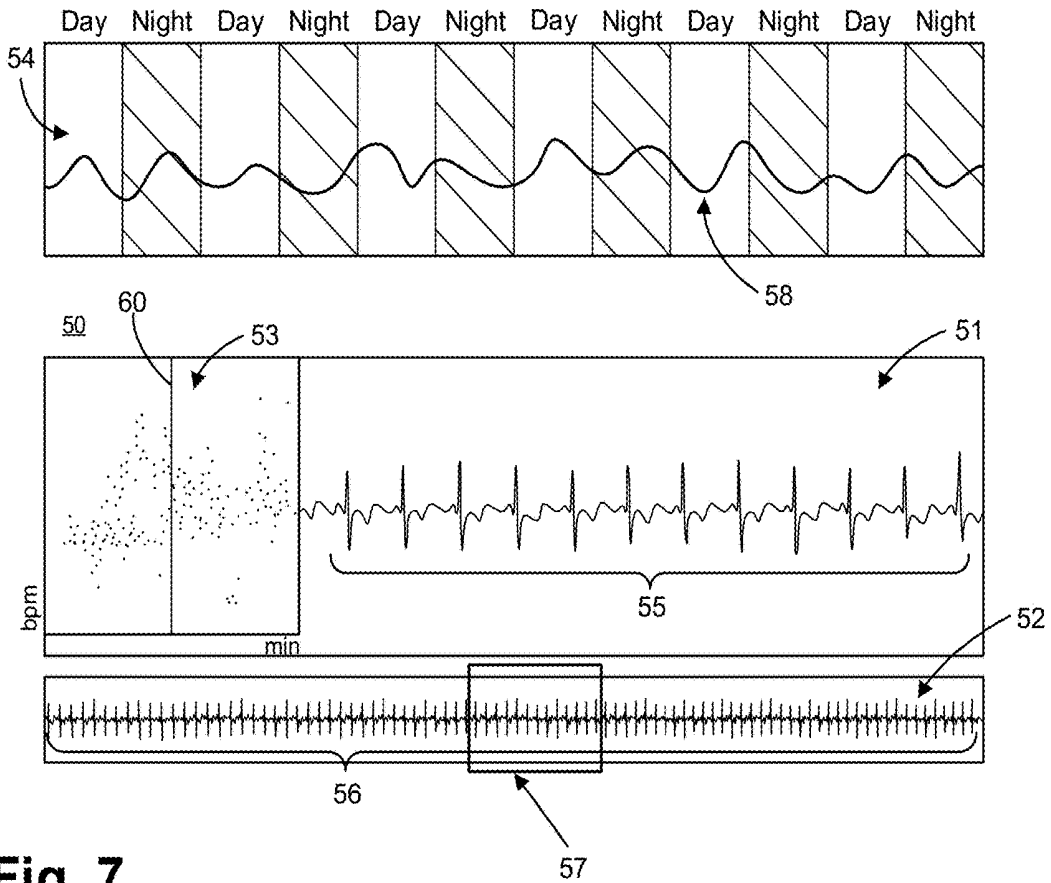


Fig. 7.

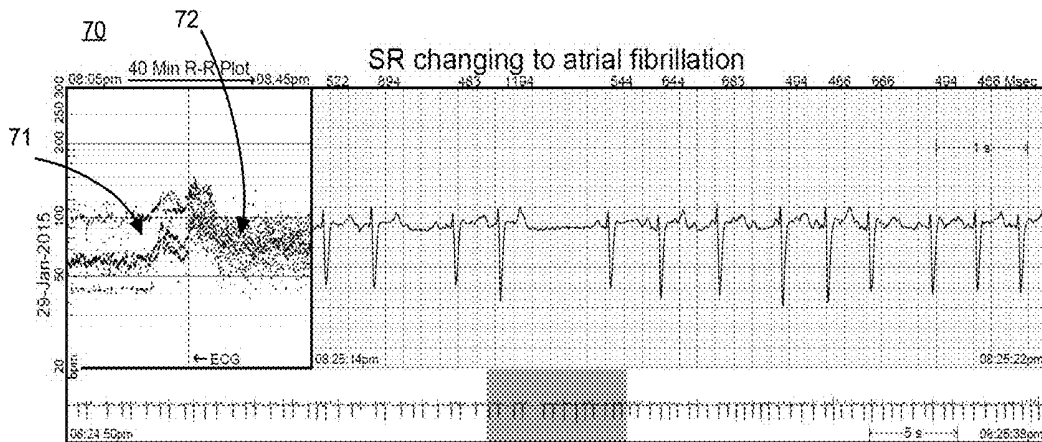


Fig. 8.

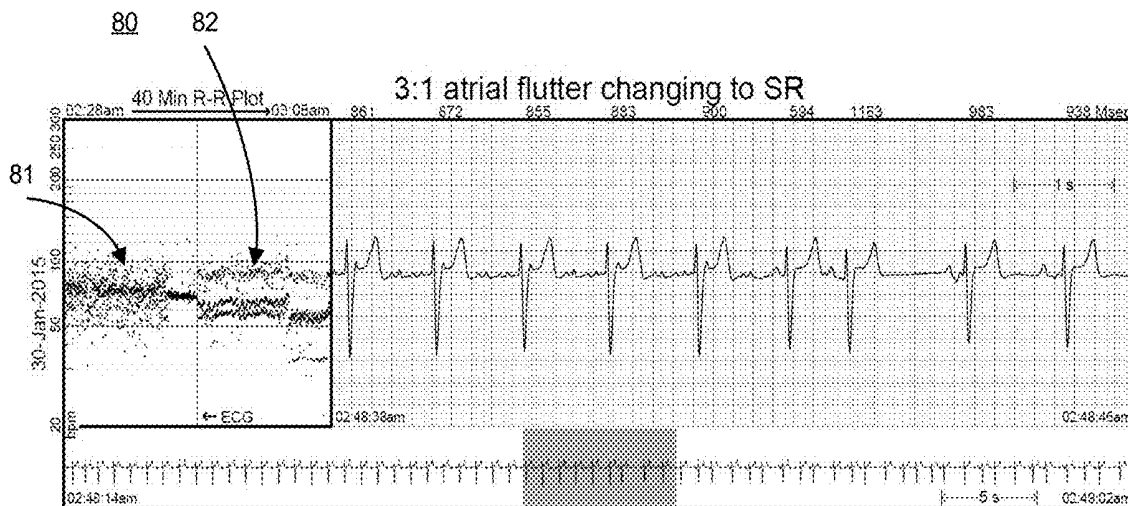


Fig. 9.

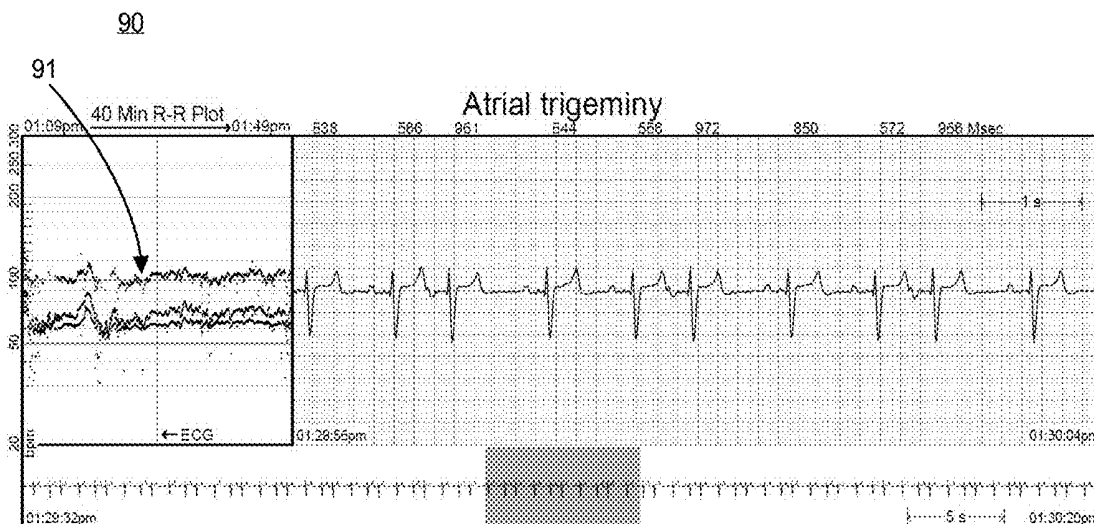


Fig. 10.

100

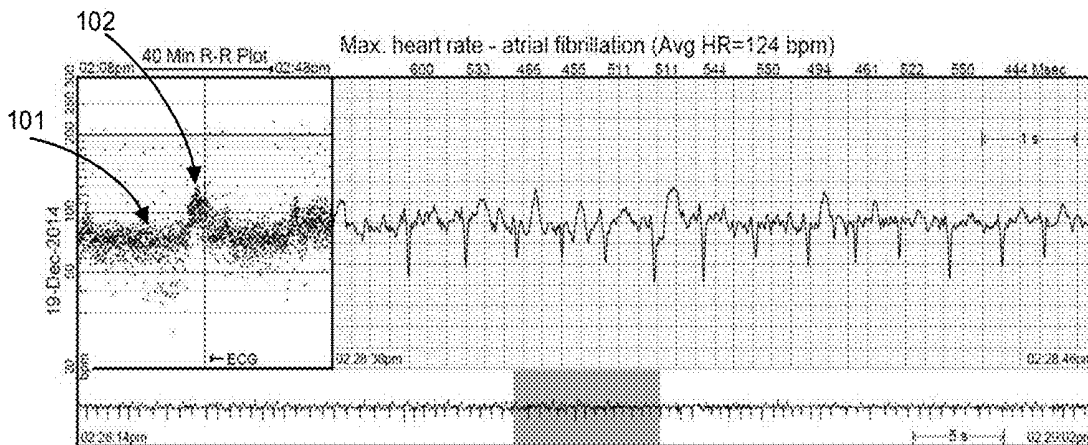


Fig. 11.

110

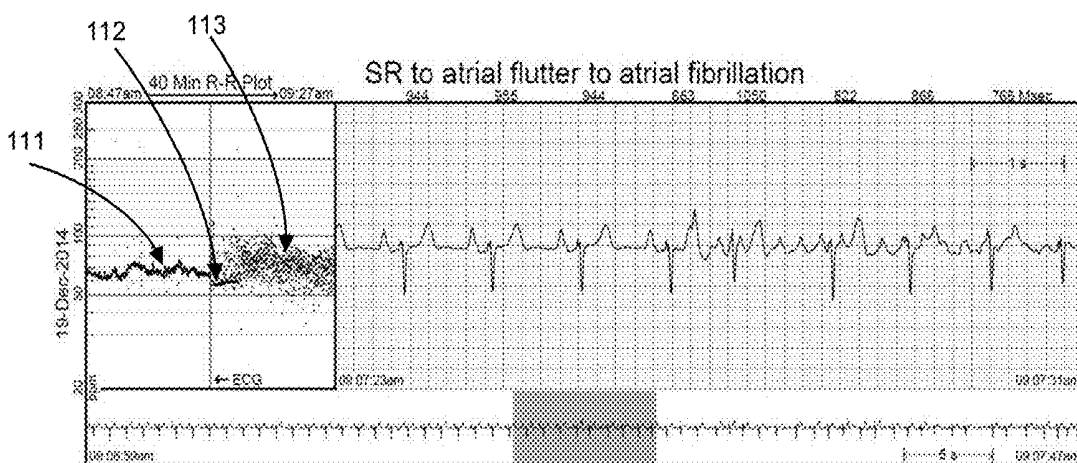


Fig. 12.

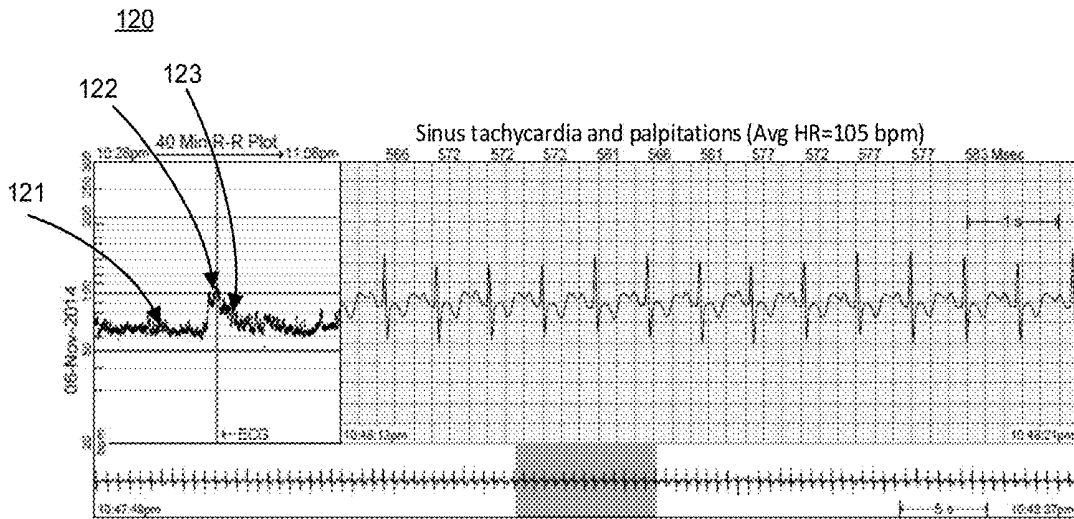
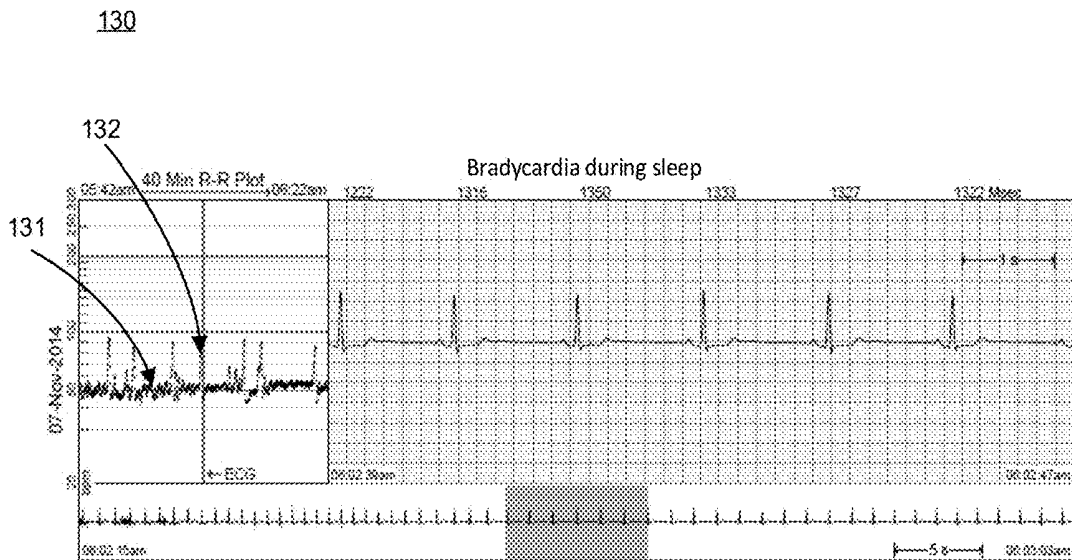


Fig. 13.



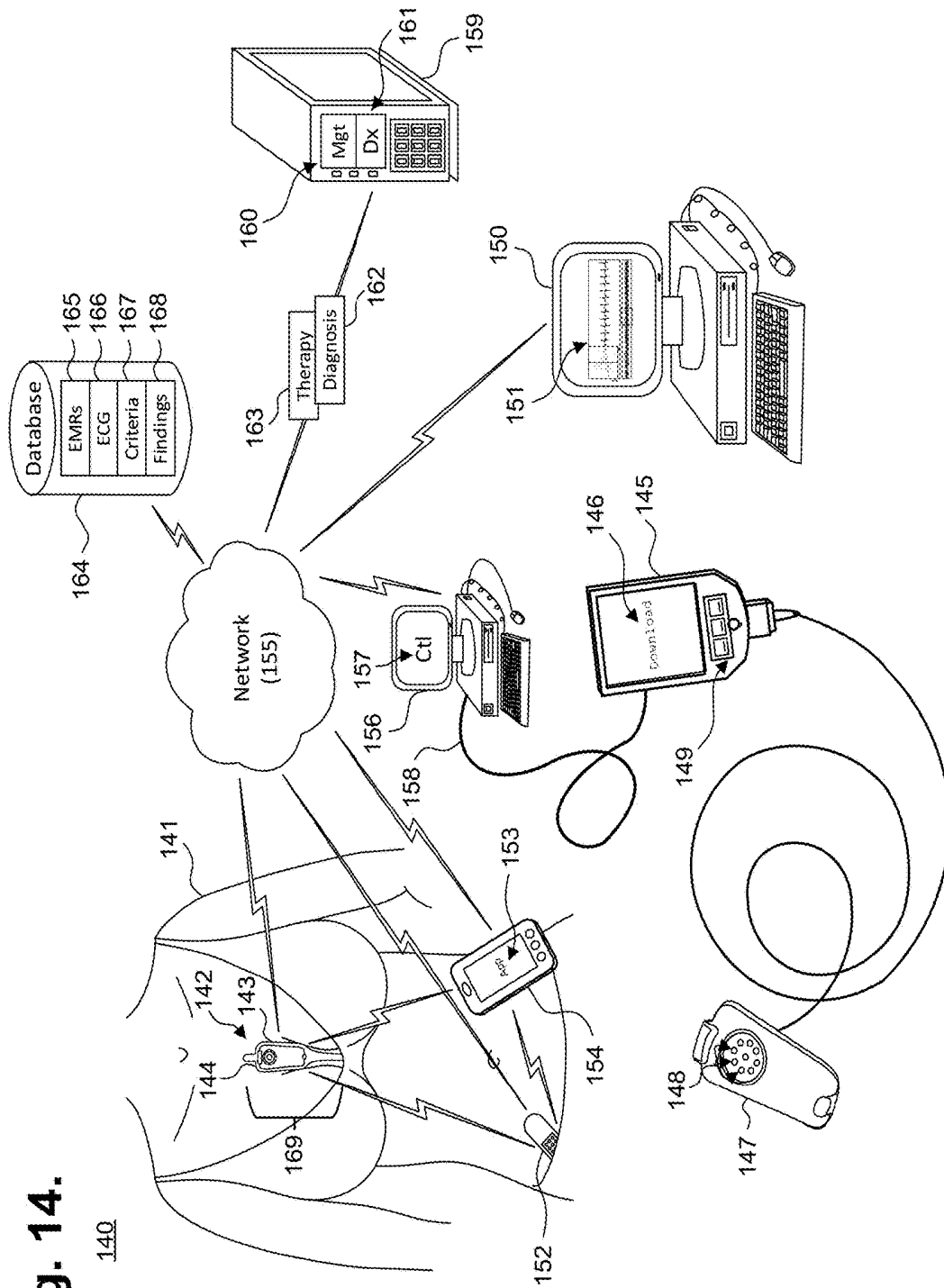


Fig. 14.

**SYSTEM AND METHOD FOR
FACILITATING A CARDIAC RHYTHM
DISORDER DIAGNOSIS WITH THE AID OF
A DIGITAL COMPUTER**

CROSS-REFERENCE TO RELATED
APPLICATION

[0001] This non-provisional patent application is a continuation of U.S. patent application Ser. No. 15/231,752, filed Aug. 8, 2016, pending; which is a continuation of U.S. Pat. No. 9,408,551, issued Aug. 9, 2016; which is a continuation-in-part of U.S. Pat. No. 9,345,414, issued May 24, 2016; which is a continuation-in-part of U.S. Pat. No. 9,408,545, issued Aug. 9, 2016; which is a continuation-in-part of U.S. Pat. No. 9,700,227, issued Jul. 11, 2017; which is a continuation-in-part of U.S. Pat. No. 9,730,593, issued Aug. 15, 2017; and further claims priority under 35 U.S.C. § 119(e) to U.S. Provisional Patent Application, Ser. No. 62/132,497, filed Mar. 12, 2015, and U.S. Provisional Patent Application, Ser. No. 61/882,403, filed Sep. 25, 2013, the disclosures of which are incorporated by reference.

FIELD

[0002] This application relates in general to electrocardiographic monitoring and, in particular, to a method for facilitating diagnosis of cardiac rhythm disorders with the aid of a digital computer.

BACKGROUND

[0003] An electrocardiogram (ECG) allows physicians to diagnose cardiac function by visually tracing the cutaneous electrical signals (action potentials) that are generated by the propagation of the transmembrane ionic currents that trigger the depolarization of cardiac fibers. An ECG trace contains alphabetically-labeled waveform deflections that represent distinct features within the cyclic cardiac activation sequence. The P-wave represents atrial depolarization, which causes atrial contraction. The QRS-complex represents ventricular depolarization. The T-wave represents ventricular repolarization.

[0004] The R-wave is often used as an abbreviation for the QRS-complex. An R-R interval spans the period between successive R-waves and, in a normal heart, is 600 milliseconds (ms) to one second long, which respectively correspond to 100 to 60 beats per minute (bpm). The R-wave is the largest waveform generated during normal conduction and represents the cardiac electrical stimuli passing through the ventricular walls. R-R intervals provide information that allows a physician to understand at a glance the context of cardiac rhythms both before and after a suspected rhythm abnormality and can be of confirmational and collaborative value in cardiac arrhythmia diagnosis and treatment.

[0005] Conventionally, the potential of R-R interval context has not been fully realized, partly due to the difficulty of presentation in a concise and effective manner to physicians. For instance, routine ECGs are typically displayed at an effective paper speed of 25 millimeters (mm) per second. A lower speed is not recommended because ECG graph resolution degrades at lower speeds and diagnostically-relevant features may be lost. Conversely, a half-hour ECG recording, progressing at 25 mm/s, results in 45 meters of ECG waveforms that, in printed form, is cumbersome and, in electronic display form, will require significant back and

forth toggling between pages of waveforms, as well as presenting voluminous data transfer and data storage concerns. As a result, ECGs are less than ideal tools for diagnosing cardiac arrhythmia patterns that only become apparent over an extended time frame, such as 30 minutes or longer.

[0006] R-R intervals have also been visualized in Poincaré plots, which graph $RR(n)$ on the x-axis and $RR(n+1)$ on the y-axis. However, a Poincaré plot fails to preserve the correlation between an R-R interval and the R-R interval's time of occurrence and the linearity of time and associated contextual information, before and after a specific cardiac rhythm, are lost. In addition, significant changes in heart rate, particularly spikes in heart rate, such as due to sinus rhythm transitions to atrial flutter or atrial fibrillation, may be masked or distorted in a Poincaré plot if the change occurs over non-successive heartbeats, rather than over two adjacent heartbeats, which undermines reliance on Poincaré plots as dependable cardiac arrhythmia diagnostic tools. Further, Poincaré plots cannot provide context and immediate temporal reference to the actual ECG, regardless of paper speed. Events both prior to and after a specific ECG rhythm can provide key clinical information disclosed in the R-R interval plot that may change patient management above and beyond the specific rhythm being diagnosed.

[0007] Therefore, a need remains for presenting R-R interval data to physicians to reveal temporally-related patterns as an aid to rhythm abnormality diagnosis.

SUMMARY

[0008] R-R interval data is presented to physicians in a format that includes views of relevant near field and far field ECG data, which together provide contextual information that improves diagnostic accuracy. The near field (or short duration) ECG data view provides a "pinpoint" classical view of an ECG at traditional recording speed in a manner that is known to and widely embraced by physicians. The near field ECG data is coupled to a far field (or medium duration) ECG data view that provides an "intermediate" lower resolution, pre- and post-event contextual view.

[0009] Both near field and far field ECG data views are temporally keyed to an extended duration R-R interval data view. In one embodiment, the R-R interval data view is scaled non-linearly to maximize the visual differentiation for frequently-occurring heart rate ranges, such that a single glance allows the physician to make a diagnosis. All three views are presented simultaneously, thereby allowing an interpreting physician to diagnose rhythm and the pre- and post-contextual events leading up to a cardiac rhythm of interest.

[0010] The durations of the classical "pinpoint" view, the pre- and post-event "intermediate" view, and the R-R interval plot are flexible and adjustable. In one embodiment, a temporal point of reference is identified in the R-R interval plot and the ECG data that is temporally associated with the point of reference is displayed in the near field and far field ECG data views. In a further embodiment, diagnostically relevant cardiac events can be identified as the temporal point of reference. For clarity, the temporal point of reference will generally be placed in the center of the R-R interval data to allow pre- and post-event heart rhythm and ECG waveform data to present in the correct context. Thus, the pinpoint "snapshot" and intermediate views of ECG data with the extended term R-R interval data allow a physician

to comparatively view heart rate context and patterns of behavior prior to and after a clinically meaningful arrhythmia, patient concern or other indicia, thereby enhancing diagnostic specificity of cardiac rhythm disorders and providing physiological context to improve diagnostic ability.

[0011] One embodiment provides a system and method for facilitating a cardiac rhythm disorder diagnosis with the aid of a digital computer. A plurality of R-wave peaks are identified in a set of ECG data and a difference between recording times of successive pairs of the R-wave peaks are calculated as R-R intervals. A heart rate associated with each time difference is determined. An R-R interval plot of the ECG data is formed. The R-R intervals are plotted along an x-axis of the R-R interval plot and the heart rates associated with the R-R intervals are plotted along a y-axis of the R-R interval plot. A diagnostic composite plot is generated, including the R-R interval plot, a near field view of a portion of the ECG data, and an intermediate field view of a different portion of the ECG data for diagnosis of a cardiac event.

[0012] The foregoing aspects enhance the presentation of diagnostically relevant R-R interval data, reduce time and effort needed to gather relevant information by a clinician and provide the clinician with a concise and effective diagnostic tool, which is critical to accurate arrhythmia and cardiac rhythm disorder diagnoses.

[0013] Custom software packages have been used to identify diagnostically relevant cardiac events from the electrocardiography data, but usually require a cardiologist's diagnosis and verification. In contrast, when presented with a machine-identified event, the foregoing approach aids the cardiologist's diagnostic job by facilitating presentation of ECG-based background information prior to and after the identified event.

[0014] Still other embodiments will become readily apparent to those skilled in the art from the following detailed description, wherein are described embodiments by way of illustrating the best mode contemplated. As will be realized, other and different embodiments are possible and the embodiments' several details are capable of modifications in various obvious respects, including time and clustering of events, all without departing from their spirit and the scope. Accordingly, the drawings and detailed description are to be regarded as illustrative in nature and not as restrictive.

BRIEF DESCRIPTION OF THE DRAWINGS

[0015] FIG. 1 is a graph showing, by way of example, a single ECG waveform.

[0016] FIG. 2 is a graph showing, by way of example, a prior art Poincaré R-R interval plot.

[0017] FIG. 3 is a flow diagram showing a method for facilitating diagnosis of cardiac rhythm disorders with the aid of a digital computer in accordance with one embodiment.

[0018] FIG. 4 is a flow diagram showing a routine for constructing and displaying a diagnostic composite plot for use in the method of FIG. 3.

[0019] FIG. 5 is a flow diagram showing a routine for constructing an extended-duration R-R interval plot for use in the routine of FIG. 4.

[0020] FIG. 6 is a diagram showing, by way of example, a diagnostic composite plot generated by the method of FIG. 3.

[0021] FIG. 7 is a diagram showing, by way of example, a diagnostic composite plot for facilitating the diagnosis of sinus rhythm (SR) transitioning into atrial fibrillation (AF).

[0022] FIG. 8 is a diagram showing, by way of example, a diagnostic composite plot for facilitating the diagnosis of 3:1 atrial flutter (AFL) transitioning into SR.

[0023] FIG. 9 is a diagram showing, by way of example, a diagnostic composite plot for facilitating the diagnosis of atrial trigeminy.

[0024] FIG. 10 is a diagram showing, by way of example, a diagnostic composite plot for facilitating the diagnosis of maximum heart rate in an episode of AF during exercise.

[0025] FIG. 11 is a diagram showing, by way of example, a diagnostic composite plot for facilitating the diagnosis of SR transitioning into AFL transitioning into AF.

[0026] FIG. 12 is a diagram showing, by way of example, a diagnostic composite plot for facilitating the diagnosis of sinus tachycardia and palpitations that occurred during exercise accompanied by a jump in heart rate.

[0027] FIG. 13 is a diagram showing, by way of example, a diagnostic composite plot for facilitating the diagnosis of bradycardia.

[0028] FIG. 14 is a block diagram showing a system for facilitating diagnosis of cardiac rhythm disorders with the aid of a digital computer in accordance with one embodiment.

DETAILED DESCRIPTION

[0029] A normal healthy cardiac cycle repeats through an expected sequence of events that can be visually traced through an ECG. Each cycle starts with cardiac depolarization originating high in the right atrium in the sinoatrial (SA) node before spreading leftward towards the left atrium and inferiorly towards the atrioventricular (AV) node. After a delay in the AV node, the depolarization impulse transits the Bundle of His and moves into the right and left bundle branches and Purkinje fibers to activate the right and left ventricles.

[0030] When a rhythm disorder is suspected, diagnostically-relevant arrhythmic events in the cardiac cycle can often be identified and evaluated with the assistance of an ECG and R-R interval tachography, such as Poincaré plots. Routine ECG evaluation is primarily focused identifying changes to expected ECG waveform shapes. FIG. 1 is a graph showing, by way of example, a single ECG waveform 10. The x-axis represents approximate time in units of tenths of a second and the y-axis represents approximate cutaneous electrical signal strength in units of millivolts. By longstanding convention, ECGs are typically printed or displayed at an effective paper speed of 25 millimeters (mm) per second. Although in practice an ECG may be provided to a physician in traditional paper-printed form, in "virtual" electronic display form, or both, the term "effective paper speed" is nevertheless still widely applied as a metric to normalize the recorded ECG signal to a standardized grid of 1 mm squares (omitted for the sake of clarity in FIG. 1), whereby each 1 mm horizontal box in the grid corresponds to 0.04 s (40 ms) of recorded time. Other effective paper speeds, grid sizes and units of display are possible.

[0031] A full ECG consists of a stream of alphabetically-labeled waveforms 10 that collectively cover cardiac performance over a period of observation. For a healthy patient, within each ECG waveform 10, the P-wave 11 will normally have a smooth, normally upward, positive waveform that

indicates atrial depolarization. The QRS complex **17** will usually follow, often with a downward deflection of a Q-wave **12**, followed by a larger upward deflection of an R-wave **13**, and be terminated with a downward waveform of the S-wave **14**, which are collectively representative of ventricular depolarization. The T-wave **15** will normally be a modest upward waveform, representative of ventricular repolarization, while the U-wave **16**, which is often not directly observable, will indicate the recovery period of the Purkinje conduction fibers.

[0032] Rhythm disorders often manifest through R-R interval variability and the patterns formed by R-R intervals over an extended time period are important tools in the diagnosis of cardiac rhythm abnormalities. For example, atrial fibrillation (AF) is the chaotic firing of the atria that leads to an erratic activation of the ventricles. AF is initially diagnosed by an absence of organized P-waves **11** and confirmed by erratic ventricular rates that manifest in an ECG R-R interval plot as a cloud-like pattern of irregular R-R intervals due to an abnormal conduction of impulses to the ventricles. There is a Gaussian-like distribution to these R-R intervals during AF. Similarly, atrial flutter (AFL) is an abnormal heart rhythm in which cardiac impulses travel along pathways within the right atrium in an organized circular motion, causing the atria to beat faster than and out of sync with the ventricles. During AFL, the heart beats quickly, yet with a regular pattern. Although AFL presents in an electrogram (e-gram) as a “sawtooth” pattern, AFL can be confirmed in an ECG by characteristic R-R interval patterns that usually manifest as 2:1 atrioventricular (AV) conduction or 4:1 atrioventricular conduction. On occasion, the conduction through the AV node is variable and not fixed.

[0033] Conventionally, R-R intervals have been visualized using Poincaré plots. FIG. 2 is a graph showing, by way of example, a prior art Poincaré R-R interval plot **18**. The x-axis represents the duration of R-R interval n in units of milliseconds (ms). The y-axis represents the duration of R-R interval $n+1$ also in units of ms. Ordinarily, the x- and y-axes use the same units, so as to form a trend line **19** along the 45-degree angle. When an R-R interval is equal to the successive R-R interval, as often occurs when heart rhythm is regular, the dot representing the two intervals falls onto the 45-degree trend line **19**. Conversely, when an R-R interval has changed since the preceding R-R interval, the dot representing the two intervals falls off the 45-degree trend line **19** and, as the difference between successive R-R intervals increases, the dots fall further away from the trend line **19**.

[0034] The number of dots deviating from the trend line **19** in a Poincaré plot can indicate the frequency of occurrence of irregular heartbeats when compared to the number of dots on the trend line **19**. The distance of the dots to the trend line **19** can approximate the extent of heart rate change from one heartbeat to the next. However, as heart rate change is limited to only successively-occurring heartbeats, the linearity of time and associated contextual information over an extended time frame are lost. In addition, significant changes in heart rate, particularly spikes in heart rate, such as due to sinus rhythm transitions to atrial flutter, may be masked, distorted or even omitted in a Poincaré plot if the change occurs over non-successive heartbeats. In summary, a Poincaré plot is more useful as a mathematical tool than a physiological one, and therefore a Poincaré plot cannot truly

represent what the heart is doing serially over time with respect to changes in the heart’s normal and abnormal physiology.

[0035] Despite the limitations of Poincaré plots and related forms of R-R interval tachography, R-R interval data when presented in a format duplicating temporal physiological events remains a key tool that physicians can rely upon to identify temporally-related cardiac dysrhythmic patterns. Interpretation of R-R interval data can be assisted by including multiple temporal points of reference and a plot of R-R interval data that comparatively depicts heart rate variability in concert with R-R interval data. FIG. 3 is a flow diagram showing a method **20** for facilitating diagnosis of cardiac rhythm disorders with the aid of a digital computer in accordance with one embodiment. The method **20** can be implemented in software and execution of the software can be performed on a computer, such as further described infra with reference to FIG. 14, as a series of process or method modules or steps.

[0036] As a precursor step, the cutaneous action potentials of a patient are monitored and recorded as ECG data over a set time period (step **21**), which can be over a short term or extended time frame. ECG recordation, as well as physiological monitoring, can be provided through various kinds of ECG-capable monitoring ensembles, including a standardized 12-lead ECG setup, such as used for clinical ECG monitoring, a portable Holter-type ECG recorder for traditional ambulatory ECG monitoring, or a wearable ambulatory ECG monitor, such as a flexible extended wear electrode patch and a removable reusable (or single use) monitor recorder, such as described in commonly-assigned U.S. Pat. No. 9,345,414, issued May 24, 2016, the disclosure of which is incorporated by reference, the latter of which includes an electrode patch and monitor recorder that are synergistically optimized to capture electrical signals from the propagation of low amplitude, relatively low frequency content cardiac action potentials, particularly the P-waves, generated during atrial activation. Still other forms of ECG monitoring assemblies are possible.

[0037] Upon completion of the monitoring period, the ECG and any physiological data are downloaded or retrieved into a digital computer, as further described infra with reference to FIG. 14, with, for instance, the assistance of a download station or similar device, or via wireless connection, if so equipped, and a vector of the downloaded or retrieved ECG data is obtained (step **22**). In one embodiment, the vector of ECG data represents a 40-minute (or other duration) time span that is used in constructing the plot of R-R interval data, although other pre-event and post-event time spans are possible. Optionally, a potentially-actionable cardiac event within the vector of ECG data can be identified and the ECG data during, prior to and after the event is selected (step **23**). The event could be identified with the assistance of a software package, such as Holter LX Analysis Software, licensed by NorthEast Monitoring, Inc., Maynard, Mass.; IntelliSpace Cardiovascular Image and Information management system, licensed Koninklijke Philips N.V., Amsterdam, Netherlands; MoMe System, licensed by InfoBionic, Lowell, Mass.; Pyramis ECG Management, licensed by Mortara Instrument Inc., Milwaukee, Wis.; ICS Clinical Suite, licensed by Spacelabs Healthcare Inc., Snoqualmie, Wash.; or a customized software package.

Alternatively, the potentially-actionable cardiac event could be identified by a physician or technician during review of the ECG data.

[0038] To improve diagnosis of heart rate variability, a diagnostic composite plot is constructed that includes one or more temporal points of reference into the ECG data, which provide important diagnostic context, and a plot of R-R interval data is constructed based on the vector of ECG data (step 24), as further described infra with reference to FIG. 4. Briefly, both near field and far field contextual views of the ECG data are constructed and displayed. Both views are temporally keyed to an extended duration R-R interval data view that, in one embodiment, is scaled non-linearly to maximize the visual differentiation for frequently-occurring heart rate ranges, such that a single glance allows the physician to make a diagnosis. All three views are presented simultaneously, thereby allowing the interpreting physician to diagnose rhythm and the pre- and post-contextual events leading up to a cardiac rhythm of interest.

[0039] In a further embodiment, findings made through interpretation of heart rate variability patterns in the diagnostic composite plot can be analyzed to form a diagnosis of a cardiac rhythm disorder (step 25), such as the cardiac rhythm disorders listed, by way of example, in Table 1. For instance, the heart rate variability patterns in the diagnostic composite plot could be provided to a system that programmatically detects AF by virtue of looking for the classic Gaussian-type distribution on the “cloud” of heart rate variability formed in the plot of R-R interval data, which can be corroborated by the accompanying contextual ECG data. Finally, therapy to address diagnosed disorder findings can optionally be programmed into a cardiac rhythm therapy delivery device (step 26), such as an implantable medical device (IMD) (not shown), including a pacemaker, implantable cardioverter defibrillator (ICD), or similar devices.

TABLE 1

Cardiac Rhythm Disorders
Normal sinus rhythm
Sinus Bradycardia
Sinus Tachycardia
Premature atrial and ventricular beats
Ectopic atrial tachycardia
Atrial fibrillation
Atrial flutter
Atrial or ventricular bigeminy, trigeminy or quadrigeminy
Sinus Bradycardia
Fusion beats
Interpolated ventricular premature beats
Intraventricular conduction delay
Junctional rhythm
AV Nodal re-entrant tachycardia
AV re-entrant tachycardia
Wolff-Parkinson-White Syndrome and Pre-excitation
Ventricular tachycardia
Accelerated idioventricular rhythm
AV Wenckebach block
AV Type II block
Sinoatrial block

[0040] A diagnostic composite plot is constructed and displayed to help physicians identify and diagnose temporally-related cardiac dysrhythmic patterns. The diagnostic composite plot includes ECG traces from two or more temporal points of reference and a plot of R-R interval data, although other configurations of ECG data plots when combined with the R-R interval plot will also provide

critical information. FIG. 4 is a flow diagram showing a routine 30 for constructing and displaying a diagnostic composite plot for use in the method 20 of FIG. 3. Specific examples of diagnostic composite plots are discussed in detail infra with reference to FIGS. 7-13.

[0041] In the diagnostic composite plot, R-R interval data is presented to physicians in a format that includes views of relevant near field and far field ECG data, which together provide contextual information that improves diagnostic accuracy. In a further embodiment, other views of ECG data can be provided in addition to or in lieu of the near field and far field ECG data views. The near field (or short duration) ECG data provides a “pinpoint” classical view of an ECG at traditional recording speed in a manner that is known to and widely embraced by physicians. The near field ECG data is coupled to a far field (or medium duration) ECG data view that provides an “intermediate” lower resolution, pre- and post-event contextual view. Thus, the extended-duration R-R interval plot is first constructed (step 31), as further described infra with reference to FIG. 5. Optionally, noise can be filtered from the R-R interval plot (step 32), which is then displayed (step 33). Noise filtering can include low-pass or high-pass filtering or other forms of signal processing, including automatic gain control, such as described in commonly-assigned U.S. Pat. No. 9,345,414, cited supra.

[0042] Rhythm disorders have different weightings depending upon the context with which they occur. In the diagnostic composite plot, the R-R interval data view and the multiple views of the ECG data provide that necessary context. Effectively, the short and medium duration ECG data that accompanies the extended-duration R-R interval plot represents the ECG data “zoomed” in around a temporal point of reference identified in the center (or other location) of the R-R interval plot, thereby providing a visual context to the physician that allows temporal assessment of cardiac rhythm changes in various complementary views of the heart’s behavior. The durations of the classical “pinpoint” view, the pre- and post-event “intermediate” view, and the R-R interval plot are flexible and adjustable. In one embodiment, the diagnostic composite plot displays R-R interval data over a forty-minute duration and ECG data over short and medium durations (steps 34 and 35), such as four-second and 24-second durations that provide two- and 12-second segments of the ECG data before and after the R-R interval plot’s temporal point of reference, which is generally in the center of the R-R interval plot, although other locations in the R-R interval plot could be identified as the temporal point of reference. The pinpoint “snapshot” and intermediate views of ECG data with the extended term R-R interval data comparatively depicts heart rate context and patterns of behavior prior to and after a clinically meaningful arrhythmia or patient concern, thereby enhancing diagnostic specificity of cardiac rhythm disorders and providing physiological context to improve diagnostic ability. In a further embodiment, diagnostically relevant cardiac events can be identified and the R-R interval plot can be constructed with a cardiac event centered in the middle (or other location) of the plot, which thereby allows pre- and post-event heart rhythm data to be contextually “framed” through the pinpoint and intermediate ECG data views. Other durations, intervals and presentations of ECG data are possible.

[0043] The extended-duration R-R interval plot presents beat-to-beat heart rate variability in a format that is intuitive and contextual, yet condensed. The format of the R-R

interval plot is selected to optimize visualization of cardiac events in a compressed, yet understandable field of view, that allows for compact presentation of the data akin to a cardiologists understanding of clinical events. FIG. 5 is a flow diagram showing a routine 40 for constructing an extended-duration R-R interval plot for use in the routine 30 of FIG. 4. The duration of the R-R interval plot can vary from less than one minute to the entire duration of the recording. Thus, a plurality of R-wave peaks is first selected out of the vector of ECG data (step 41) appropriate to the duration of the R-R interval plot to be constructed. For successive pairs of the R-wave peaks (steps 42-43), the difference between the recording times of the R-peaks is calculated (step 43). Each recording time difference represents the length of one heartbeat. The heart rate associated with the recording time difference is determined by taking an inverse of the recording time difference and normalizing the inverse to beats per minute (step 44). Taking the inverse of the recording time difference yields a heart rate expressed in beats per second, which can be adjusted by a factor of 60 to provide a heart rate expressed in bpm. Calculation of the differences between the recording times and the associated heart rate continues for all of the remaining pairs of the R-wave peaks (step 44).

[0044] The pairings of R-R intervals and associated heart rates are formed into a two-dimensional plot. R-R intervals are plotted along the x-axis and associated heart rates are plotted along the y-axis. The range and scale of the y-axis (heart rate) can be adjusted according to the range and frequency of normal or patient-specific heart rates, so as to increase the visual distinctions between the heart rates that correspond to different R-R intervals. In one embodiment, the y-axis of the R-R interval plot has a range of 20 to 300 beats per minute and R-R intervals corresponding to heart rates falling extremely outside of this range are excluded to allow easy visualization of 99+% of the heart rate possibilities.

[0045] In a further embodiment, they-axis has a non-linear scale that is calculated as a function of the x-axis (R-R interval), such that:

$$y = \left(\frac{x - \text{min bpm}}{\text{max bpm} - \text{min bpm}} \right)^n$$

where x is the time difference, min bpm is the minimum heart rate, max bpm is the maximum heart rate, and $n < 1$. The non-linear scale of the y-axis accentuates the spatial distance between successive heart rates when heart rate is low. For example, when $n=2$, the spatial difference between 50 and 60 bpm is 32% larger than the spatial difference between 90 bpm and 100 bpm, and 68% larger than the spatial difference between 150 bpm and 160 bpm. As a result the overall effect is to accentuate the spatial differences in frequently-occurring ranges of heart rate and de-emphasize the spatial differential in ranges of heart rate where a deviation from norm would have been apparent, thus maximizing the spatial efficiency in data presentation. The goal is to show cardiac events in a simple, small visual contextual format. Larger scales and larger formats bely the practical limits of single-page presentations for the easy visualization at a glance by the busy physician. The visual distinctions between the heart rates that correspond to different R-R intervals stand out, especially when plotted on a non-linear scale. Other y-axis

ranges and scales are possible as may be selected by distinct clinical needs and specific diagnostic requirements.

[0046] The diagnostic composite plot includes a single, long range view of R-R interval data and a pair of pinpoint ECG data views that together help to facilitate rhythm disorder diagnosis by placing focused long-term heart rate information alongside short-term and medium-term ECG information. Such pairing of ECG and R-R interval data is unique in its ability to inform the physician of events prior to, during and after a cardiovascular event. FIG. 6 is a diagram showing, by way of example, a diagnostic composite plot 50 generated by the method 30 of FIG. 3. Note that the diagnostic composite plot can be tailored to include more than one view of R-R interval data and as many views of contextual ECG data as needed. In a further embodiment, a background information plot presenting an extended far field of related information can be included, such as activity amount, activity intensity, posture, syncope impulse detection, respiratory rate, blood pressure, oxygen saturation (SpO_2), blood carbon dioxide level (pCO_2), glucose, lung wetness, and temperature. Other forms of background information are possible. In a still further embodiment, background information can be layered on top of or keyed to the diagnostic composite plot 50, particularly at key points of time in the R-R interval data plot, so that the context provided by each item of background information can be readily accessed by the reviewing physician.

[0047] The diagnostic composite plot 50 includes an ECG plot presenting a near field (short duration) view 51, an ECG plot presenting an intermediate field (medium duration) view 52, and an R-R interval data plot presenting a far field (extended duration) view 53. The three views 51, 52, 53 are juxtaposed alongside one other to allow quick back and forth referencing of the full context of the heart's normal and abnormal physiology. Typically, a temporal point of reference, which could be a diagnostically relevant cardiac event, patient concern or other indicia, would be identified and centered on the x-axis in all three views. The placement of the temporal point of reference in the middle of all three x-axes enables the ECG data to be temporally keyed to the R-R interval data appearing in the center 60 of the R-R interval data view 53, with a near field view 51 of an ECG displayed at normal (paper-based) recording speed and a far field view 52 that presents the ECG data occurring before and after the center 60. As a result, the near field view 51 provides the ECG data corresponding to the R-R interval data at the center 60 (or other location) in a format that is familiar to all physicians, while the intermediate field view 52 enables presentation of the broader ECG data context going beyond the borders of the near field view 51. In a further embodiment, the center 60 can be slidably adjusted backwards and forwards in time, with the near field view 51 and the far field view 52 of the ECG data automatically adjusting accordingly to stay in context with the R-R interval data view 51. In a still further embodiment, multiple temporal points of reference can be identified with each temporal point of reference being optionally accompanied by one or more dedicated sets of ECG data views.

[0048] The collection of plots are conveniently arranged close enough to one another to facilitate printing on a single page of standard sized paper (or physical paper substitute, such as a PDF file), although other layouts of the plots are possible. The far field view 53 is plotted with time in the x-axis and heart rate in the y-axis. The R-R intervals are

calculated by measuring the time occurring between successive R-wave peaks. In one embodiment, the far field view **53** presents R-R interval data (expressed as heart rate in bpm) that begins about 20 minutes prior to and ends about 20 minutes following the center **60**, although other durations are possible.

[0049] The near field view **51** and intermediate field view **52** present ECG data relative to the center **60** of the far field view **53**. The near field view **51** provides a pinpoint or short duration view of the ECG data. In one embodiment, the near field view **51** presents ECG data **55** that begins about two seconds prior to and ends about two seconds following the center **60**, although other durations are possible. The intermediate field view **52** provides additional contextual ECG information allowing the physician to assess the ECG itself and gather a broader view of the rhythm before and after a “blow-up” of the specific arrhythmia of interest. In one embodiment, the intermediate field view **52** presents ECG data **56** that begins about 12 seconds prior to and ends about 12 seconds following the center **60**, although other durations are possible. For convenience, the eight-second interval of the ECG data **56** in the intermediate field view **52** that makes up the ECG data **56** in the near field view **51** is visually highlighted, here, with a surrounding box **57**. In addition, other views of the ECG data, either in addition to or in lieu of the near field view **51** and the far field view **52** are possible. Optionally, an ECG plot presenting an extended far field view **54** of the background information can be included in the diagnostic composite plot **50**. In one embodiment, the background information is presented as average heart rate with day and night periods **58** alternately shaded along the x-axis. Other types of background information, such as activity amount, activity intensity, posture, syncope impulse detection, respiratory rate, blood pressure, oxygen saturation (SpO₂), blood carbon dioxide level (pCO₂), glucose, lung wetness, and temperature, are possible.

[0050] Examples of the diagnostic composite plot as applied to specific forms of cardiac rhythm disorders will now be discussed. These examples help to illustrate the distinctive weightings that accompany different forms of rhythm disorders and the R-R interval and ECG waveform deflection context with which they occur. FIG. **7** is a diagram showing, by way of example, a diagnostic composite plot **70** for facilitating the diagnosis of sinus rhythm (SR) transitioning into AF. SR is indicated through the presence of a reasonably steady baseline, but with subsidiary lines of premature beats and their compensatory pauses. SR manifests as a shadowing **71** of a high heart rate line and a low heart rate line. AF is characterized by irregular heartbeats with a somewhat random variation of R-R intervals, although within a limited range and concentrating in a Gaussian-like distribution pattern around a mean that varies over time. Although AF can be diagnosed by viewing a near field view **51** of ECG data showing heartbeats with reversed P-wave and irregular R-R intervals, this approach may be unclear when viewing “snippets” of ECG data, especially when associated with poor quality ECG signals. The presence of AF can also be confirmed through a far field view **53** of R-R interval data, in which the R-R intervals assume superficially appearing disorganized, spread-out and decentralized scattered cloud **72** along the x-axis, in comparison to a concentrated, darkened line typical of a more organized cardiac rhythm.

[0051] FIG. **8** is a diagram showing, by way of example, a diagnostic composite plot **80** for facilitating the diagnosis of 3:1 atrial flutter (AFL) transitioning into SR with frequent premature ectopic atrial beats. In the initial part of the R-R interval plot, the R-R intervals have a discernible aggregated line in the middle of the cloud **81** when the rhythm has yet to stabilize into a set pattern, not quite AF and not quite AFL. Immediately thereafter, a dense line representing firm 3:1 atrial flutter stabilizes the rhythm prior to the transition into SR associated with the presence of two seesawing baselines that result from frequent atrial ectopy causing short coupling intervals and then compensatory long coupling intervals. SR is indicated by the middle of the three lines with a low heart rate line consistent with the compensatory pause (long coupling interval) and a high heart rate line with the shortest coupling interval representing the series of atrial premature beats **82**, and thus, at a faster heart rate.

[0052] FIG. **9** is a diagram showing, by way of example, a diagnostic composite plot **90** for facilitating the diagnosis of atrial trigeminy. Atrial trigeminy is characterized by three heartbeat rates appearing intermittently yet reasonably regularly. Although atrial trigeminy can be diagnosed by viewing a near field view **51** of ECG data, the pattern is significantly more recognizable in a far field view **53** of R-R interval data, in which a repeating pattern of three distinct heartbeat lines are persistently present and clearly visible **91**. This view also provides the physician with a qualitative feel for the frequency of the event troubling the patient that is not discernible from a single ECG strip.

[0053] FIG. **10** is a diagram showing, by way of example, a diagnostic composite plot **100** for facilitating the diagnosis of maximum heart rate in an episode of AF during exercise. In a far field view **50** of R-R interval data, AF manifests through a dispersed cloud of dots (Gaussian-like distribution) without a discernible main heart rate line representing regular heartbeats **101**. Under exercise, the maximum heartbeat can be located by an increase in heart rate clustered about the cloud **102**. In addition, individual dots above the 200 bpm range throughout the entire 40-minute range indicates the maximum heart rate during exercise. The very rapid rise in heart rate can be critical to patient management, as such bumps in rate by exercise can prove serious and even trigger cardiac arrest. Their very presence is easily visualized in the R-R interval data plot, thereby allowing the physician to alter therapy sufficiently to control such potentially damaging rises in heart rate.

[0054] FIG. **11** is a diagram showing, by way of example, a diagnostic composite plot **110** for facilitating the diagnosis of SR transitioning into AFL transitioning into AF. In a far field view **53** of R-R interval data, SR manifests as an uneven main heart rate line with a fluctuating height **111**. At the onset of AFL, the main heart rate line breaks away at a lower heart rate than the SR main heart rate line **112**. The episode of AFL further evolves into AF as characterized by a dispersed cloud of irregular heartbeats without concentrated heart rate lines **113**. This view provides critical information to the physician managing AF patients in that, at a glance, the view provides data that tells the physician that the patient’s AF may be the consequence of AFL. Such knowledge may alter both drug and procedure therapies, like catheter ablation details of intervention.

[0055] FIG. **12** is a diagram showing, by way of example, a diagnostic composite plot **120** for facilitating the diagnosis of sinus tachycardia and palpitations that occurred during

exercise accompanied by a jump in heart rate. In a far field view **50** of R-R interval data, sinus tachycardia is indicated by the presence of a baseline heart rate of about 60 bpm **121** that spikes up to around 100 bpm **122** and gradually slopes down with a wide tail **123**, reflecting a sharp rise of heart rates followed by a gradual decline. The associated ECG data in the near field and intermediate field views (not shown) can confirm the rhythm as sinus rhythm and a normal response to exercise. This rhythm, although superficially obvious, was associated with symptoms of palpitations and demonstrates a sensitivity to heart rate fluctuations, rather than a sensitivity to an arrhythmia. This common problem is often dismissed as merely sinus tachycardia, rather than recognizing the context of a changing rate that generated the patient's complaint, a problem, visible only in the R-R interval data plot.

[0056] FIG. **13** is a diagram showing, by way of example, a diagnostic composite plot **90** for facilitating the diagnosis of bradycardia during sleep and a R-R interval pattern characteristic of sleep. Bradycardia refers to a resting heart rate of under 60 bpm. Bradycardia during sleep is often tempered with occasional spikes of rapid heart rate, which can be a secondary compensatory response to dreaming, snoring or sleep apnea. In a far field view **50** of R-R interval data, bradycardia manifests as the presence of a base line heart rate in the range of about 50 bpm **131**, coupled with multiple spikes of dots **132** representing intermittent episodes of elevated heart rate. Such elevations in heart rate during a pre-dominantly slower rate may be signs of a cardio-respiratory disorder. Still other applications of the diagnostic composite plot **80** are possible.

[0057] The diagnostic composite plots are a tool used by physicians as part of a continuum of cardiac care provisioning that begins with ECG monitoring, continues through diagnostic overread and finally, if medically appropriate, concludes with cardiac rhythm disorder treatment. Each of these steps involve different physical components that collaboratively allow physicians to acquire and visualize R-R interval and ECG data in a way that accurately depicts heart rate variability over time. FIG. **14** is a block diagram showing a system **140** for facilitating diagnosis of cardiac rhythm disorders with the aid of a digital computer **150** in accordance with one embodiment. Each diagnostic composite plot **151** is based on ECG data **166** that has either been recorded by a conventional electrocardiograph (not shown) or retrieved or obtained from some other type of ECG monitoring and recording device. Following completion of the ECG monitoring, the ECG data is assembled into a diagnostic composite plot **151**, which can be used by a physician to diagnosis and, if required, treat a cardiac rhythm disorder, or for other health care or related purposes.

[0058] Each diagnostic composite plot **151** is based on ECG data **166** that has been recorded over a period of observation, which can be for just a short term, such as during a clinic appointment, or over an extended time frame of months. ECG recordation and, in some cases, physiological monitoring can be provided through various types of ECG-capable monitoring ensembles, including a standardized 12-lead ECG setup (not shown), such as used for clinical ECG monitoring, a portable Holter-type ECG recorder for traditional ambulatory ECG monitoring (also not shown), or a wearable ambulatory ECG monitor.

[0059] One form of ambulatory ECG monitor **142** particularly suited to monitoring and recording ECG and physi-

ological data employs an electrode patch **143** and a removable reusable (or single use) monitor recorder **144**, such as described in commonly-assigned U.S. Pat. No. 9,345,414, cited supra. The electrode patch **143** and monitor recorder **144** are synergistically optimized to capture electrical signals from the propagation of low amplitude, relatively low frequency content cardiac action potentials, particularly the P-waves generated during atrial activation. The ECG monitor **142** sits centrally (in the midline) on the patient's chest along the sternum **169** oriented top-to-bottom. The ECG monitor **142** interfaces to a pair of cutaneous electrodes (not shown) on the electrode patch **143** that are adhered to the patient's skin along the sternal midline (or immediately to either side of the sternum **169**). The ECG monitor **142** has a unique narrow "hourglass"-like shape that significantly improves the ability of the monitor to be comfortably worn by the patient **141** for an extended period of time and to cutaneously sense cardiac electric signals, particularly the P-wave (or atrial activity) and, to a lesser extent, the QRS interval signals in the ECG waveforms indicating ventricular activity.

[0060] The electrode patch **143** itself is shaped to conform to the contours of the patient's chest approximately centered on the sternal midline. To counter the dislodgment due to compressional and torsional forces, a layer of non-irritating adhesive, such as hydrocolloid, is provided at least partially on the underside, or contact, surface of the electrode patch, but only on the electrode patch's distal and proximal ends. To counter dislodgment due to tensile and torsional forces, a strain relief is defined in the electrode patch's flexible circuit using cutouts partially extending transversely from each opposite side of the flexible circuit and continuing longitudinally towards each other to define in 'S'-shaped pattern. In a further embodiment, the electrode patch **143** is made from a type of stretchable spunlace fabric. To counter patient bending motions and prevent disadhesion of the electrode patch **143**, the outward-facing aspect of the backing, to which a (non-stretchable) flexible circuit is fixedly attached, stretches at a different rate than the backing's skin-facing aspect, where a skin adhesive removably affixes the electrode patch **143** to the skin. Each of these components are distinctive and allow for comfortable and extended wear, especially by women, where breast mobility would otherwise interfere with ECG monitor use and comfort. Still other forms of ECG monitoring and recording assemblies are possible.

[0061] When operated standalone, the monitor recorder **142** senses and records the patient's ECG data **166** and physiological data (not shown) into a memory onboard the monitor recorder **144**. The recorded data can be downloaded using a download station **147**, which could be a dedicated download station **145** that permits the retrieval of stored ECG data **166** and physiological data, if applicable, execution of diagnostics on or programming of the monitor recorder **144**, or performance of other functions. To facilitate physical connection with the download station **145**, the monitor recorder **144** has a set of electrical contacts (not shown) that enable the monitor recorder **144** to physically interface to a set of terminals **148**. In turn, the download station **145** can be operated through user controls **149** to execute a communications or data download program **146** ("Download") or similar program that interacts with the monitor recorder **144** via the physical interface to retrieve the stored ECG data **166**. The download station **145** could

alternatively be a server, personal computer, tablet or hand-held computer, smart mobile device, or purpose-built device designed specific to the task of interfacing with a monitor recorder **144**. Still other forms of download station **145** are possible. In a further embodiment, the ECG data **166** from the monitor recorder **144** can be offloaded wirelessly.

[0062] The ECG data **166** can be retrieved from the download station **145** using a control program **157** (“Ctl”) or analogous application executing on a personal digital computer **156** or other connectable computing device, via a hard wired link **158**, wireless link (not shown), or by physical transfer of storage media (not shown). The personal digital computer **156** may also execute middleware (not shown) that converts the ECG data **166** into a format suitable for use by a third-party post-monitoring analysis program. The personal digital computer **156** stores the ECG data **166** along with each patient’s electronic medical records (EMRs) **165** in the secure database **64**, as further discussed infra. In a further embodiment, the download station **145** is able to directly interface with other devices over a computer communications network **155**, which could be a combination of local area and wide area networks, including the Internet or another telecommunications network, over wired or wireless connections.

[0063] A client-server model can be employed for ECG data **166** analysis. In this model, a server **62** executes a patient management program **160** (“Mgt”) or similar application that accesses the retrieved ECG data **166** and other information in the secure database **164** cataloged with each patient’s EMRs **165**. The patients’ EMRs can be supplemented with other information (not shown), such as medical history, testing results, and so forth, which can be factored into automated diagnosis and treatment. The patient management program **160**, or other trusted application, also maintains and safeguards the secure database **164** to limit access to patient EMRs **165** to only authorized parties for appropriate medical or other uses, such as mandated by state or federal law, such as under the Health Insurance Portability and Accountability Act (HIPAA) or per the European Union’s Data Protection Directive. Other schemes and safeguards to protect and maintain the integrity of patient EMRs **165** are possible.

[0064] In a further embodiment, the wearable monitor **142** can interoperate wirelessly with other wearable or implantable physiology monitors and activity sensors **152**, such as activity trackers worn on the wrist or body, and with mobile devices **153**, including smart watches and smartphones. Wearable or implantable physiology monitors and activity sensors **152** encompass a wide range of wirelessly interconnectable devices that measure or monitor a patient’s physiological data, such as heart rate, temperature, blood pressure, respiratory rate, blood pressure, blood sugar (with or without an appropriate subcutaneous probe), oxygen saturation, minute ventilation, and so on; physical states, such as movement, sleep, footsteps, and the like; and performance, including calories burned or estimated blood glucose level. Frequently, wearable and implantable physiology monitors and activity sensors **152** are capable of wirelessly interfacing with mobile devices **153**, particularly smart mobile devices, including so-called “smartphones” and “smart watches,” as well as with personal computers and tablet or handheld computers, to download monitoring data either in real-time or in batches through an application (“App”) or similar program.

[0065] Based on the ECG data **166**, physicians can rely on the data as medically certifiable and are able to directly proceed with diagnosing cardiac rhythm disorders and determining the appropriate course of treatment for the patient **141**, including undertaking further medical interventions as appropriate. The ECG data **166** can be retrieved by a digital computer **150** over the network **155**. A diagnostic composite plot **151** that includes multiple temporal points of reference and a plot of R-R interval data is then constructed based on the ECG data **166**, as discussed in detail supra with reference to FIG. 3, and displayed or, alternatively, printed, for use by a physician.

[0066] In a further embodiment, the server **159** executes a patient diagnosis program **161** (“Dx”) or similar application that can evaluate the ECG data **166** to form a diagnosis of a cardiac rhythm disorder. The patient diagnosis program **161** compares and evaluates the ECG data **166** to a set of medical diagnostic criteria **167**, from which a diagnostic overread **162** (“diagnosis”) is generated. Each diagnostic overread **162** can include one or more diagnostic findings **168** that can be rated by degree of severity, such as with the automated diagnosis of atrial fibrillation. If at least one of the diagnostic findings **168** for a patient exceed a threshold level of tolerance, which may be tailored to a specific client, disease or medical condition group, or applied to a general patient population, in a still further embodiment, therapeutic treatment (“Therapy”) to address diagnosed disorder findings can be generated and, optionally, programmed into a cardiac rhythm therapy delivery device, such as an IMD (not shown), including a pacemaker, implantable cardioverter defibrillator (ICD), or similar devices.

[0067] While the invention has been particularly shown and described as referenced to the embodiments thereof, those skilled in the art will understand that the foregoing and other changes in form and detail may be made therein without departing from the spirit and scope.

What is claimed is:

1. A system for facilitating a cardiac rhythm disorder diagnosis with the aid of a digital computer, comprising:
 - an electrocardiogram (ECG) monitoring and recording device;
 - a download station adapted to retrieve cutaneous action potentials of a patient recorded over a set period of time by the ECG monitoring and recording device as ECG data; and
 - a processor and memory within which code for execution by the processor is stored, wherein the processor:
 - identifies a plurality of R-wave peaks in the ECG data;
 - calculates a difference between recording times of successive pairs of the R-wave peak as R-R intervals and determines a heart rate associated with each time difference;
 - forms an R-R interval plot of the ECG data comprising the R-R intervals plotted along an x-axis of the plot and the heart rates associated with the R-R intervals plotted along a y-axis of the plot; and
 - generates a diagnostic composite plot comprising the R-R interval plot, a near field view of a portion of the ECG data, and an intermediate field view of a different portion of the ECG data for diagnosis of a cardiac event.
2. A system in accordance with claim 1, wherein the y-axis has a range of 20 to 300 heartbeats per minute.

3. A system in accordance with claim 2, wherein the processor removes those R-R intervals that correspond to heart rates outside the range of the y-axis.

4. A system in accordance with claim 1, wherein a background information plot presenting one or more of activity amount, activity intensity, posture, syncope impulse detection, respiratory rate, blood pressure, oxygen saturation (SpO₂), blood carbon dioxide level (pCO₂), glucose, lung wetness, and temperature is provided with the diagnostic composite plot.

5. A system in accordance with claim 4, wherein the background information plot is provided as one of layered on top of the diagnostic composite plot and keyed to the diagnostic composite plot.

6. A system in accordance with claim 1, further comprising:

a display to present on the R-R interval plot a diagnosis of sinus rhythm transitioning into atrial fibrillation comprising:

displaying sinus rhythm as a shadowing of a high heart rate line and a low heart rate line; and

displaying atrial fibrillation as irregular heartbeats with a random variation of R-R intervals.

7. A system in accordance with claim 1, further comprising:

a display to present on the R-R interval plot a diagnosis of atrial flutter transitioning into sinus rhythm, comprising:

representing each R-R interval and associated heart rate as a point in the R-R interval plot;

displaying a discernible aggregated line of points in a middle of a cluster of points;

identifying a dense line of points after the discernible aggregated line of points as atrial flutter, and

displaying after the dense line of points, a shadowing of points representing a high heart rate line and points representing a low heart rate line as sinus rhythm.

8. A system in accordance with claim 1, further comprising:

a display to present a diagnosis of atrial trigeminy in the R-R interval plot comprising:

representing each R-R interval and associated heart rate as a point in the R-R interval plot; and

displaying three separate lines of points each representing a different heart beat rate appearing reasonably regularly and intermittently in the R-R interval plot.

9. A system in accordance with claim 1, further comprising:

a display to present a diagnosis of maximum heartbeat during an episode of atrial fibrillation in the R-R interval plot, comprising:

representing each R-R interval and associated heart rate as a point in the R-R interval plot;

displaying the atrial fibrillation as a dispersed group of points without a discernible main heart rate line representing regular heartbeats; and

displaying the maximum heartbeat via points representing an increase in heart rate that are clustered about the group.

10. A system in accordance with claim 1, further comprising:

a display to present a diagnosis of sinus rhythm transitioning into atrial flutter transitioning into atrial fibrillation, comprising:

representing each R-R interval and associated heart rate as a point in the R-R interval plot;

displaying sinus rhythm as an uneven line of points with a fluctuating height representing a main heart rate;

displaying atrial flutter as the main heart rate at a lower heart rate than for sinus rhythm; and

displaying atrial fibrillation as a dispersed cloud of points representing irregular heartbeats without concentrated heart rate lines.

11. A system in accordance with claim 1, further comprising:

a display to present a diagnosis of sinus tachycardia, comprising:

representing each R-R interval and associated heart rate as a point in the R-R interval plot; and

displaying a baseline of points that spikes up and gradually slopes down with a wide tail reflecting a sharp rise of heart rates followed by a gradual decline.

12. A system in accordance with claim 1, further comprising:

a display to present a diagnosis of bradycardia, comprising:

representing each R-R interval and associated heart rate as a point in the R-R interval plot; and

displaying a baseline of points with multiple spikes of points representing intermittent episodes of elevated heart rate.

13. A method for facilitating a cardiac rhythm disorder diagnosis with the aid of a digital computer, comprising:

identifying a plurality of R-wave peaks in a set of ECG data;

calculating a difference between recording times of successive pairs of the R-wave peaks as R-R intervals and determining a heart rate associated with each time difference;

forming an R-R interval plot of the ECG data comprising the R-R intervals plotted along an x-axis of the R-R interval plot and the heart rates associated with the R-R intervals plotted along a y-axis of the R-R interval plot; and

generating a diagnostic composite plot comprising the R-R interval plot, a near field view of a portion of the ECG data, and an intermediate field view of a different portion of the ECG data for diagnosis of a cardiac event.

14. A method in accordance with claim 13, wherein the y-axis has a range of 20 to 300 heartbeats per minute.

15. A method in accordance with claim 14, further comprising:

removing those R-R intervals that correspond to heart rates outside the range of the y-axis.

16. A method in accordance with claim 13, further comprising:

providing a background information plot presenting one or more of activity amount, activity intensity, posture, syncope impulse detection, respiratory rate, blood pressure, oxygen saturation (SpO₂), blood carbon dioxide level (pCO₂), glucose, lung wetness, and temperature with the diagnostic composite plot.

17. A method in accordance with claim 16, further comprising:

presenting the background information plot as one of layered on top of the diagnostic composite plot and keyed to the diagnostic composite plot.

18. A method in accordance with claim **13**, further comprising:

presenting on the R-R interval plot a diagnosis of sinus rhythm transitioning into atrial fibrillation comprising: displaying sinus rhythm as a shadowing of a high heart rate line and a low heart rate line; and displaying atrial fibrillation as irregular heartbeats with a random variation of R-R intervals.

19. A method in accordance with claim **13**, further comprising:

presenting on the R-R interval plot a diagnosis of atrial flutter transitioning into sinus rhythm, comprising: representing each R-R interval and associated heart rate as a point in the R-R interval plot; displaying a discernible aggregated line of points in a middle of a cluster of points; identifying a dense line of points after the discernible aggregated line of points as atrial flutter, and displaying after the dense line of points, a shadowing of points representing a high heart rate line and points representing a low heart rate line as sinus rhythm.

20. A method in accordance with claim **13**, further comprising:

presenting a diagnosis of atrial trigeminy in the R-R interval plot comprising: representing each R-R interval and associated heart rate as a point in the R-R interval plot; and displaying three separate lines of points each representing a different heart beat rate appearing reasonably regularly and intermittently in the R-R interval plot.

21. A method in accordance with claim **13**, further comprising:

presenting a diagnosis of maximum heartbeat during an episode of atrial fibrillation in the R-R interval plot, comprising: representing each R-R interval and associated heart rate as a point in the R-R interval plot;

displaying the atrial fibrillation as a dispersed group of points without a discernible main heart rate line representing regular heartbeats; and displaying the maximum heartbeat via points representing an increase in heart rate that are clustered about the group.

22. A method in accordance with claim **13**, further comprising:

presenting a diagnosis of sinus rhythm transitioning into atrial flutter transitioning into atrial fibrillation, comprising:

representing each R-R interval and associated heart rate as a point in the R-R interval plot;

displaying sinus rhythm as an uneven line of points with a fluctuating height representing a main heart rate;

displaying atrial flutter as the main heart rate at a lower heart rate than for sinus rhythm; and

displaying atrial fibrillation as a dispersed cloud of points representing irregular heartbeats without concentrated heart rate lines.

23. A method in accordance with claim **13**, further comprising:

presenting a diagnosis of sinus tachycardia, comprising:

representing each R-R interval and associated heart rate as a point in the R-R interval plot; and

displaying a baseline of points that spikes up and gradually slopes down with a wide tail reflecting a sharp rise of heart rates followed by a gradual decline.

24. A method in accordance with claim **13**, further comprising:

presenting a diagnosis of bradycardia, comprising:

representing each R-R interval and associated heart rate as a point in the R-R interval plot; and

displaying a baseline of points with multiple spikes of points representing intermittent episodes of elevated heart rate.

* * * * *

专利名称(译)	用数字计算机辅助促进心律失常诊断的系统和方法		
公开(公告)号	US20180344191A1	公开(公告)日	2018-12-06
申请号	US16/102608	申请日	2018-08-13
[标]申请(专利权)人(译)	BARDY诊断		
申请(专利权)人(译)	BARDY诊断, INC.		
当前申请(专利权)人(译)	BARDY诊断, INC.		
[标]发明人	BARDY GUST H DREISBACH EZRA M		
发明人	BARDY, GUST H. DREISBACH, EZRA M.		
IPC分类号	A61B5/0456 A61B5/00 A61B5/024 A61B5/0245 A61B5/0464 A61B5/046 A61B5/0452 A61B5/044 A61B5/0432 A61B5/0408 A61B5/04 A61B5/0205 A61B5/0468		
CPC分类号	A61B5/044 A61B5/742 A61B5/0432 A61B5/04017 A61B5/7203 A61B5/6823 A61B5/04085 A61B5/ /04525 A61B5/046 A61B5/04087 A61B5/0468 A61B5/0464 A61B5/0245 A61B5/02405 A61B5/0205 A61B5/0456		
优先权	62/132497 2015-03-12 US 61/882403 2013-09-25 US		
外部链接	Espacenet USPTO		

摘要(译)

提供了一种借助数字计算机促进心律紊乱诊断的系统和方法。在一组ECG数据中识别多个R波峰，并且将连续的R波峰对的记录时间之间的差异计算为R-R间隔。确定与每个时间差相关联的心率。形成ECG数据的R-R间期图。沿R-R间隔图的x轴绘制R-R间隔，沿R-R间隔图的y轴绘制与R-R间隔相关的心率。生成诊断复合图，包括R-R间期图，ECG数据的一部分的近场视图，以及ECG数据的不同部分的中间视野视图，用于诊断心脏事件。

